



**PATIENT**

Echo Dodge

**SPECIES**

Canine

**BREED**

Terrier Cross

**SEX**

Spayed female

**AGE**

11 years

**WEIGHT**

25.1 lbs

**INTERPRETED BY**

Remo Lobetti, BVSc,  
MMedVet (Med),  
PhD, Dipl. ECVIM

**IMAGING PERFORMED BY**

Yvonna Aranda

**HOSPITAL NAME**

Santa Clara AH

**REFERRING VET**

Dr. Malec

**INVOICE**

68307

**DATE**

11/4/25

**PRESENTING CLINICAL SIGNS**

History: Clinical Exam Findings: Overall normal exam, routine annual bloodwork performed and significant abnormalities identified.

ABNORMAL Labwork Values Platelets- 475 (high) Sodium- 140 (low) Na:K- 27 (low) Chloride- 100 (low) Anion Gap- 27 (high) Total Protein- 9.2 (high) Albumin- 4.9 (high) Globulin- 4.3 (high) ALT- 191 (high) AST- 232 (high) ALP 220 (high) Cholesterol- 419 (high) Lipase- 266 (high) CK- 454 (high) Unable to determine T4 due to gross lipemia Current Medications fluoxetine 10mg SID

**ULTRASONOGRAPHIC EXAMINATION OF THE ABDOMEN**

**Urinary System**

The urinary bladder is full with a normal thickness and smooth appearance of the wall. Normal anechoic urine with no sediment or uroliths evident.

Normal appearance of the trigone area, proximal urethra, and iliac blood vessels.

Normal appearance and size of the iliac lymph nodes. Ureters not visualized, which can be considered a normal finding.

Normal renal size (left measured 4.8 cm, right measured 4.7 cm), architecture, echogenic appearance, cortico-medullary differentiation, which maintains a 1:3 cortex to medulla ratio, pelvis, and capsule. No infarcts, mineralization or renoliths evident. Normal color flow pattern is evident in both kidneys.

**Adrenal Glands**

Normal shape, echogenic appearance, size, position, and appearance of the visible peri-adrenal vasculature. Left adrenal gland measured 1.67 cm in length x 0.53 cm and 0.48 cm in width. The right adrenal gland measured 1.54 cm in length x 0.46 cm and 0.46 cm in width.

**Spleen**

Normal size and echogenic appearance. Smooth homogenous parenchyma and regular curvilinear capsule. Normal volume of the splenic vasculature without any overt congestion or thrombosis evident. No inflammatory, neoplastic, infarction, or infiltrative changes evident. The spleen measured 1.6 cm in width.

**Liver**

Normal size with a diffuse increased echogenic and coarse appearance, normal portal markings, and regular curvilinear capsule. No nodules or masses evident. Normal appearance of the hepatic and portal vasculature.



**PATIENT**

Echo Dodge

**SPECIES**

Canine

**BREED**

Terrier Cross

**SEX**

Spayed female

**AGE**

11 years

**WEIGHT**

25.1 lbs

**INTERPRETED BY**

Remo Lobetti, BVSc,  
MMedVet (Med),  
PhD, Dipl. ECVIM

**IMAGING PERFORMED BY**

Yvonna Aranda

**HOSPITAL NAME**

Santa Clara AH

**REFERRING VET**

Dr. Malec

**INVOICE**

68307

**DATE**

11/4/25

**Gallbladder**

The gallbladder is small containing normal anechoic bile. Normal thickness and echogenic appearance of the wall. Normal size and appearance of the cystic and common bile duct.

**Gastrointestinal**

Normal appearance of the stomach, duodenum, small intestine, ileo-cecal junction, and colon with no loss of layering, 1:3 muscularis to mucosa ratio, normal wall thickness and peristaltic activity, and no distension of the lumen.

**Pancreas**

The visible sections of the pancreas are of normal size and echogenic appearance with a regular capsule. Normal echogenic appearance of the mesentery and fat surrounding the pancreas.

**Free Abdomen**

Normal mesenteric lymph nodes.

No ascites evident.

**Thorax**

Normal appearance of the heart. No pericardial or pleural effusion evident.

**ULTRASONOGRAPHIC FINDINGS**

- Hepatopathy.

**INTERPRETATION OF THE FINDINGS & FURTHER RECOMMENDATIONS**

The appearance of the liver is similar to that on the previous ultrasound making age related reactive hyperplasia the most likely etiology with vacuolar and metabolic differential diagnosis.

Further assessment that can be considered would be FNA cytology of the liver, However, a tru cut or wedge biopsy may be required for a final etiological diagnosis.

Specific therapy would be dependent on an etiological diagnosis.

Symptomatic management of the hepatopathy that can be considered would be the use of Ursodiol with regular monitoring of liver enzyme activity.



**PATIENT**

Echo Dodge

**SPECIES**

Canine

**BREED**

Terrier Cross

**SEX**

Spayed female

**AGE**

11 years

**WEIGHT**

25.1 lbs

**INTERPRETED BY**

Remo Lobetti, BVSc,  
 MMedVet (Med),  
 PhD, Dipl. ECVIM

**IMAGING PERFORMED BY**

Yvonna Aranda

**HOSPITAL NAME**

Santa Clara AH

**REFERRING VET**

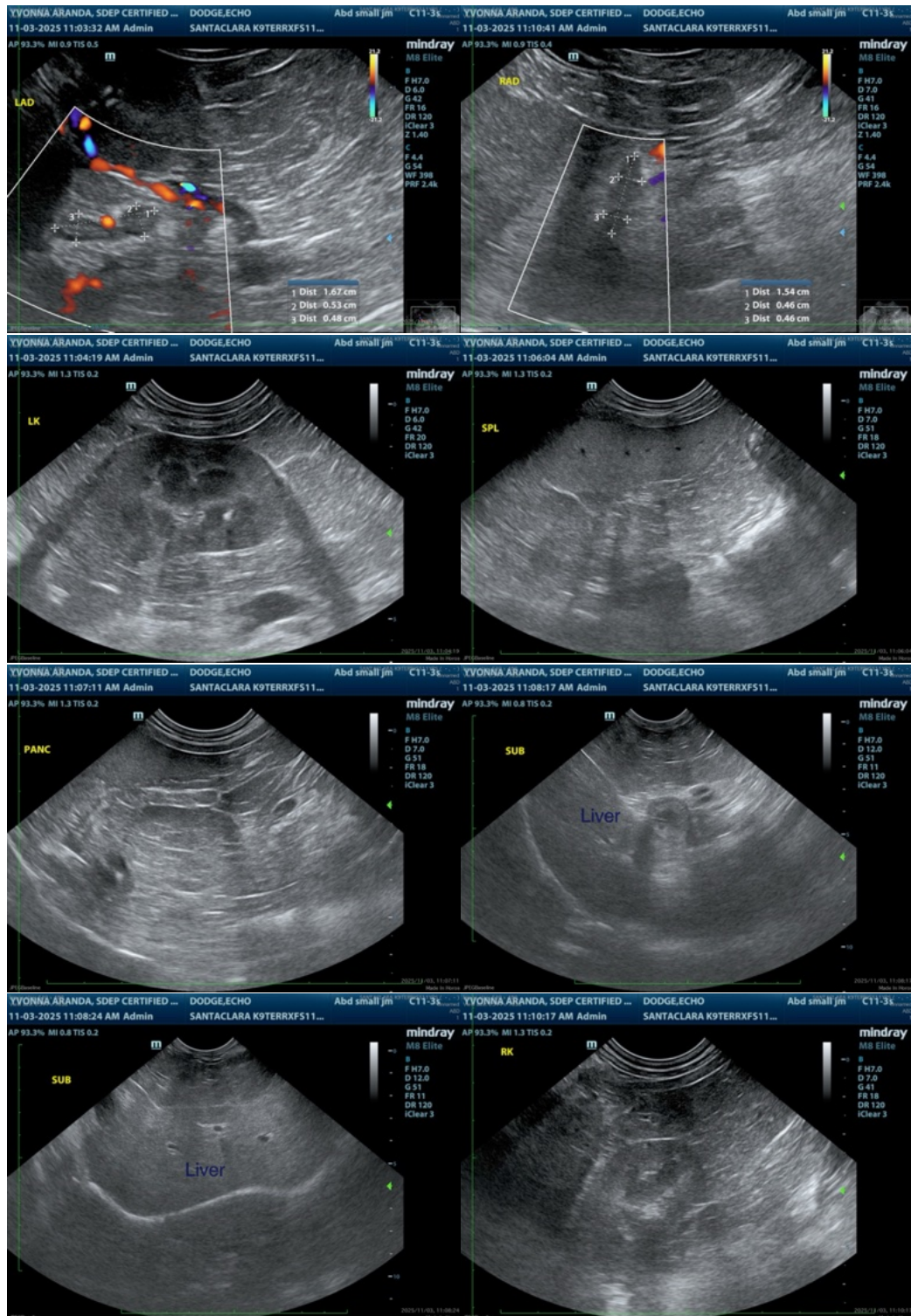
Dr. Malec

**INVOICE**

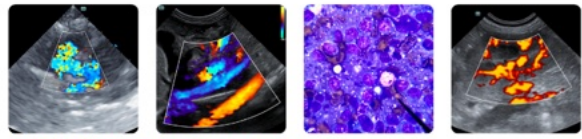
68307

**DATE**

11/4/25



The information and recommendations provided are based on the images presented by the referring veterinarian/sonographer. No evaluation can be communicated regarding pathology



**PATIENT**

Echo Dodge

**SPECIES**

Canine

**BREED**

Terrier Cross

**SEX**

Spayed female

**AGE**

11 years

**WEIGHT**

25.1 lbs

**INTERPRETED BY**

Remo Lobetti, BVSc,  
MMedVet (Med),  
PhD, Dipl. ECVIM

**IMAGING  
PERFORMED BY**

Yvonna Aranda

**HOSPITAL NAME**

Santa Clara AH

**REFERRING VET**

Dr. Malec

**INVOICE**

68307

**DATE**

11/4/25

**that was not visible in the image/video clips provided.**

Thank you for this referral. If the clinical or image interpretation does not parallel your findings or if I can be of any further assistance please contact me.

**Remo Lobetti, BVSc, MMedVet (Med), PhD, Dipl. ECVIM (Internal Medicine)**

[info@sonopath.com](mailto:info@sonopath.com)