



PATIENT	PRESENTING CLINICAL SIGNS
Hunter Black	History: reason for ultrasound. Patient came in last night for vomiting. P is very lethargic and nauseous. P had diarrhea during the night.
SPECIES	
Canine	
BREED	
Blue Heeler	
SEX	
Intact Male	
AGE	
4 months	
WEIGHT	
20 lbs	
INTERPRETED BY	
Remo Lobetti, BVSc, MMedVet (Med), PhD, Dipl. ECVIM	
IMAGING PERFORMED BY	
Brent Crutchfield, DVM	
HOSPITAL NAME	
Treasure Coast ER	
REFERRING VET	
Dr. Cail, DVM	
INVOICE	
13995	
DATE	
8.8.23	
	ULTRASONOGRAPHIC EXAMINATION OF THE ABDOMEN
	Urinary System
	The urinary bladder is full with a normal thickness and smooth appearance of the wall (measuring 0.20 cm). Normal anechoic urine with no sediment or uroliths evident.
	Reproductive System
	Normal appearance of the trigone area, proximal urethra, and iliac blood vessels.
	Adrenal Glands
	Normal appearance and size of the iliac lymph nodes. Ureters not visualized, which can be considered a normal finding.
	Normal renal size (left kidney 6.0 cm) (right kidney 5.1 cm), architecture, echogenic appearance, cortico-medullary differentiation, which maintains a 1:3 cortex to medulla ratio, pelvis, and capsule. No infarcts, mineralization or renoliths evident.
	Spleen
	Normal size and appearance of the testicles. Normal size and echogenic appearance of the prostate (measuring 0.80 cm).
	Normal shape, echogenic appearance, size (left 0.45 cm) (right 0.51 cm), position, and appearance of the visible peri-renal vasculature.
	Liver
	Normal size (measuring 1.30 cm) and echogenic appearance. Smooth homogenous parenchyma and regular curvilinear capsule. Normal volume of the splenic vasculature without any overt congestion or thrombosis evident. No inflammatory, neoplastic, infarction, or infiltrative changes evident.
	Gallbladder
	Normal size, echogenic appearance, portal markings, and regular curvilinear capsule. No nodules or masses evident. Normal appearance of the hepatic and portal vasculature.
	Gastrointestinal
	The gallbladder is full containing scant amount of hyperechogenic sediment. Normal thickness and echogenic appearance of the wall (measuring 0.10 cm). Normal size and appearance of the cystic and common bile duct.
	Normal appearance of the gastroesophageal junction, duodenum, ileo-cecal junction, and colon (measuring 0.18 cm) with no loss of layering, and no distention of the lumen. Segmental thickening of the stomach (up to 0.61 cm) and small intestines (0.52 cm) with no loss of layering, maintaining a 1:3 muscularis to mucosa ratio, normal peristaltic activity, and no distension of the lumen. Fluid-filled colon.
	Pancreas
	Normal size and echogenic appearance. Regular capsule. Normal echogenic appearance of the mesentery and fat surrounding the pancreas.



PATIENT *Free Abdomen*

Normal mesenteric lymph nodes.

Hunter Black

SPECIES

No ascites evident.

Canine

ULTRASONOGRAPHIC FINDINGS

BREED

Primary Findings

Blue Heeler

- Gastroenteropathy

SEX

Secondary Findings

Intact Male

- None

AGE

INTERPRETATION OF THE FINDINGS & FURTHER RECOMMENDATIONS

4 months

The most likely etiology for the gastroenteropathy would be nonspecific gastroenteritis, such as dietary indiscretion, toxins, viral and parasites. No evidence of a gastroenteritis foreign body evident on this ultrasound.

WEIGHT

20 lbs

Symptomatic management would be fluid therapy, correction of any electrolyte anomalies (if needed), antiemetics, intestinal binders/absorbents and feeding small, frequent meals of an intestinal diet.

INTERPRETED BY

Remo Lobetti, BVSc,
MMedVet (Med),
PhD, Dipl. ECVIM

IMAGING PERFORMED BY

Brent Crutchfield,
DVM

HOSPITAL NAME

Treasure Coast ER

REFERRING VET

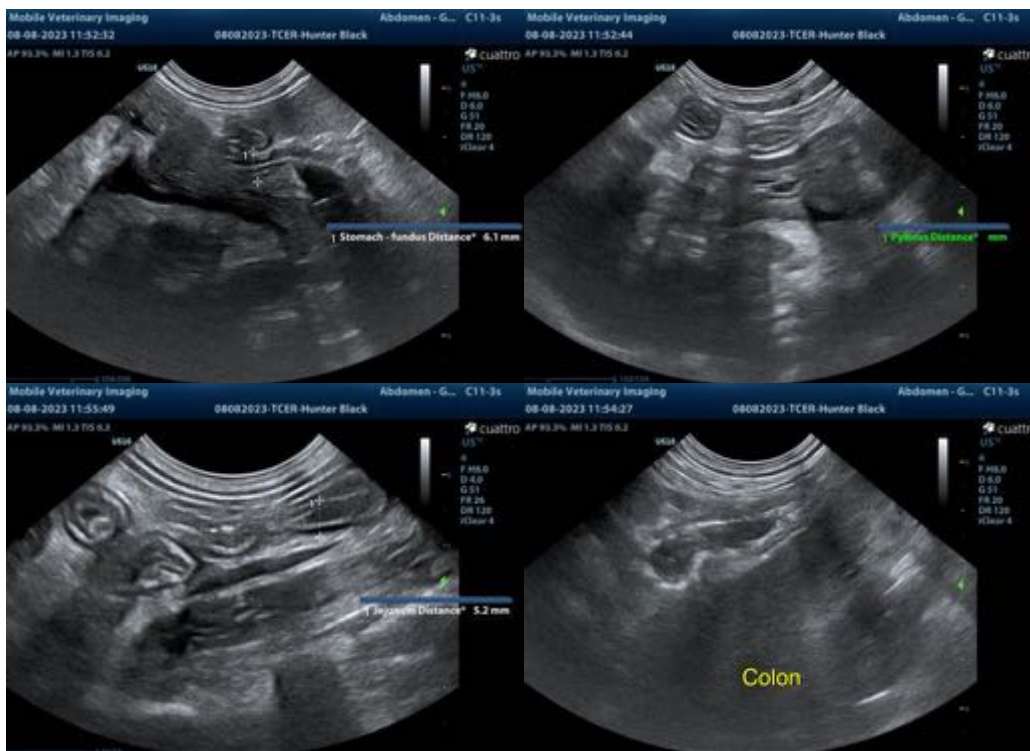
Dr. Cail, DVM

INVOICE

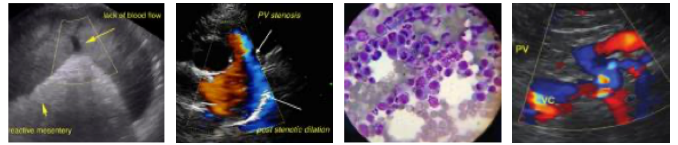
13995

DATE

8.8.23



The information and recommendations provided are based on the images presented by the referring veterinarian. No evaluation can be communicated regarding pathology that was not visible in the image/video clips provided.



PATIENT

Hunter Black

Thank you for this referral. If the clinical or image interpretation does not parallel your findings or if I can be of any further assistance, please contact me.

SPECIES

Canine

Remo Lobetti, BVSc, MMedVet (Med), PhD, Dipl. ECVIM (Internal Medicine)
info@sonopath.com

BREED

Blue Heeler

SEX

Intact Male

AGE

4 months

WEIGHT

20 lbs

INTERPRETED BY

Remo Lobetti, BVSc,
MMedVet (Med),
PhD, Dipl. ECVIM

**IMAGING
PERFORMED BY**

Brent Crutchfield,
DVM

HOSPITAL NAME

Treasure Coast ER

REFERRING VET

Dr. Cail, DVM

INVOICE

13995

DATE

8.8.23