



PATIENT	PRESENTING CLINICAL SIGNS
Bello Escoriza	History: Proteinuria (UPC 2.9) and elevated ALKP (485). O reports a little PU/PD. PT is gaining weight. Lepto neg. - LDDST 8 hr post was 1.8 - normal, USG 1033
SPECIES	
Canine	ULTRASONOGRAPHIC EXAMINATION OF THE ABDOMEN
BREED	Urinary System
Pomeranian	The urinary bladder is full with a normal thickness and smooth appearance of the wall. Normal anechoic urine with no sediment or uroliths evident.
SEX	Normal appearance of the trigone area, proximal urethra, and iliac blood vessels.
Neutered Male	Normal appearance and size of the iliac lymph nodes. Ureters not visualized, which can be considered a normal finding.
AGE	
6 years	Normal renal size (left kidney 4.30 cm) (right kidney 4.60 cm), with increased echogenic appearance, loss of cortico-medullary differentiation, and normal pelvis and capsule. No infarcts, mineralization or renoliths evident.
WEIGHT	
7.1 kg	Reproductive System
INTERPRETED BY	Small hypoechoic prostate (measuring 0.60 cm).
Remo Lobetti, BVSc, MMedVet (Med), PhD, Dipl. ECVIM	Adrenal Glands
	Normal shape, echogenic appearance, size (left 0.46 cm) (right 0.57 cm), position, and appearance of the visible peri-renal vasculature.
IMAGING PERFORMED BY	Spleen
Seth	Normal size and echogenic appearance. Smooth homogenous parenchyma and regular curvilinear capsule. Normal volume of the splenic vasculature without any overt congestion or thrombosis evident. No inflammatory, neoplastic, infarction, or infiltrative changes evident.
HOSPITAL NAME	Liver
Treasure Coast ER	Normal size, echogenic appearance, portal markings, and regular curvilinear capsule. No nodules or masses evident. Normal appearance of the hepatic and portal vasculature.
REFERRING VET	Gallbladder
Seth	The gallbladder is full containing normal anechoic bile. Normal thickness and echogenic appearance of the wall. Normal size and appearance of the cystic and common bile duct (measuring 0.10 cm).
INVOICE	Gastrointestinal
13997	Normal appearance of the stomach (measuring 0.32 cm), duodenum (0.27 cm), jejunum (measuring 0.24 cm) small intestine, ileo-cecal junction, and colon with no loss of layering, 1:3 muscularis to mucosa ratio, normal wall thickness and peristaltic activity, and no distension of the lumen. Moderate amount of ingesta within the stomach
DATE	Pancreas
8.8.23	Normal size (right 1.10 cm) and echogenic appearance. Regular capsule. Normal echogenic appearance of the mesentery and fat surrounding the pancreas.
	Free Abdomen



PATIENT Normal mesenteric lymph nodes.

Bello Escoriza No ascites evident.

SPECIES **ULTRASONOGRAPHIC FINDINGS**

Canine **Primary Findings**

- Renal disease vs age-related renal changes

Pomeranian **Secondary Findings**

- None

Neutered Male

INTERPRETATION OF THE FINDINGS & FURTHER RECOMMENDATIONS

AGE

6 years Further assessment of the kidneys and the proteinuria would be urine culture, blood pressure, renal function (urea, creatinine and SDMA) and serum phosphate assay. Renal biopsies could also be considered.

WEIGHT

7.1 kg Specific therapy would be dependent on an etiological diagnosis. Symptomatic management of the proteinuria would be feeding a renal diet and the use of either an ACE inhibitor or receptor blocker.

INTERPRETED BY

Remo Lobetti, BVSc,
MMedVet (Med),
PhD, Dipl. ECVIM

IMAGING PERFORMED BY

Seth

HOSPITAL NAME

Treasure Coast ER

REFERRING VET

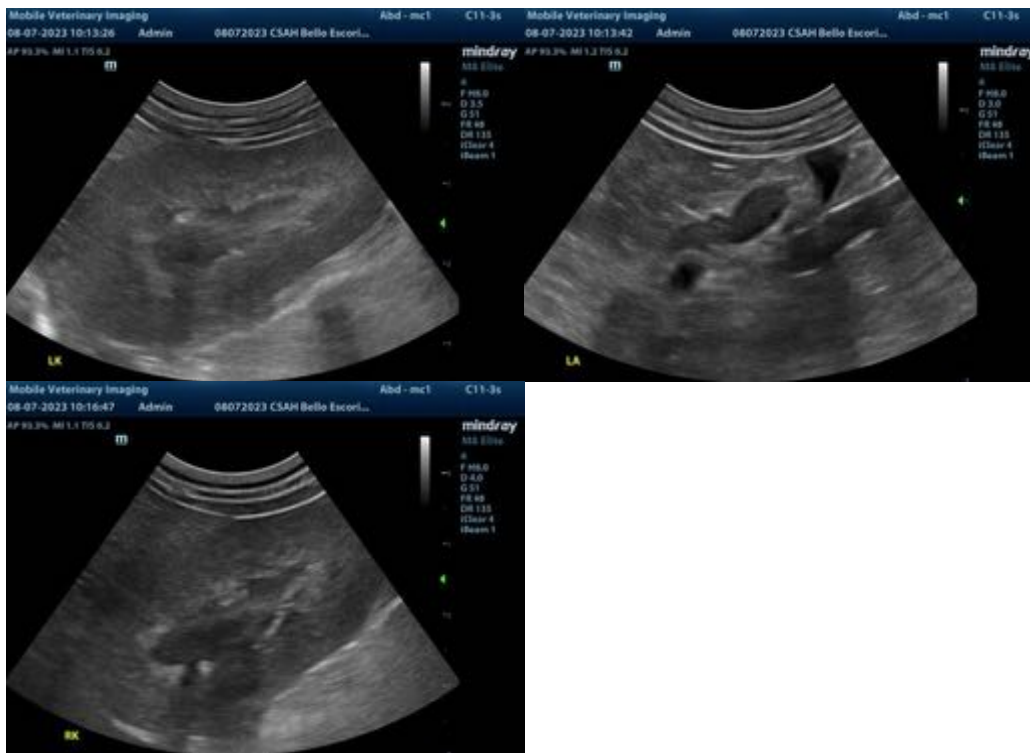
Seth

INVOICE

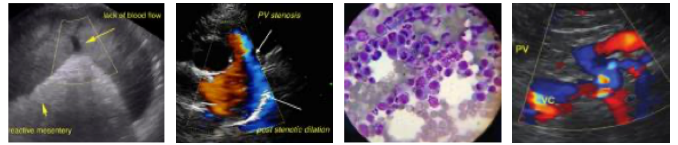
13997

DATE

8.8.23



The information and recommendations provided are based on the images presented by the referring veterinarian. No evaluation can be communicated regarding pathology that was not visible in the image/video clips provided.



PATIENT

Thank you for this referral. If the clinical or image interpretation does not parallel your findings or if I can be of any further assistance, please contact me.

Bello Escoriza

SPECIES

Remo Lobetti, BVSc, MMedVet (Med), PhD, Dipl. ECVIM (Internal Medicine)
info@sonopath.com

Canine

BREED

Pomeranian

SEX

Neutered Male

AGE

6 years

WEIGHT

7.1 kg

INTERPRETED BY

Remo Lobetti, BVSc,
MMedVet (Med),
PhD, Dipl. ECVIM

**IMAGING
PERFORMED BY**

Seth

HOSPITAL NAME

Treasure Coast ER

REFERRING VET

Seth

INVOICE

13997

DATE

8.8.23