



PATIENT	PRESENTING CLINICAL SIGNS
Scooby Gardner	History: Long-term vomiting.
SPECIES	ULTRASONOGRAPHIC EXAMINATION OF THE ABDOMEN
Canine	Urinary System
BREED	The urinary bladder is full with a normal thickness (measuring 1.10 cm) and smooth appearance of the wall. Normal anechoic urine with no sediment or uroliths evident.
Boxer	Normal appearance of the trigone area, proximal urethra, and iliac blood vessels.
SEX	Normal appearance and size of the iliac lymph nodes. Ureters not visualized, which can be considered a normal finding.
Female Spayed	
AGE	Normal renal size (left kidney 5.70 cm) (right kidney 6.2 cm), architecture, echogenic appearance, cortico-medullary differentiation, which maintains a 1:3 cortex to medulla ratio, pelvis, and capsule. No infarcts, mineralization or renoliths evident.
11.5 years	
WEIGHT	Adrenal Glands
NP	Normal shape, echogenic appearance, size (left 0.84 cm) (right 0.72 cm), position, and appearance of the visible peri-renal vasculature.
INTERPRETED BY	Spleen
Remo Lobetti, BVSc, MMedVet (Med), PhD, Dipl. ECVIM	Normal size (measuring 1.40 cm) and echogenic appearance. Smooth homogenous parenchyma and regular curvilinear capsule. Normal volume of the splenic vasculature without any overt congestion or thrombosis evident. No inflammatory, neoplastic, infarction, or infiltrative changes evident.
IMAGING PERFORMED BY	Liver
Brent Crutchfield, DVM	Normal size, echogenic appearance, portal markings, and regular curvilinear capsule. No nodules or masses evident. Normal appearance of the hepatic and portal vasculature.
HOSPITAL NAME	Gallbladder
Treasure Coast Emerg&Specialty	The gallbladder is full containing normal anechoic bile. Normal thickness and echogenic appearance of the wall (measuring 0.10 cm). Normal size and appearance of the cystic and common bile duct.
REFERRING VET	Gastrointestinal
Dr. Cail, DVM	Normal appearance and thickness of the gastric wall with no loss of layering. Large amount of shadowing material within the stomach, without any obvious pyloric obstruction evident. The stomach measured 0.52 cm. Normal appearance of the duodenum, jejunum (measuring 0.45 cm) small intestine, ileo-cecal junction, and colon (measuring 0.11 cm) with no loss of layering, 1:3 muscularis to mucosa ratio, normal wall thickness and peristaltic activity, and no distension of the lumen.
INVOICE	Pancreas
13966	Normal size and echogenic appearance. Regular capsule. Normal echogenic appearance of the mesentery and fat surrounding the pancreas.
DATE	Free Abdomen
8.4.23	Normal mesenteric lymph nodes.
	No ascites evident.



PATIENT **ULTRASONOGRAPHIC FINDINGS**

Scooby Gardner

Primary Findings

SPECIES

- Gastric foreign material

Canine

Secondary Findings

BREED

- None

Boxer

SEX

INTERPRETATION OF THE FINDINGS & FURTHER RECOMMENDATIONS

Female Spayed

Although the gastric foreign material may only represent recent ingestion of food, with the history, a chronic foreign body needs to be considered.

AGE

11.5 years

Further assessment would be to repeat the ultrasound after fasting, and survey abdominal radiographs. If there is no change in the appearance of the stomach on repeat ultrasound, or there is evidence of a gastric foreign body on survey radiographs, then a laparotomy should be considered. It is also possible that this patient has gastric hypermotility.

WEIGHT

NP

INTERPRETED BY

Remo Lobetti, BVSc,
MMedVet (Med),
PhD, Dipl. ECVIM

IMAGING PERFORMED BY

Brent Crutchfield,
DVM

HOSPITAL NAME

Treasure Coast
Emerg&Specialty

REFERRING VET

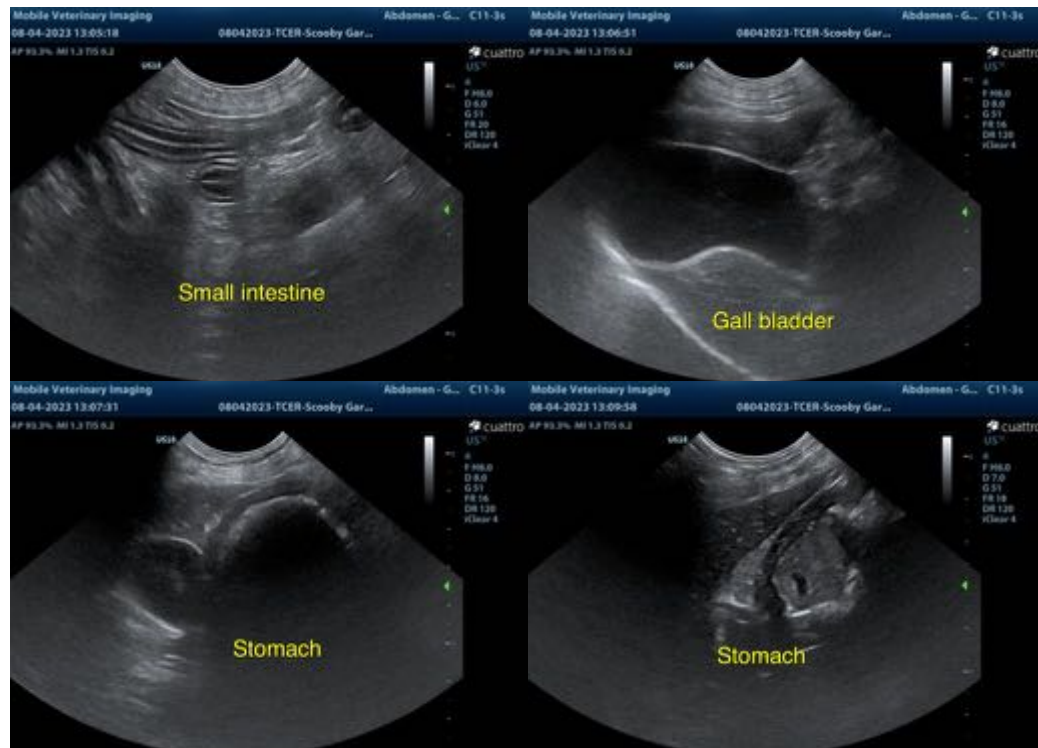
Dr. Cail, DVM

INVOICE

13966

DATE

8.4.23



The information and recommendations provided are based on the images presented by the referring veterinarian. No evaluation can be communicated regarding pathology that was not visible in the image/video clips provided.

Thank you for this referral. If the clinical or image interpretation does not parallel your findings or if I can be of any further assistance, please contact me.



PATIENT

Remo Lobetti, BVSc, MMedVet (Med), PhD, Dipl. ECVIM (Internal Medicine)
info@sonopath.com

Scooby Gardner

SPECIES

Canine

BREED

Boxer

SEX

Female Spayed

AGE

11.5 years

WEIGHT

NP

INTERPRETED BY

Remo Lobetti, BVSc,
MMedVet (Med),
PhD, Dipl. ECVIM

**IMAGING
PERFORMED BY**

Brent Crutchfield,
DVM

HOSPITAL NAME

Treasure Coast
Emerg&Specialty

REFERRING VET

Dr. Cail, DVM

INVOICE

13966

DATE

8.4.23