



PATIENT PRESENTING CLINICAL SIGNS

Coco Rucks History: O states patient has abdominal mass. Chronic UTIs

SPECIES ULTRASONOGRAPHIC EXAMINATION OF THE ABDOMEN

Feline Urinary System

The urinary bladder is full with a normal thickness (0.20 cm) and smooth appearance of the wall. Normal anechoic urine with no sediment or uroliths evident.

BREED

Normal appearance of the trigone area, proximal urethra, and iliac blood vessels.

DSH

SEX

Normal appearance and size of the iliac lymph nodes. Ureters not visualized, which can be considered a normal finding.

Female Spayed

AGE

Normal renal size (left kidney 4.00 cm) (right kidney 3.50 cm), architecture, echogenic appearance, cortico-medullary differentiation, which maintains a 1:3 cortex to medulla ratio, pelvis, and capsule. No infarcts, mineralization or renoliths evident.

18 years

Adrenal Glands

Normal shape, echogenic appearance, size (left 0.48 cm) (right 0.40 cm), position, and appearance of the visible peri-renal vasculature.

WEIGHT

15 lbs

Spleen

Normal size (0.90 cm) and echogenic appearance. Smooth homogenous parenchyma and regular curvilinear capsule. Normal volume of the splenic vasculature without any overt congestion or thrombosis evident. No inflammatory, neoplastic, infarction, or infiltrative changes evident.

INTERPRETED BY

Remo Lobetti, BVSc,
MMedVet (Med),
PhD, Dipl. ECVIM

Liver

Normal size, echogenic appearance, portal markings, and regular curvilinear capsule. No nodules or masses evident. Normal appearance of the hepatic and portal vasculature.

IMAGING PERFORMED BY

Dr Crutchfield

Gallbladder

The gallbladder is small containing normal anechoic bile. Normal thickness (0.10 cm) and echogenic appearance of the wall. Normal size and appearance of the cystic and common bile duct.

HOSPITAL NAME

Mobile Vet Imaging

Gastrointestinal

Normal appearance of the stomach (0.42 cm), duodenum (0.37 cm), jejunum (measuring 0.21 cm) small intestine, ileo-cecal junction, and colon with no loss of layering, 1:3 muscularis to mucosa ratio, normal wall thickness and peristaltic activity, and no distension of the lumen.

REFERRING VET

Dr Cail

Pancreas

Normal size and echogenic appearance. Regular capsule. Normal echogenic appearance of the mesentery and fat surrounding the pancreas.

INVOICE

14107

Free Abdomen

Normal mesenteric lymph nodes.

No ascites evident.

DATE

8.15.23



PATIENT ULTRASONOGRAPHIC FINDINGS

Coco Rucks **Primary Findings**

- None

Secondary Findings

- None

BREED

DSH

SEX

INTERPRETATION OF THE FINDINGS & FURTHER RECOMMENDATIONS

Normal ultrasound examination of the abdomen.

Female Spayed

AGE

18 years

WEIGHT

15 lbs

INTERPRETED BY

Remo Lobetti, BVSc,
MMedVet (Med),
PhD, Dipl. ECVIM

IMAGING PERFORMED BY

Dr Crutchfield

HOSPITAL NAME

Mobile Vet Imaging

REFERRING VET

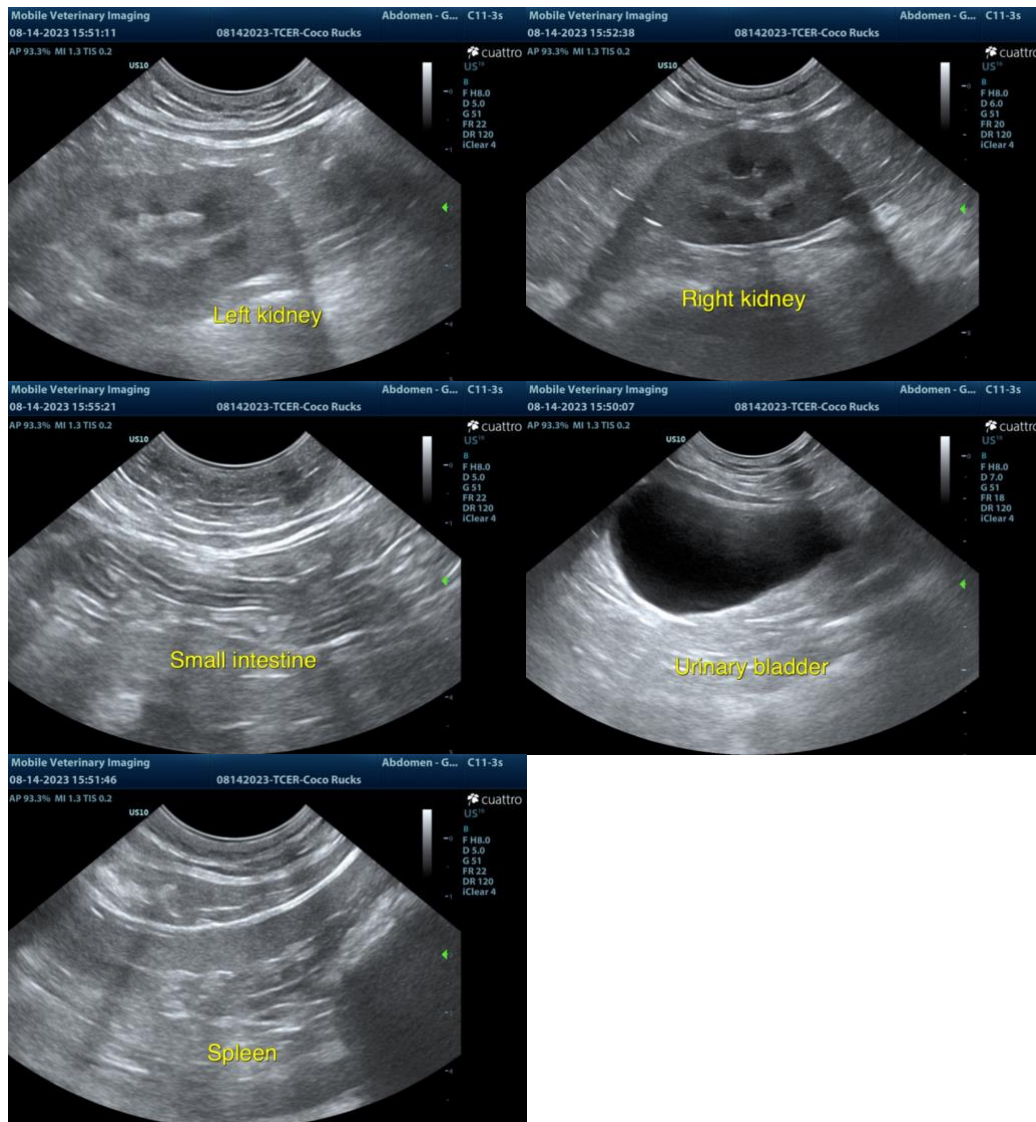
Dr Cail

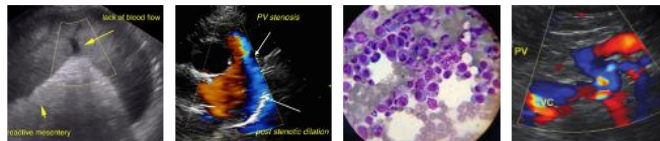
INVOICE

14107

DATE

8.15.23





PATIENT The information and recommendations provided are based on the images presented by the referring veterinarian. No evaluation can be communicated regarding pathology that was not visible in the image/video clips provided.

Coco Rucks

SPECIES Thank you for this referral. If the clinical or image interpretation does not parallel your findings or if I can be of any further assistance, please contact me.

Feline

Remo Lobetti, BVSc, MMedVet (Med), PhD, Dipl. ECVIM (Internal Medicine)
info@sonopath.com

BREED

DSH

SEX

Female Spayed

AGE

18 years

WEIGHT

15 lbs

INTERPRETED BY

Remo Lobetti, BVSc,
MMedVet (Med),
PhD, Dipl. ECVIM

**IMAGING
PERFORMED BY**

Dr Crutchfield

HOSPITAL NAME

Mobile Vet Imaging

REFERRING VET

Dr Cail

INVOICE

14107

DATE

8.15.23