



**PATIENT PRESENTING CLINICAL SIGNS**

**Lulu Littlejohn** History: Vomiting 2 weeks, sometimes bile, sometimes food. Acting strange, biting mom's legs, lethargic, needy, decreased appetite. Normal BM's, normal urinations. Increased shedding. Licking aggressively. Chews objects around the house, plants (peonies recently), no other house plants recently. Indoor only, does go in garage and basement. Seen at Yarmouth vet last week, given nausea meds, IV fluids. Lots of stool noted in colon, dehydrated. Vomiting did not improve after that. Not on F/T preventative

**SPECIES** Feline

**BREED** Abnormal PE/Chem/CBC/UA Results: CBC/Chem/Lytes- normal

**DSH ULTRASONOGRAPHIC EXAMINATION OF THE ABDOMEN**

**SEX** *Urinary System*

Female Spayed The urinary bladder is full with a normal thickness and smooth appearance of the wall. Normal anechoic urine with no sediment or uroliths evident.

**AGE** Normal appearance of the trigone area, proximal urethra, and iliac blood vessels.

2 years Normal appearance and size of the iliac lymph nodes. Ureters not visualized, which can be considered a normal finding.

**WEIGHT** 3.44 kg Normal renal size (left kidney 3.20 cm / right kidney 3.50 cm), architecture, echogenic appearance, cortico-medullary differentiation, which maintains a 1:3 cortex to medulla ratio, pelvis, and capsule. No infarcts, mineralization or renoliths evident.

**INTERPRETED BY**

Remo Lobetti, BVSc, MMedVet (Med), PhD, Dipl. ECVIM

*Adrenal Glands*

Normal shape, echogenic appearance, size (left 0.33 cm), position, and appearance of the visible peri-renal vasculature.

**IMAGING PERFORMED BY**

Amy Hess

*Spleen*

Normal size (0.80 cm) and echogenic appearance. Smooth homogenous parenchyma and regular curvilinear capsule. Normal volume of the splenic vasculature without any overt congestion or thrombosis evident. No inflammatory, neoplastic, infarction, or infiltrative changes evident.

**HOSPITAL NAME**

Petmedic Urgent Care VC

*Liver*

Normal size, echogenic appearance, portal markings, and regular curvilinear capsule. No nodules or masses evident. Normal appearance of the hepatic and portal vasculature.

**REFERRING VET**

Amy Hess

*Gallbladder*

The gallbladder is full containing normal anechoic bile. Normal thickness and echogenic appearance of the wall. Normal size and appearance of the cystic and common bile duct.

**INVOICE**

13624

*Gastrointestinal*

Normal appearance of the stomach, duodenum, small intestine, ileo-cecal junction, and colon with no loss of layering, 1:3 muscularis to mucosa ratio, normal wall thickness and peristaltic activity, and no distension of the lumen. Fecal material within the colon

**DATE**

7.8.23

*Pancreas*

Normal size and echogenic appearance. Regular capsule. Normal echogenic appearance of the mesentery and fat surrounding the pancreas.

*Free Abdomen*

Normal mesenteric lymph nodes.



**PATIENT**

Lulu Littlejohn

**SPECIES**

Feline

**BREED**

DSH

**SEX**

Female Spayed

**AGE**

2 years

**WEIGHT**

3.44 kg

**INTERPRETED BY**

Remo Lobetti, BVSc,  
MMedVet (Med), PhD,  
Dipl. ECVIM

**IMAGING PERFORMED BY**

Amy Hess

**HOSPITAL NAME**

Petmedic  
Urgent Care VC

**REFERRING VET**

Amy Hess

**INVOICE**

13624

**DATE**

7.8.23

No ascites evident.

**ULTRASONOGRAPHIC FINDINGS**

**Primary Findings**

- None

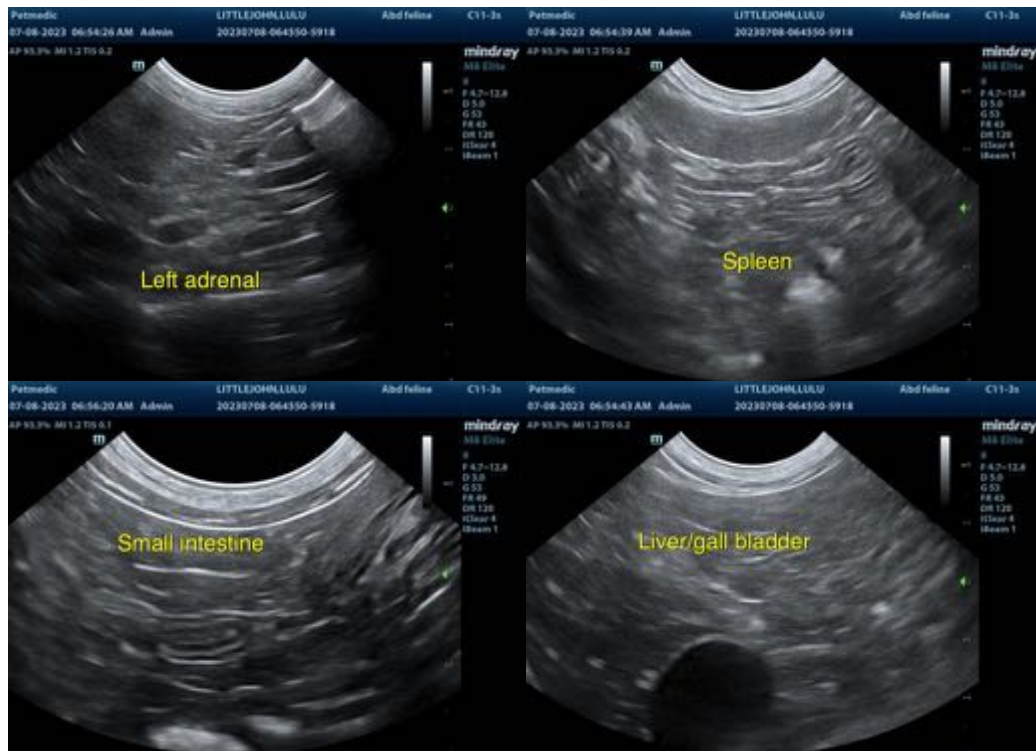
**Secondary Findings**

- None

**INTERPRETATION OF THE FINDINGS & FURTHER RECOMMENDATIONS**

Normal ultrasound examination of the abdomen with no obvious etiology for the presenting clinical signs.

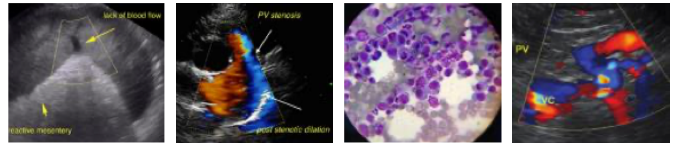
With the presenting clinical signs, primary neurological disease should also be considered.



The information and recommendations provided are based on the images presented by the referring veterinarian. No evaluation can be communicated regarding pathology that was not visible in the image/video clips provided.

Thank you for this referral. If the clinical or image interpretation does not parallel your findings or if I can be of any further assistance, please contact me.

Remo Lobetti, BVSc, MMedVet (Med), PhD, Dipl. ECVIM (Internal Medicine)



**PATIENT** [info@sonopath.com](mailto:info@sonopath.com)

Lulu Littlejohn

**SPECIES**

Feline

**BREED**

DSH

**SEX**

Female Spayed

**AGE**

2 years

**WEIGHT**

3.44 kg

**INTERPRETED BY**

Remo Lobetti, BVSc,  
MMedVet (Med), PhD,  
Dipl. ECVIM

**IMAGING  
PERFORMED BY**

Amy Hess

**HOSPITAL NAME**

Petmedic  
Urgent Care VC

**REFERRING VET**

Amy Hess

**INVOICE**

13624

**DATE**

7.8.23