



PATIENT PRESENTING CLINICAL SIGNS

Jax Warshowsky History: Suspected IBD, on hypoallergenic food and prednisolone

SPECIES ULTRASONOGRAPHIC EXAMINATION OF THE ABDOMEN

Feline **Urinary System**

BREED The urinary bladder is full, with a normal thickness and smooth appearance of the wall. Small amount of floating hyperechogenic sediment present. No uroliths evident.

DSH Normal appearance of the trigone area, proximal urethra (0.20 cm), and iliac blood vessels.

SEX Normal appearance and size of the iliac lymph nodes. Ureters not visualized, which can be considered a normal finding.

Neutered Male

AGE Normal renal size (left kidney 4.10 cm / right kidney 4.20 cm), architecture, echogenic appearance, cortico-medullary differentiation, which maintains a 1:3 cortex to medulla ratio, pelvis, and capsule. No infarcts, mineralization or renoliths evident.

6 years

WEIGHT Adrenal Glands

15 lbs Normal shape, echogenic appearance, size (left 0.35 cm / right 0.50 cm), position, and appearance of the visible peri-renal vasculature.

INTERPRETED BY

Remo Lobetti, BVSc,
MMedVet (Med),
PhD, Dipl. ECVIM

Spleen

Normal size (0.80 cm) and echogenic appearance. Smooth homogenous parenchyma and regular curvilinear capsule. Normal volume of the splenic vasculature without any overt congestion or thrombosis evident. No inflammatory, neoplastic, infarction, or infiltrative changes evident.

IMAGING PERFORMED BY

Sonya Myers DVM

Liver

Normal size, echogenic appearance, portal markings, and regular curvilinear capsule. No nodules or masses evident. Normal appearance of the hepatic and portal vasculature.

HOSPITAL NAME

Lake Emma AH

Gallbladder

The gallbladder is full, containing normal anechoic bile. Normal thickness and echogenic appearance of the wall. Normal size and appearance of the cystic and common bile duct (0.20 cm).

REFERRING VET

Lesmes

Gastrointestinal

Normal appearance of the stomach (0.28 cm), duodenum (0.21 cm), jejunum (0.23 cm) small intestine, ileocecal junction, and colon (0.13 cm) with no loss of layering, 1:3 muscularis to mucosa ratio, normal wall thickness and peristaltic activity, and no distension of the lumen.

INVOICE

13625

Pancreas

Enlarged (1.23 cm) and hypoechoic appearance of the right lobe, with an irregular capsule and a hyperechogenic appearance of the surrounding mesentery and fat. Normal size (1.00 cm) and appearance of the left lobe with a regular capsule.

DATE

7.8.23

Free Abdomen

Normal mesenteric lymph nodes (0.70 cm).

No ascites evident.

ULTRASONOGRAPHIC FINDINGS



PATIENT Primary Findings

Jax Warshowsky

- Pancreatitis
- Secondary Findings

SPECIES

Feline

- Urinary bladder sediment

BREED

INTERPRETATION OF THE FINDINGS & FURTHER RECOMMENDATIONS

DSH

The appearance of the pancreas is consistent with pancreatitis, and possibly associated with a historical enteropathy.

SEX

Neutered Male

On this ultrasound, the GIT tract appears ultrasonographically normal, and thus appears to be well-controlled with the current therapy of prednisolone and a hypoallergenic diet.

AGE

6 years

Further assessment would be urinalysis, urine culture and fPL/PSL assay.

WEIGHT

15 lbs

Management of the pancreatitis would be feeding small, frequent meals and antiemetics and analgesics as needed.

INTERPRETED BY

Remo Lobetti, BVSc,
MMedVet (Med),
PhD, Dipl. ECVIM

IMAGING PERFORMED BY

Sonya Myers DVM

HOSPITAL NAME

Lake Emma AH

REFERRING VET

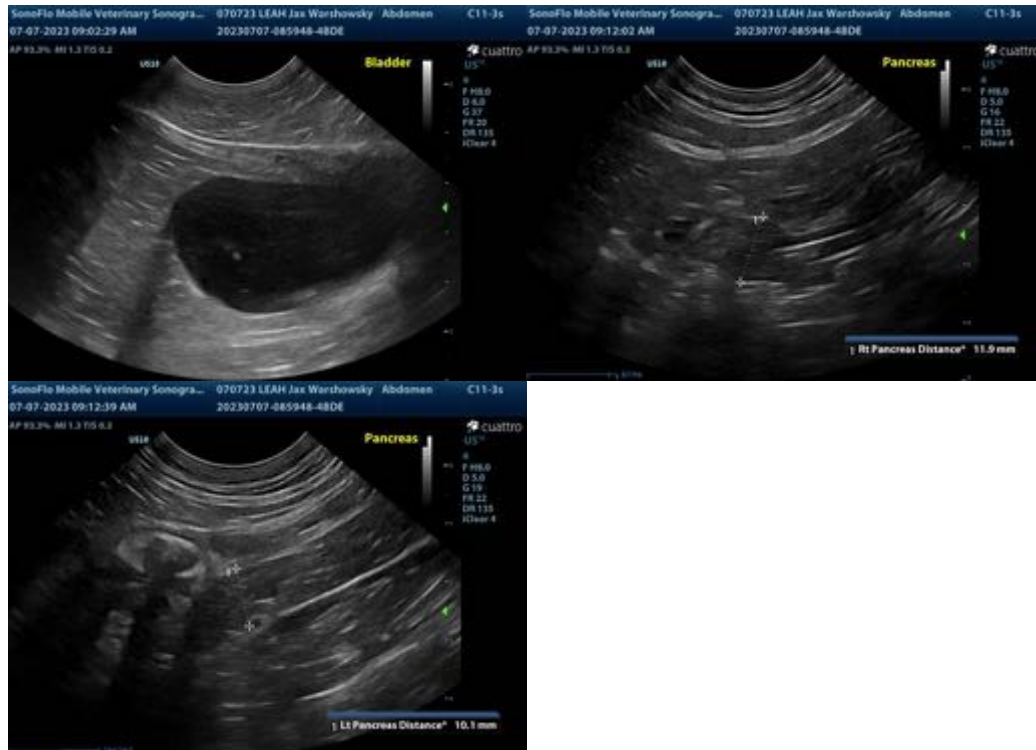
Lesmes

INVOICE

13625

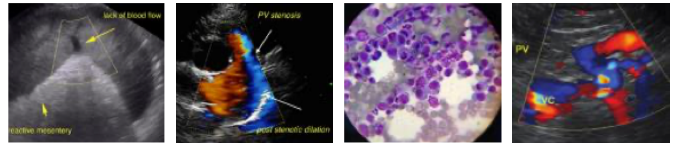
DATE

7.8.23



The information and recommendations provided are based on the images presented by the referring veterinarian. No evaluation can be communicated regarding pathology that was not visible in the image/video clips provided.

Thank you for this referral. If the clinical or image interpretation does not parallel your findings or if I can be of any further assistance, please contact me.



PATIENT

Remo Lobetti, BVSc, MMedVet (Med), PhD, Dipl. ECVIM (Internal Medicine)
info@sonopath.com

Jax Warshowsky

SPECIES

Feline

BREED

DSH

SEX

Neutered Male

AGE

6 years

WEIGHT

15 lbs

INTERPRETED BY

Remo Lobetti, BVSc,
MMedVet (Med),
PhD, Dipl. ECVIM

**IMAGING
PERFORMED BY**

Sonya Myers DVM

HOSPITAL NAME

Lake Emma AH

REFERRING VET

Lesmes

INVOICE

13625

DATE

7.8.23