

PATIENT

Marley Hoskins

SPECIES

Canine

BREED

Boxer

SEX

Spayed Female

AGE

5 years

WEIGHT

56.5 lbs

INTERPRETED BY

Remo Lobetti, BVSc,
MMedVet (Med), PhD,
Dipl. ECVIM

IMAGING PERFORMED BY

Sara Hansen

HOSPITAL NAME

West Eugene AH

REFERRING VET

Dr McCurry

INVOICE

13583

DATE

7.6.23

PRESENTING CLINICAL SIGNS

History: QAR Thin O says throwing up often Anorexic Has had 2 seizures in teh past year

Abnormal PE/Chem/CBC/UA Results: ALP-495 ALT-1677 AST-458 Tbili-1.8 T4<.5 Current Medications Mirtazapine Radiographic Findings None

ULTRASONOGRAPHIC EXAMINATION OF THE ABDOMEN

Urinary System

The urinary bladder is full, with a normal thickness and smooth appearance of the wall. Normal anechoic urine with no sediment or uroliths evident.

Normal appearance of the trigone area, proximal urethra, and iliac blood vessels.

Normal appearance and size of the iliac lymph nodes. Ureters not visualized, which can be considered a normal finding.

Normal renal size (left kidney 8.30 cm) (right kidney 8.10 cm), architecture, echogenic appearance, cortico-medullary differentiation, which maintains a 1:3 cortex to medulla ratio, pelvis, and capsule. No infarcts, mineralization or renoliths evident.

Adrenal Glands

The left gland is of normal shape, echogenic appearance, size (2.80 cm in length x 0.57 x 0.69 cm), position, and appearance of the visible surrounding vasculature. The right adrenal gland is poorly visualized, but appears to be of normal shape, echogenic appearance and size.

Spleen

Normal size (2.90 cm) with a diffuse, mottled echogenic and “moth-eaten” appearance. Smooth homogenous parenchyma and regular curvilinear capsule. Normal volume of the splenic vasculature without any overt congestion or thrombosis evident.

Liver

Normal size, echogenic appearance, portal markings, and regular curvilinear capsule. No nodules or masses evident. Normal appearance of the hepatic and portal vasculature.

Gallbladder

The gallbladder is full, containing normal anechoic bile. Normal thickness and echogenic appearance of the wall. Normal size and appearance of the cystic and common bile duct.

Gastrointestinal

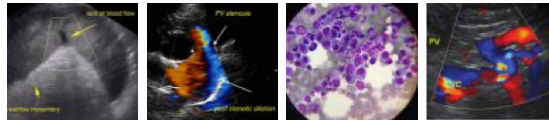
Normal appearance of the stomach, duodenum, small intestine, ileo-cecal junction, and colon with no loss of layering, 1:3 muscularis to mucosa ratio, normal wall thickness and peristaltic activity, and no distension of the lumen.

Pancreas

Normal size and echogenic appearance. Regular capsule. Normal echogenic appearance of the mesentery and fat surrounding the pancreas.

Free Abdomen

Normal mesenteric lymph nodes.



PATIENT

Marley Hoskins

No ascites evident.

SPECIES

Canine

ULTRASONOGRAPHIC FINDINGS

Primary Findings

- Splenic pathology

BREED

Boxer

Secondary Findings

- None

SEX

Spayed Female

INTERPRETATION OF THE FINDINGS & FURTHER RECOMMENDATIONS

Etiologies for the spleen would be reactive, hyperplasia, splenitis and infiltrative neoplasia (possible lymphoma).

AGE

5 years

Although the liver appeared ultrasonographically normal, with the elevated liver enzyme activity, acute hepatitis (viral, bacterial, toxins and Leptospirosis) still needs to be considered.

WEIGHT

56.5 lbs

Further assessment would be three-view thoracic radiographs and FNA cytology of the liver and spleen.

Specific therapy would be dependent on an etiological diagnosis. Symptomatic management would be Ursodiol.

INTERPRETED BY

Remo Lobetti, BVSc,
MMedVet (Med), PhD,
Dipl. ECVIM

IMAGING PERFORMED BY

Sara Hansen

HOSPITAL NAME

West Eugene AH

REFERRING VET

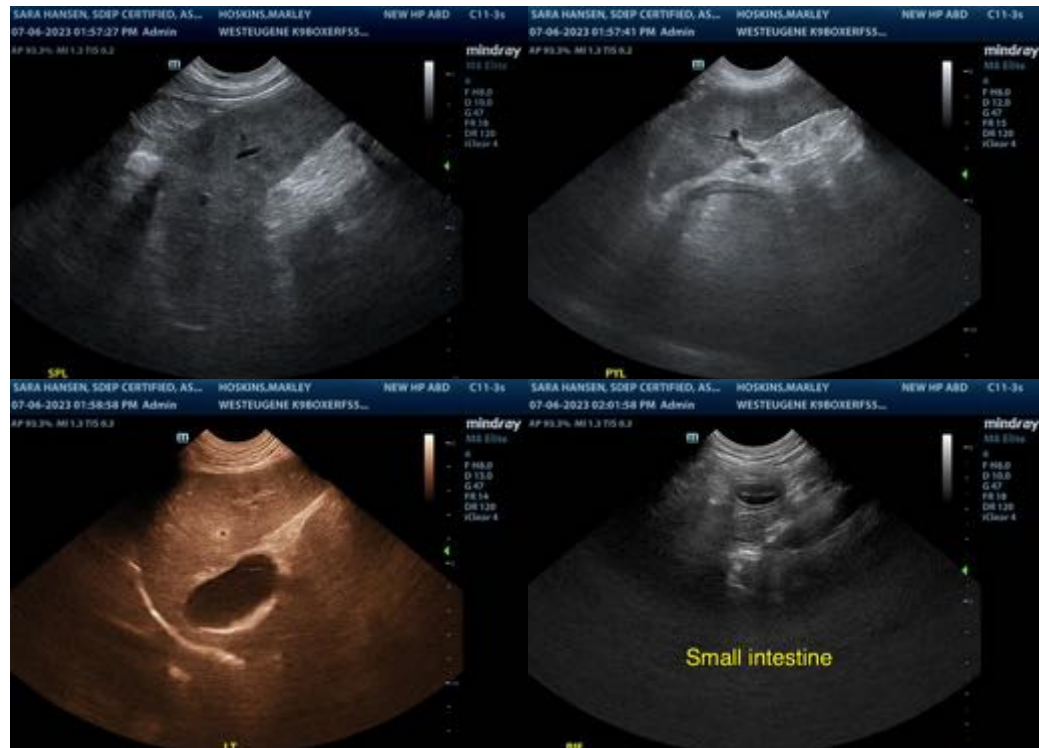Dr McCurry

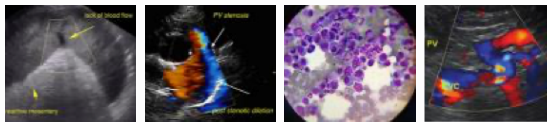
INVOICE

13583

DATE

7.6.23





PATIENT

Marley Hoskins

The information and recommendations provided are based on the images presented by the referring veterinarian. No evaluation can be communicated regarding pathology that was not visible in the image/video clips provided.

SPECIES

Canine

Thank you for this referral. If the clinical or image interpretation does not parallel your findings or if I can be of any further assistance, please contact me.

BREED

Boxer

Remo Lobetti, BVSc, MMedVet (Med), PhD, Dipl. ECVIM (Internal Medicine)
info@sonopath.com

SEX

Spayed Female

AGE

5 years

WEIGHT

56.5 lbs

INTERPRETED BY

Remo Lobetti, BVSc,
MMedVet (Med), PhD,
Dipl. ECVIM

**IMAGING
PERFORMED BY**

Sara Hansen

HOSPITAL NAME

West Eugene AH

REFERRING VET

Dr McCurry

INVOICE

13583

DATE

7.6.23