



**PATIENT PRESENTING CLINICAL SIGNS**

**Flame Collins** History: P presents for a dental cleaning. Chronic stage 2/4 CKD, managed on renal diet. Creatinine has ranged from high 2's to low 3's. In the last few weeks, P has become more lethargic and hyporexic. AUS performed under GA today at dental.

**SPECIES**

Feline

Abnormal PE/Chem/CBC/UA Results: Mild monocytosis, Mild azotemia (USG 1.022). Labs attached

**ULTRASONOGRAPHIC EXAMINATION OF THE ABDOMEN**

**BREED**

**Urinary System**

DSH

The urinary bladder is full, with a normal thickness and smooth appearance of the wall. A small amount of floating hyperechogenic sediment is present. No uroliths evident.

**SEX**

Normal appearance of the trigone area, proximal urethra, and iliac blood vessels.

Neutered Male

Normal appearance and size of the iliac lymph nodes. Ureters not visualized, which can be considered a normal finding.

**AGE**

11 years

Small left kidney (2.40 cm). Normal size of right kidney (3.10 cm), both with increased echogenic appearance, loss of cortico-medullary differentiation, and normal pelvis. Irregular capsule. No infarcts, mineralization or renoliths evident.

**WEIGHT**

10.3 lbs

**Adrenal Glands**

Normal shape, echogenic appearance, size (left 0.55 cm) (right 0.42 cm), position, and appearance of the visible peri-renal vasculature.

**Spleen**

Normal size (0.80 cm) and echogenic appearance. Smooth homogenous parenchyma and regular curvilinear capsule. Normal volume of the splenic vasculature without any overt congestion or thrombosis evident. No inflammatory, neoplastic, infarction, or infiltrative changes evident.

**INTERPRETED BY**

Remo Lobetti, BVSc,  
MMedVet (Med), PhD,  
Dipl. ECVIM

**Liver**

Normal size, echogenic appearance, portal markings, and regular curvilinear capsule. No nodules or masses evident. Normal appearance of the hepatic and portal vasculature.

**IMAGING PERFORMED BY**

Saum Hadi

**Gallbladder**

The gallbladder is full, containing small amount of hyperechogenic sediment. Normal thickness and echogenic appearance of the wall. Normal size and appearance of the cystic and common bile duct.

**HOSPITAL NAME**

Nimbus PH

**Gastrointestinal**

Normal appearance of the stomach, duodenum, small intestine, ileo-cecal junction, and colon with no loss of layering, 1:3 muscularis to mucosa ratio, normal wall thickness and peristaltic activity, and no distension of the lumen. Small amount of fluid within the stomach. Fecal material within the colon.

**REFERRING VET**

Saum Hadi

**Pancreas**

Enlarged with hypoechogenic appearance and irregular capsule. Hyperechogenic appearance of the mesentery and fat surrounding the pancreas.

**INVOICE**

13591

**Free Abdomen**

Prominent mesenteric lymph nodes, with normal size, but with a rounded shape and hypoechogenic appearance.

**DATE**

7.6.23



**PATIENT** No ascites evident.

Flame Collins **ULTRASONOGRAPHIC FINDINGS**

**Primary Findings**

**SPECIES**

Feline

- Renal disease
- Pancreatitis

**BREED**

DSH

- Lymphadenomegaly

**Secondary Findings**

**SEX**

- Gall and urinary bladder sediment

Neutered Male

**INTERPRETATION OF THE FINDINGS & FURTHER RECOMMENDATIONS**

**AGE**

11 years

The appearance of the kidneys is consistent with chronic kidney disease, and in line with the history. Bacterial nephritis and hypertensive nephropathy need to be considered as comorbidities.

The appearance of the pancreas would be consistent with chronic active pancreatitis. The lymphadenomegaly is most likely reactive hyperplasia, secondary to the pancreatitis.

**WEIGHT**

10.3 lbs

Further assessment would be full urinalysis, urine culture, UPC (if culture and sediment negative), blood pressure, and fPL/PSL assay.

Management would be to continue with the renal diet, fed as small, frequent meals, ACE inhibitor or ACE receptor blocker, analgesic, and fluid therapy as needed.

**INTERPRETED BY**

Remo Lobetti, BVSc,  
MMedVet (Med), PhD,  
Dipl. ECVIM

**IMAGING PERFORMED BY**

Saum Hadi

**HOSPITAL NAME**

Nimbus PH

**REFERRING VET**

Saum Hadi

**INVOICE**

13591

**DATE**

7.6.23



**PATIENT**

Flame Collins

**SPECIES**

Feline

**BREED**

DSH

**SEX**

Neutered Male

**AGE**

11 years

**WEIGHT**

10.3 lbs

**INTERPRETED BY**

Remo Lobetti, BVSc,  
MMedVet (Med), PhD,  
Dipl. ECVIM

**IMAGING PERFORMED BY**

Saum Hadi

**HOSPITAL NAME**

Nimbus PH

**REFERRING VET**

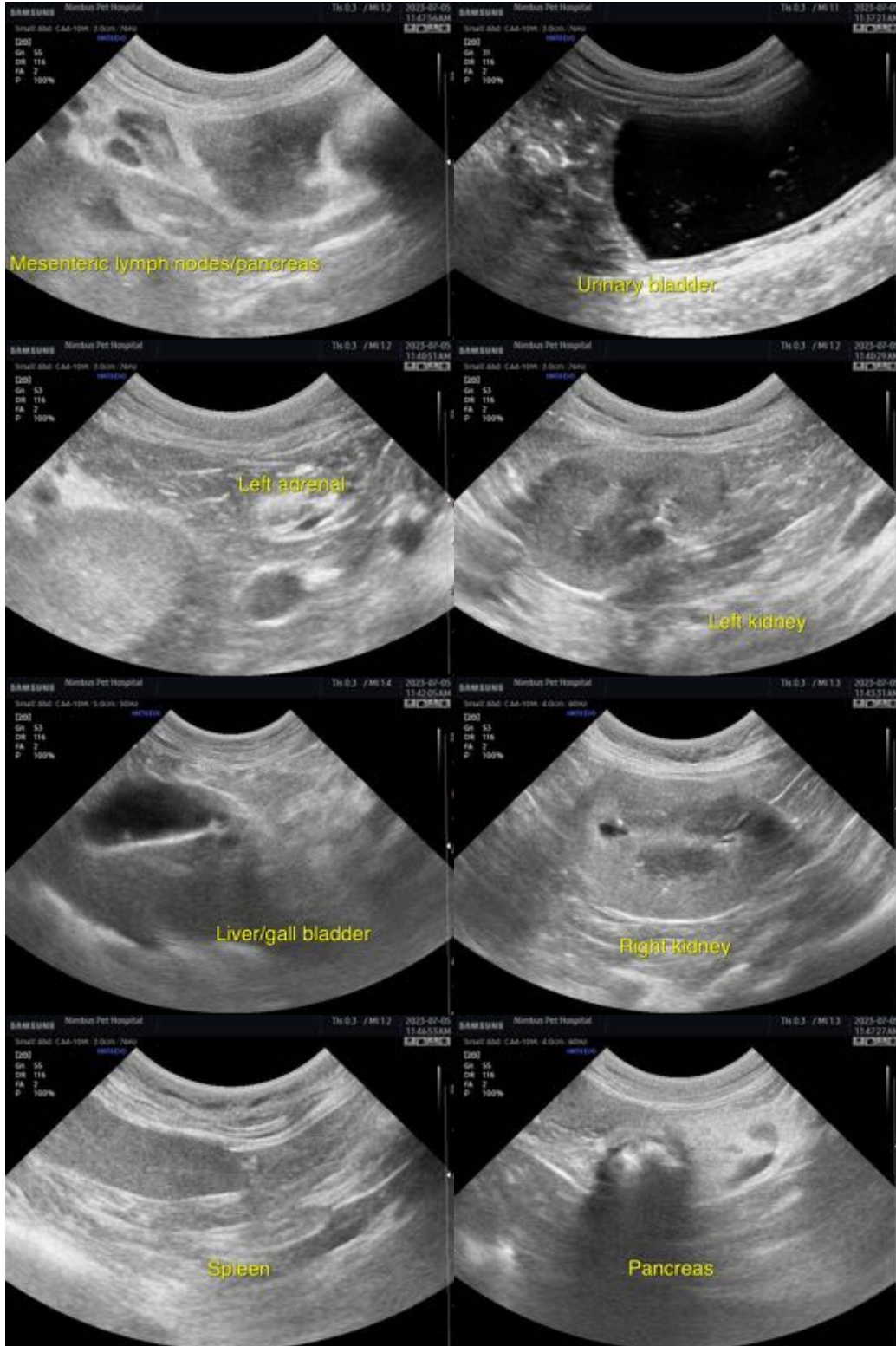
Saum Hadi

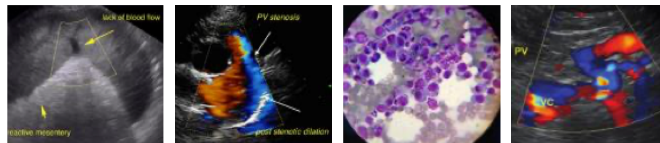
**INVOICE**

13591

**DATE**

7.6.23





**PATIENT**

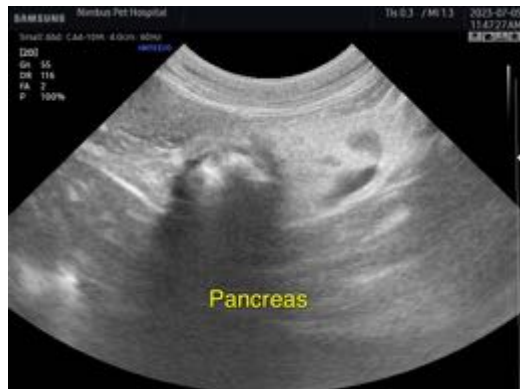Flame Collins

**SPECIES**

Feline

**BREED**

DSH



**SEX**

Neutered Male

The information and recommendations provided are based on the images presented by the referring veterinarian. No evaluation can be communicated regarding pathology that was not visible in the image/video clips provided.

**AGE**

11 years

Thank you for this referral. If the clinical or image interpretation does not parallel your findings or if I can be of any further assistance, please contact me.

**Remo Lobetti, BVSc, MMedVet (Med), PhD, Dipl. ECVIM (Internal Medicine)**  
[info@sonopath.com](mailto:info@sonopath.com)

**WEIGHT**

10.3 lbs

**INTERPRETED BY**

Remo Lobetti, BVSc,  
MMedVet (Med), PhD,  
Dipl. ECVIM

**IMAGING PERFORMED BY**

Saum Hadi

**HOSPITAL NAME**

Nimbus PH

**REFERRING VET**

Saum Hadi

**INVOICE**

13591

**DATE**

7.6.23