



PATIENT PRESENTING CLINICAL SIGNS

Summer Jalone History: Chronic intermittent vomiting, about 3 times per month. Also, chronic anal sacculitis. On hydrolyzed diet for 2 years.

SPECIES

Feline

Abnormal PE/Chem/CBC/UA Results: CBC/CHEM/UA Within Normal Limits

BREED

DSH

Urinary System

The urinary bladder is small, with a normal thickness and smooth appearance of the wall. Small amount of floating hyperechogenic sediment present. No uroliths evident.

SEX

Spayed Female

Normal appearance of the trigone area, proximal urethra, and iliac blood vessels.

AGE

4 years

Normal appearance and size of the iliac lymph nodes. Ureters not visualized, which can be considered a normal finding.

WEIGHT

14.4 lbs

Normal renal size (left kidney 3.30 cm / right kidney 3.40 cm), architecture, echogenic appearance, cortico-medullary differentiation, which maintains a 1:3 cortex to medulla ratio, pelvis, and capsule. No infarcts, mineralization or renoliths evident.

INTERPRETED BY

Remo Lobetti, BVSc, MMedVet (Med), PhD, Dipl. ECVIM

Adrenal Glands

Normal shape, echogenic appearance, size (left 0.97 cm in length x 0.25 cm in width), position, and appearance of the visible peri-renal vasculature.

IMAGING PERFORMED BY

Rachel Wiley, DVM

Spleen

Normal size (1.00 cm) and echogenic appearance. Smooth homogenous parenchyma and regular curvilinear capsule. Normal volume of the splenic vasculature without any overt congestion or thrombosis evident. No inflammatory, neoplastic, infarction, or infiltrative changes evident.

HOSPITAL NAME

Petvacx AH

Liver

Normal size, echogenic appearance, portal markings, and regular curvilinear capsule. No nodules or masses evident. Normal appearance of the hepatic and portal vasculature.

REFERRING VET

Rachel Wiley, DVM

Gallbladder

The gallbladder is small, containing normal anechoic bile. Normal thickness and echogenic appearance of the wall. Normal size and appearance of the cystic and common bile duct.

INVOICE

13656

Gastrointestinal

Normal appearance of the stomach, duodenum, small intestine, ileo-cecal junction, and colon with no loss of layering, 1:3 muscularis to mucosa ratio, normal wall thickness and peristaltic activity, and no distension of the lumen.

DATE

7.13.23

Pancreas

Normal size and echogenic appearance. Regular capsule. Normal echogenic appearance of the mesentery and fat surrounding the pancreas.

Free Abdomen

Normal mesenteric lymph nodes.

No ascites evident.



PATIENT ULTRASONOGRAPHIC FINDINGS

Summer Jalone **Primary Findings**

SPECIES • None

Feline **Secondary Findings**

BREED • Urinary bladder sediment

DSH

SEX

INTERPRETATION OF THE FINDINGS & FURTHER RECOMMENDATIONS

Spayed Female

Normal ultrasound examination of the abdomen with no obvious etiology for the presenting clinical signs.

AGE

Although the urinary bladder sediment is most likely an incidental finding, urinalysis and possible urine culture should be considered.

4 years

With the presenting clinical signs, inflammatory bowel disease and parasitic enteritis need to be considered.

WEIGHT

14.4 lbs

INTERPRETED BY

Remo Lobetti, BVSc,
MMedVet (Med),
PhD, Dipl. ECVIM

IMAGING PERFORMED BY

Rachel Wiley, DVM

HOSPITAL NAME

Petvacx AH

REFERRING VET

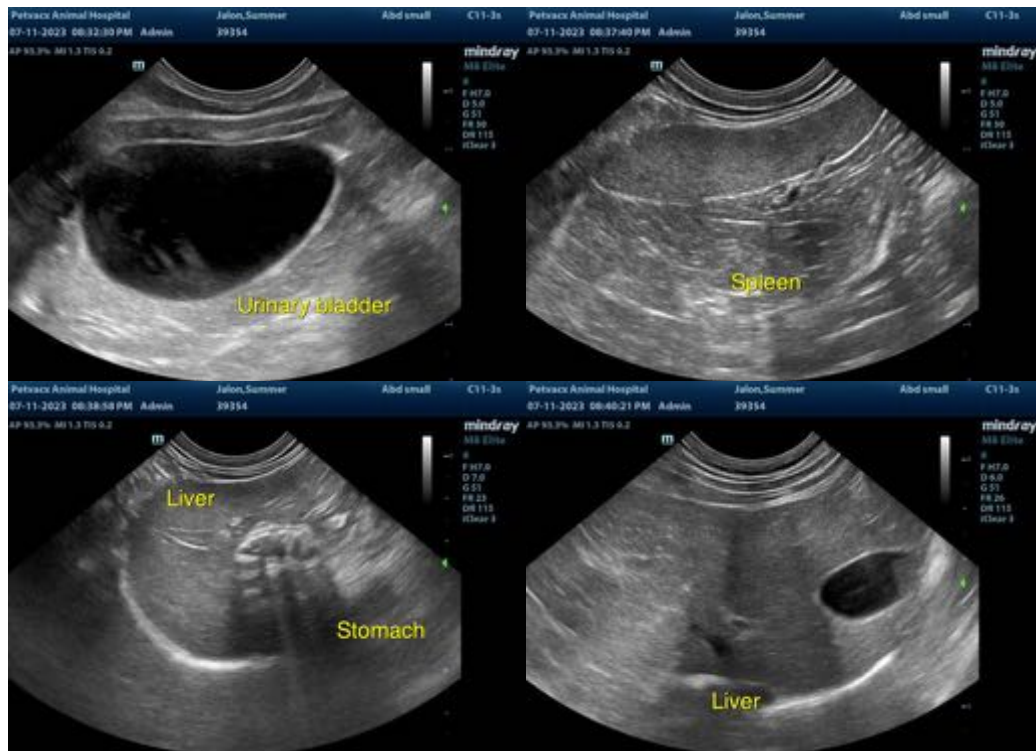
Rachel Wiley, DVM

INVOICE

13656

DATE

7.13.23



The information and recommendations provided are based on the images presented by the referring veterinarian. No evaluation can be communicated regarding pathology that was not visible in the image/video clips provided.

Thank you for this referral. If the clinical or image interpretation does not parallel your findings or if I can be of any further assistance, please contact me.

Remo Lobetti, BVSc, MMedVet (Med), PhD, Dipl. ECVIM (Internal Medicine)



PATIENT info@sonopath.com

Summer Jalone

SPECIES

Feline

BREED

DSH

SEX

Spayed Female

AGE

4 years

WEIGHT

14.4 lbs

INTERPRETED BY

Remo Lobetti, BVSc,
MMedVet (Med),
PhD, Dipl. ECVIM

**IMAGING
PERFORMED BY**

Rachel Wiley, DVM

HOSPITAL NAME

Petvacx AH

REFERRING VET

Rachel Wiley, DVM

INVOICE

13656

DATE

7.13.23