



PATIENT PRESENTING CLINICAL SIGNS

Bruce Glazer History: Presenting for MET check prior to dental procedure.

SPECIES ULTRASONOGRAPHIC EXAMINATION OF THE ABDOMEN

BREED *Urinary System*

Canine The urinary bladder is full, with a normal thickness and smooth appearance of the wall. Normal anechoic urine with no sediment or uroliths evident.

Boston Terrier Normal appearance of the trigone area, proximal urethra, and iliac blood vessels.

SEX Normal appearance and size of the iliac lymph nodes. Ureters not visualized, which can be considered a normal finding.

Neutered Male

AGE Normal renal size (left kidney 4.00 cm / right kidney 5.00 cm), architecture, echogenic appearance, cortico-medullary differentiation, which maintains a 1:3 cortex to medulla ratio, pelvis, and capsule. No infarcts, mineralization or renoliths evident.

10 years, 6 mos

WEIGHT *Reproductive System*

Small hypoechoic prostate.

18.1 lbs

INTERPRETED BY *Adrenal Glands*

Normal shape, echogenic appearance, size (left 1.44 cm in length x 0.47 cm in width) (right 1.67 cm in length x 0.51 x 0.43 cm in width), position, and appearance of the visible peri-renal vasculature.

Remo Lobetti, BVSc,
MMedVet (Med),
PhD, Dipl. ECVIM

Spleen

Normal size (1.60 cm) and echogenic appearance. Smooth homogenous parenchyma and regular curvilinear capsule. Normal volume of the splenic vasculature without any overt congestion or thrombosis evident. No inflammatory, neoplastic, infarction, or infiltrative changes evident.

IMAGING PERFORMED BY

Vivian Wang

Liver

Normal size, echogenic appearance, portal markings, and regular curvilinear capsule. No nodules or masses evident. Normal appearance of the hepatic and portal vasculature.

HOSPITAL NAME

Back Bay VC

Gallbladder

The gallbladder is full, containing normal anechoic bile. Normal thickness and echogenic appearance of the wall. Normal size and appearance of the cystic and common bile duct.

REFERRING VET

Vivian Wang

Gastrointestinal

Normal appearance of the stomach, duodenum, small intestine, ileo-cecal junction, and colon with no loss of layering, 1:3 muscularis to mucosa ratio, normal wall thickness and peristaltic activity, and no distension of the lumen. Small amount of fluid and ingesta within the stomach.

INVOICE

13645

Pancreas

Normal size and echogenic appearance. Regular capsule. Normal echogenic appearance of the mesentery and fat surrounding the pancreas.

DATE

7.11.23

Free Abdomen

Normal mesenteric lymph nodes.

No ascites evident.



PATIENT *Thorax*

Normal appearance of the heart. No pericardial or pleural effusion evident

Bruce Glazer

ULTRASONOGRAPHIC FINDINGS

SPECIES

Primary Findings

Canine

- None

BREED

Secondary Findings

Boston Terrier

- None

SEX

INTERPRETATION OF THE FINDINGS & FURTHER RECOMMENDATIONS

Neutered Male

AGE

Normal ultrasound examination of the abdomen.

10 years, 6 mos

WEIGHT

18.1 lbs

INTERPRETED BY

Remo Lobetti, BVSc,
MMedVet (Med),
PhD, Dipl. ECVIM

IMAGING PERFORMED BY

Vivian Wang

HOSPITAL NAME

Back Bay VC

REFERRING VET

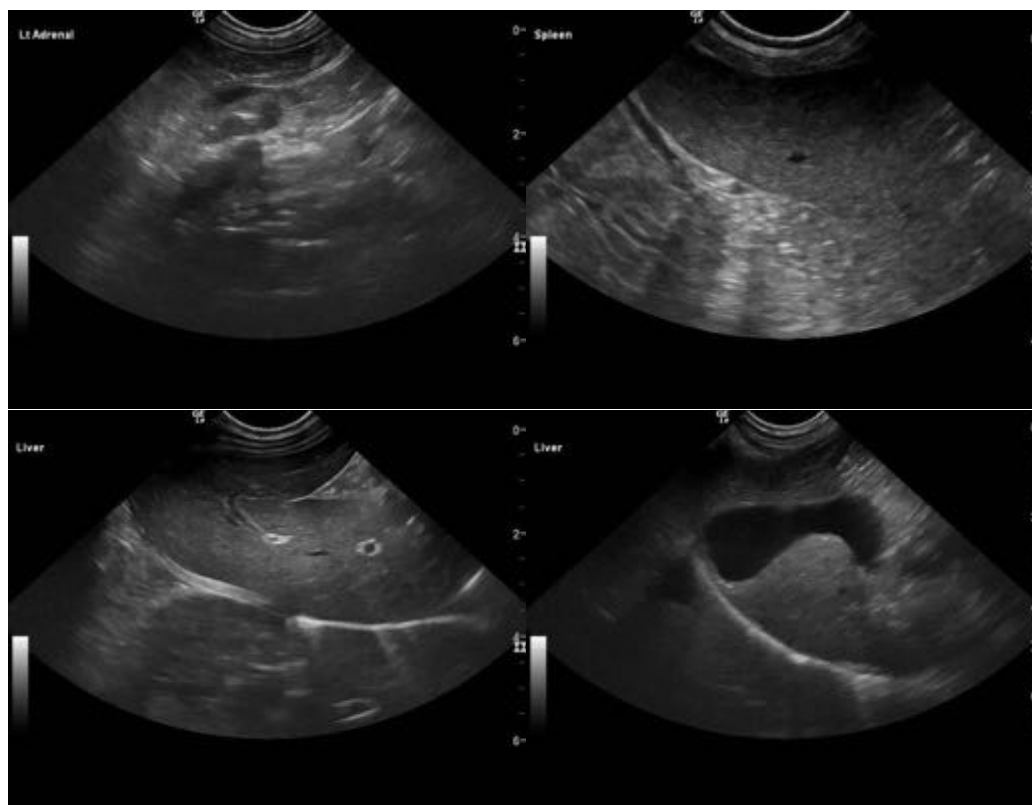
Vivian Wang

INVOICE

13645

DATE

7.11.23





PATIENT

Bruce Glazer

SPECIES

Canine

BREED

Boston Terrier

SEX

Neutered Male

AGE

10 years, 6 mos

WEIGHT

18.1 lbs

INTERPRETED BY

Remo Lobetti, BVSc,
MMedVet (Med),
PhD, Dipl. ECVIM

**IMAGING
PERFORMED BY**

Vivian Wang

HOSPITAL NAME

Back Bay VC

REFERRING VET

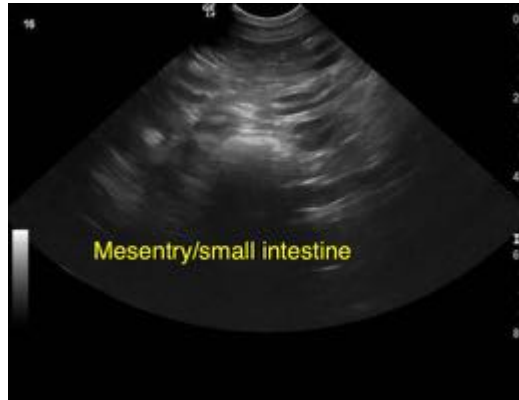Vivian Wang

INVOICE

13645

DATE

7.11.23



The information and recommendations provided are based on the images presented by the referring veterinarian. No evaluation can be communicated regarding pathology that was not visible in the image/video clips provided.

Thank you for this referral. If the clinical or image interpretation does not parallel your findings or if I can be of any further assistance, please contact me.

Remo Lobetti, BVSc, MMedVet (Med), PhD, Dipl. ECVIM (Internal Medicine)
info@sonopath.com