



PATIENT

Pumpkin Mauk

SPECIES

Feline

BREED

Domestic Longhair

SEX

Neutered male

AGE

6 years

WEIGHT

10.2 lbs

INTERPRETED BY

Remo Lobetti, BVSc,
MMedVet (Med),
PhD, Dipl. ECVIM

IMAGING PERFORMED BY

M Santiago

HOSPITAL NAME

Alison AH

REFERRING VET

Dr. Vinitsky

INVOICE

78448

DATE

6/8/26

PRESENTING CLINICAL SIGNS

History: Pt presented to ER facility on 5/10/26 for vomiting undigested food. Pt will vomit approx 10-15 mins after eating. Symptoms began approx 3 months ago. Normal appetite. Normal stool. Normal CBC/Chem. Pt has HCM and grade III/VI murmur diagnosed 2 years ago. Emergency facility could not rule out a mass in the cranial abdomen.

ULTRASONOGRAPHIC EXAMINATION OF THE ABDOMEN

Urinary System

The urinary bladder is full with a normal thickness and smooth appearance of the wall. A scant amount of floating, hyperechogenic sediment is noted.

Normal appearance of the trigone area, proximal urethra, and iliac blood vessels.

Normal appearance and size of the iliac lymph nodes. Ureters not visualized, which can be considered a normal finding.

Normal renal size (left measured 3.8 cm, right measured 3.4 cm), architecture, echogenic appearance, cortico-medullary differentiation, which maintains a 1:3 cortex to medulla ratio, pelvis, and capsule. No infarcts, mineralization or renoliths evident.

Adrenal Glands

The adrenal glands were not clearly visualized, but appear to be of normal shape, echogenic appearance and size.

Spleen

Normal size and echogenic appearance. Smooth homogenous parenchyma and regular curvilinear capsule. Normal volume of the splenic vasculature without any overt congestion or thrombosis evident. No inflammatory, neoplastic, infarction, or infiltrative changes evident. The spleen measured 0.6 cm in width.

Liver

Normal size, echogenic appearance, portal markings, and regular curvilinear capsule. No nodules or masses evident. Normal appearance of the hepatic and portal vasculature.

Gallbladder

The gallbladder is full containing normal anechoic bile. Normal thickness and echogenic appearance of the wall. Normal size and appearance of the cystic and common bile duct.



PATIENT

Pumpkin Mauk

SPECIES

Feline

BREED

Domestic Longhair

SEX

Neutered male

AGE

6 years

WEIGHT

10.2 lbs

INTERPRETED BY

Remo Lobetti, BVSc,
MMedVet (Med),
PhD, Dipl. ECVIM

IMAGING PERFORMED BY

M Santiago

HOSPITAL NAME

Alison AH

REFERRING VET

Dr. Vinitsky

INVOICE

78448

DATE

6/8/26

Gastrointestinal

Normal appearance of the stomach, duodenum, small intestine, ileo-cecal junction, and colon with no loss of layering, 1:3 muscularis to mucosa ratio, normal wall thickness and peristaltic activity, and no distension of the lumen. Fecal material was present in the colon.

Pancreas

The visible sections of the pancreas are of normal size and echogenic appearance with a regular capsule. Normal echogenic appearance of the mesentery and fat surrounding the pancreas.

Free Abdomen

Normal mesenteric lymph nodes.

No ascites evident.

ULTRASONOGRAPHIC FINDINGS

- Normal ultrasound examination of the abdomen.

INTERPRETATION OF THE FINDINGS & FURTHER RECOMMENDATIONS

On this ultrasound there is no obvious etiology for the presenting clinical signs.

Although the GI tract appears ultrasonographically normal, with the presenting clinical signs, an underlying gastroenteropathy such as chronic gastritis, Helicobacter gastritis, parasitic gastroenteritis, dietary hypersensitivity and inflammatory bowel disease should still be considered.

Further assessment would be fecal analysis, cobalamin and folate assay and endoscopy of the upper GI tract with biopsies.

Specific therapy would be dependent on an etiological diagnosis.

Symptomatic management that can be considered would be feeding small, frequent meals of a novel protein/hypoallergenic diet, course of Fenbendazole, cobalamin supplementation and if there is still not a satisfactory improvement then triple therapy for Helicobacter gastritis and if there is still not a satisfactory improvement then a course of Prednisolone would then be indicated.



PATIENT

Pumpkin Mauk

SPECIES

Feline

BREED

Domestic Longhair

SEX

Neutered male

AGE

6 years

WEIGHT

10.2 lbs

INTERPRETED BY

Remo Lobetti, BVSc,
MMedVet (Med),
PhD, Dipl. ECVIM

IMAGING PERFORMED BY

M Santiago

HOSPITAL NAME

Alison AH

REFERRING VET

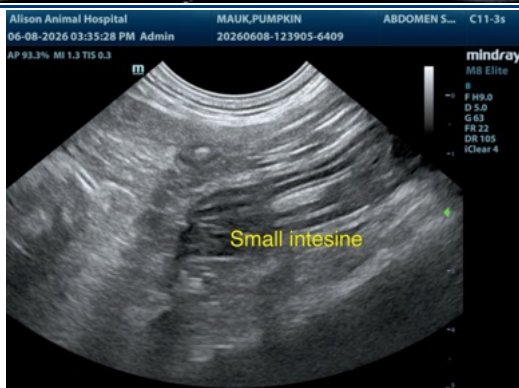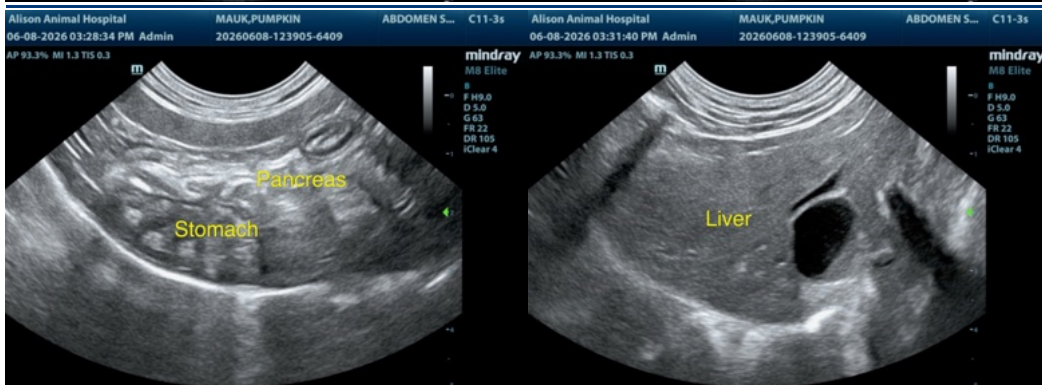
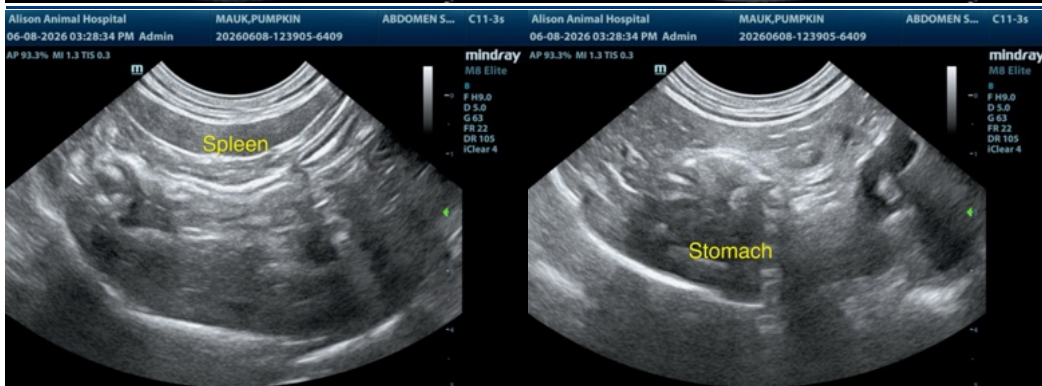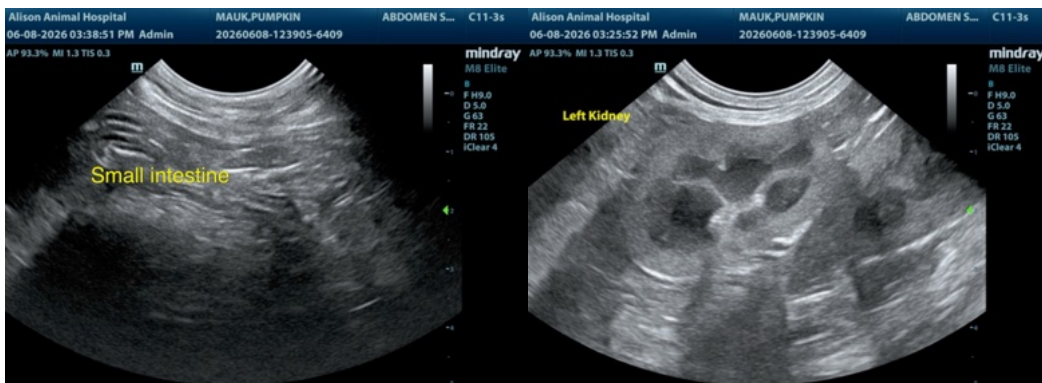Dr. Vinitsky

INVOICE

78448

DATE

6/8/26





PATIENT

Pumpkin Mauk

SPECIES

Feline

BREED

Domestic Longhair

SEX

Neutered male

AGE

6 years

WEIGHT

10.2 lbs

INTERPRETED BY

Remo Lobetti, BVSc,
MMedVet (Med),
PhD, Dipl. ECVIM

IMAGING PERFORMED BY

M Santiago

HOSPITAL NAME

Alison AH

REFERRING VET

Dr. Vinitsky

INVOICE

78448

DATE

6/8/26

The information and recommendations provided are based on the images presented by the referring veterinarian/sonographer. No evaluation can be communicated regarding pathology that was not visible in the image/video clips provided.

Thank you for this referral. If the clinical or image interpretation does not parallel your findings or if I can be of any further assistance please contact me.

Remo Lobetti, BVSc, MMedVet (Med), PhD, Dipl. ECVIM (Internal Medicine)

info@sonopath.com