



## PATIENT

Ottis Perez

## SPECIES

Canine

## BREED

Basset Hound

## SEX

Intact male

## AGE

10 months

## WEIGHT

45 lbs

## INTERPRETED BY

Remo Lobetti, BVSc,  
MMedVet (Med),  
PhD, Dipl. ECVIM

## IMAGING PERFORMED BY

Dr. Nicole Carney

## HOSPITAL NAME

Smithfield AH

## REFERRING VET

Dr. Boe

## INVOICE

78401

## DATE

6/826

## PRESENTING CLINICAL SIGNS

History: Vomiting and Diarrhea, Melena  
Abnormal PE/Chem/CBC/UA Results: Rads - Concern for small intestinal FB, subcutaneous gas appreciated Concern for FB w/ perf?

## ULTRASONOGRAPHIC EXAMINATION OF THE ABDOMEN

### *Urinary System*

The urinary bladder is small with a normal thickness and smooth appearance of the wall. Normal anechoic urine with no sediment or uroliths evident.

Normal appearance of the trigone area, proximal urethra, and iliac blood vessels.

Normal appearance and size of the iliac lymph nodes. Ureters not visualized, which can be considered a normal finding.

Normal renal size (left measured 6.7 cm, right measured 6.5 cm), architecture, echogenic appearance, cortico-medullary differentiation, which maintains a 1:3 cortex to medulla ratio, pelvis, and capsule. No infarcts, mineralization or renoliths evident.

### *Adrenal Glands*

The adrenal glands are not clearly visualized, but appear to be of normal shape, echogenic appearance and size.

### *Spleen*

Normal size and echogenic appearance. Smooth homogenous parenchyma and regular curvilinear capsule. Normal volume of the splenic vasculature without any overt congestion or thrombosis evident. No inflammatory, neoplastic, infarction, or infiltrative changes evident. The spleen measured 1.6 cm in width.

### *Liver*

Normal size, echogenic appearance, portal markings, and regular curvilinear capsule. No nodules or masses evident. Normal appearance of the hepatic and portal vasculature.

### *Gallbladder*

The gallbladder is full containing normal anechoic bile. Normal thickness and echogenic appearance of the wall. Normal size and appearance of the cystic and common bile duct.



**PATIENT**

Ottis Perez

**SPECIES**

Canine

**BREED**

Basset Hound

**SEX**

Intact male

**AGE**

10 months

**WEIGHT**

45 lbs

**INTERPRETED BY**

Remo Lobetti, BVSc,  
MMedVet (Med),  
PhD, Dipl. ECVIM

**IMAGING PERFORMED BY**

Dr. Nicole Carney

**HOSPITAL NAME**

Smithfield AH

**REFERRING VET**

Dr. Boe

**INVOICE**

78401

**DATE**

6/826

**Gastrointestinal**

Normal appearance of the stomach, duodenum, small intestine, ileo-cecal junction, and colon with no loss of layering, 1:3 muscularis to mucosa ratio, normal wall thickness and peristaltic activity, and no distension of the lumen. Fecal material was present in the colon.

**Pancreas**

The visible sections of the pancreas are of normal size and echogenic appearance with a regular capsule. Normal echogenic appearance of the mesentery and fat surrounding the pancreas.

**Free Abdomen**

Normal mesenteric lymph nodes.

No ascites evident.

**ULTRASONOGRAPHIC FINDINGS**

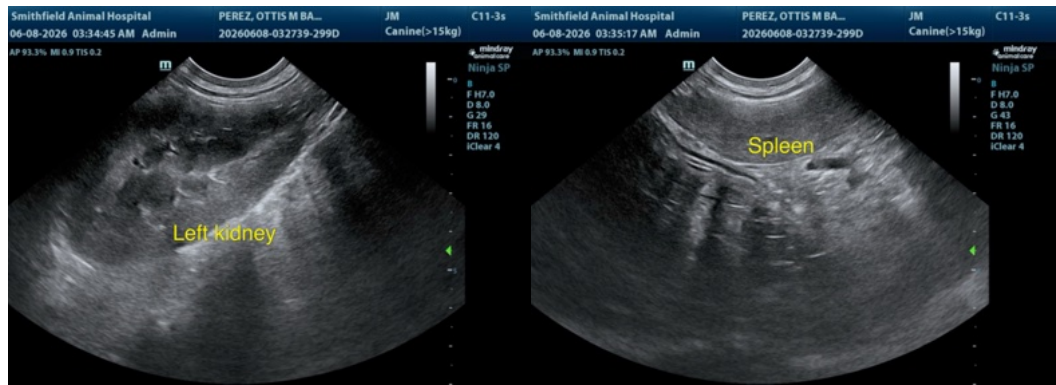
- Normal ultrasound examination of the abdomen.

**INTERPRETATION OF THE FINDINGS & FURTHER RECOMMENDATIONS**

On this ultrasound there is no obvious etiology for the presenting clinical signs.

The most likely etiology for the presenting clinical signs would be non-specific gastroenteritis such as dietary indiscretion, toxins and viral.

Initial management would be fluid therapy and correction of any electrolyte anomalies as needed, antiemetics, intestinal absorbents/protectants and feeding small frequent meals of a low fat intestinal type diet.





## PATIENT

Ottis Perez

## SPECIES

Canine

## BREED

Basset Hound

## SEX

Intact male

## AGE

10 months

## WEIGHT

45 lbs

## INTERPRETED BY

Remo Lobetti, BVSc,  
MMedVet (Med),  
PhD, Dipl. ECVIM

## IMAGING PERFORMED BY

Dr. Nicole Carney

## HOSPITAL NAME

Smithfield AH

## REFERRING VET

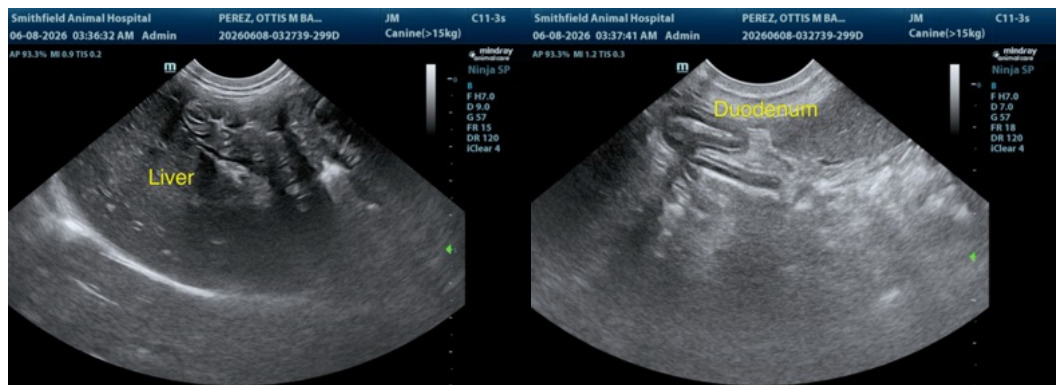
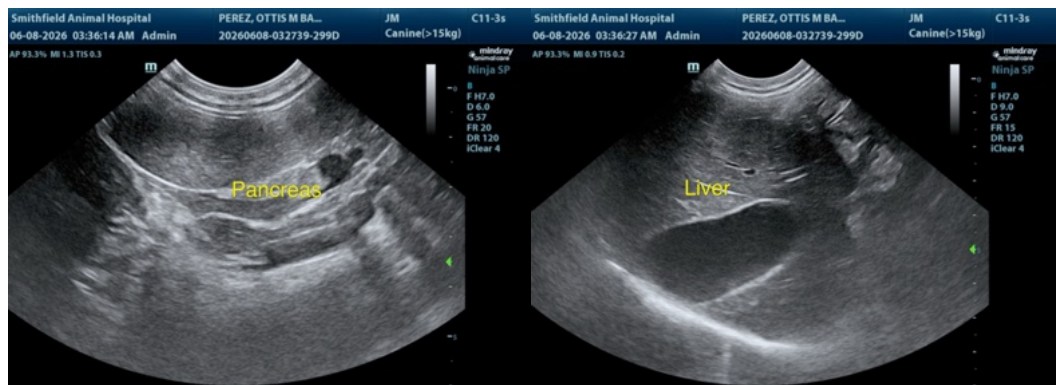
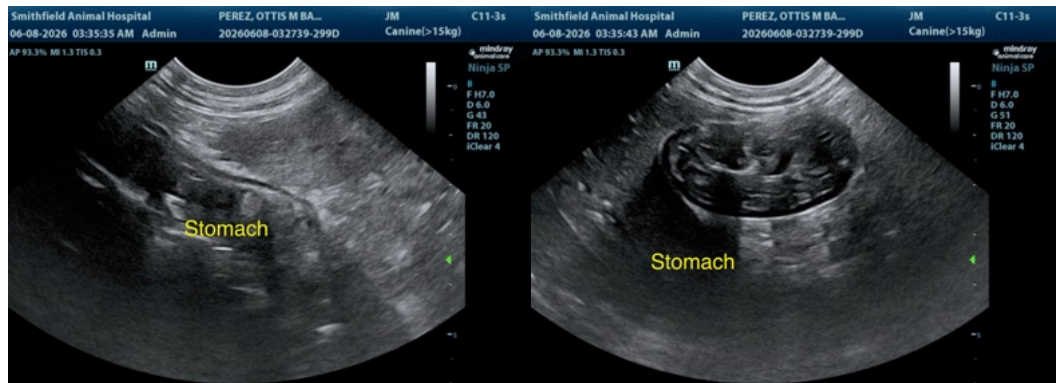
Dr. Boe

## INVOICE

78401

## DATE

6/826





## PATIENT

Ottis Perez

## SPECIES

Canine

## BREED

Basset Hound

## SEX

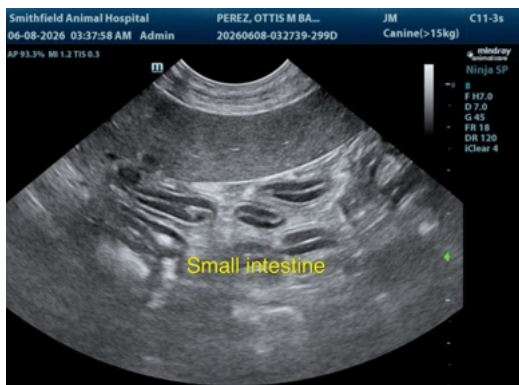Intact male

## AGE

10 months

## WEIGHT

45 lbs



The information and recommendations provided are based on the images presented by the referring veterinarian/sonographer. No evaluation can be communicated regarding pathology that was not visible in the image/video clips provided.

Thank you for this referral. If the clinical or image interpretation does not parallel your findings or if I can be of any further assistance please contact me.

Remo Lobetti, BVSc, MMedVet (Med), PhD, Dipl. ECVIM (Internal Medicine)

[info@sonopath.com](mailto:info@sonopath.com)

## INTERPRETED BY

Remo Lobetti, BVSc,  
MMedVet (Med),  
PhD, Dipl. ECVIM

## IMAGING PERFORMED BY

Dr. Nicole Carney

## HOSPITAL NAME

Smithfield AH

## REFERRING VET

Dr. Boe

## INVOICE

78401

## DATE

6/826