



## PATIENT

Brego Gomer

## SPECIES

Canine

## BREED

Bernese Mountain Dog

## SEX

Neutered male

## AGE

2 years

## WEIGHT

101.2 lbs

## INTERPRETED BY

Remo Lobetti, BVSc,  
MMedVet (Med),  
PhD, Dipl. ECVIM

## IMAGING PERFORMED BY

Allison Gomer

## HOSPITAL NAME

Shohola VH

## REFERRING VET

Dr. Demeo

## INVOICE

78451

## DATE

6/8/26

## PRESENTING CLINICAL SIGNS

**History:** Recently adopted. Patient is having episodes of gulping, retching, obsessive licking, and vomiting. The episode has happened twice, and each lasts for up to 12 hours. There has been no change in diet. The signs were non-responsive to Metoclopramide. Both times, the episodes occurred roughly 7 to 9 days after the administration of NexGard Plus.

Differentials include a gastric/GI problem versus a neurological problem.

**Abnormal PE/Chem/CBC/UA Results:** Patient's general labs are within normal limits.

## ULTRASONOGRAPHIC EXAMINATION OF THE ABDOMEN

### *Urinary System*

The urinary bladder is full with a normal thickness and smooth appearance of the wall. Normal anechoic urine with no sediment or uroliths evident.

Normal appearance of the trigone area, proximal urethra, and iliac blood vessels.

Normal appearance and size of the iliac lymph nodes. Ureters not visualized, which can be considered a normal finding.

Normal renal size (left measured 6.7 cm, right measured 6.9 cm), architecture, echogenic appearance, cortico-medullary differentiation, which maintains a 1:3 cortex to medulla ratio, pelvis, and capsule. No infarcts, mineralization or renoliths evident.

The prostate is small and hypoechogenic measuring 1.1 cm in width.

### *Adrenal Glands*

The left adrenal gland is normal in shape, echogenic appearance, size, position, and appearance of the visible peri-adrenal vasculature. Left adrenal gland measured 0.72 cm in width. The right adrenal gland was not visualized.

### *Spleen*

Normal size and echogenic appearance. Smooth homogenous parenchyma and regular curvilinear capsule. Normal volume of the splenic vasculature without any overt congestion or thrombosis evident. No inflammatory, neoplastic, infarction, or infiltrative changes evident. The spleen measured 1.7 cm in width.

### *Liver*

Normal size, echogenic appearance, portal markings, and regular curvilinear capsule. No nodules or masses evident. Normal appearance of the hepatic and portal vasculature.



## PATIENT

Brego Gomer

## SPECIES

Canine

## BREED

Bernese Mountain Dog

## SEX

Neutered male

## AGE

2 years

## WEIGHT

101.2 lbs

## INTERPRETED BY

Remo Lobetti, BVSc,  
MMedVet (Med),  
PhD, Dipl. ECVIM

## IMAGING PERFORMED BY

Allison Gomer

## HOSPITAL NAME

Shohola VH

## REFERRING VET

Dr. Demeo

## INVOICE

78451

## DATE

6/8/26

## Gallbladder

The gallbladder is full containing normal anechoic bile. Normal thickness and echogenic appearance of the wall. Normal size and appearance of the cystic and common bile duct.

## Gastrointestinal

Normal appearance of the stomach, duodenum, small intestine, ileo-cecal junction, and colon with no loss of layering, 1:3 muscularis to mucosa ratio, normal wall thickness and peristaltic activity, and no distension of the lumen.

## Pancreas

The visible sections of the pancreas are of normal size and echogenic appearance with a regular capsule. Normal echogenic appearance of the mesentery and fat surrounding the pancreas.

## Free Abdomen

Normal mesenteric lymph nodes.

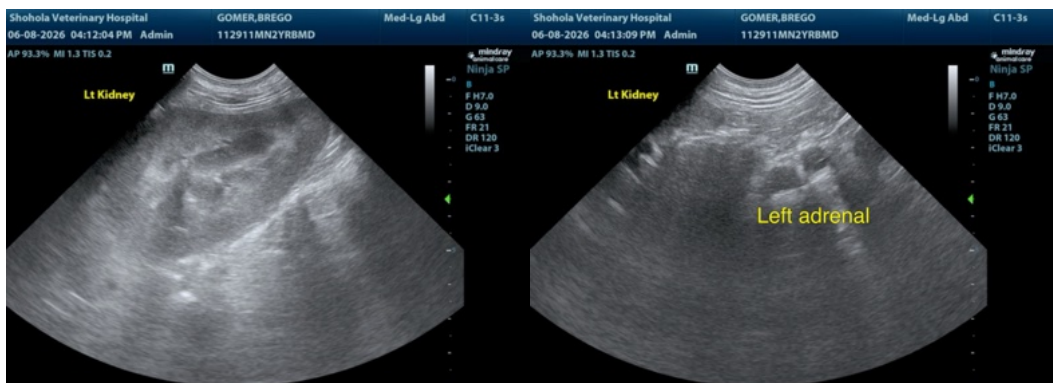
No ascites evident.

## ULTRASONOGRAPHIC FINDINGS

- Normal ultrasound examination of the abdomen.

## INTERPRETATION OF THE FINDINGS & FURTHER RECOMMENDATIONS

No specific therapy is recommended at this time.





**PATIENT**

Brego Gomer

**SPECIES**

Canine

**BREED**

Bernese Mountain Dog

**SEX**

Neutered male

**AGE**

2 years

**WEIGHT**

101.2 lbs

**INTERPRETED BY**

Remo Lobetti, BVSc,  
MMedVet (Med),  
PhD, Dipl. ECVIM

**IMAGING PERFORMED BY**

Allison Gomer

**HOSPITAL NAME**

Shohola VH

**REFERRING VET**

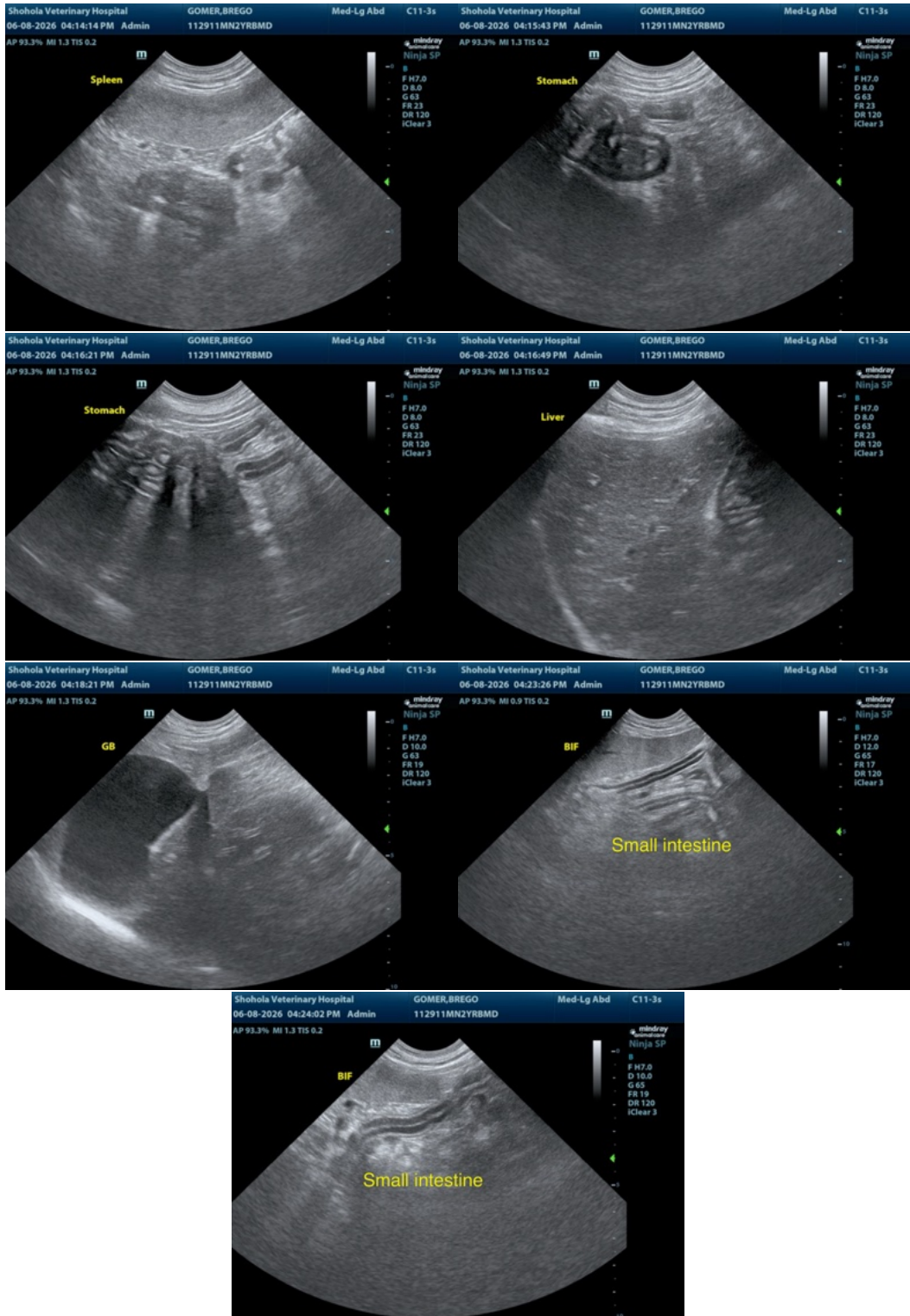
Dr. Demeo

**INVOICE**

78451

**DATE**

6/8/26





## PATIENT

Brego Gomer

## SPECIES

Canine

## BREED

Bernese Mountain Dog

## SEX

Neutered male

## AGE

2 years

## WEIGHT

101.2 lbs

## INTERPRETED BY

Remo Lobetti, BVSc,  
MMedVet (Med),  
PhD, Dipl. ECVIM

## IMAGING PERFORMED BY

Allison Gomer

## HOSPITAL NAME

Shohola VH

## REFERRING VET

Dr. Demeo

## INVOICE

78451

## DATE

6/8/26

The information and recommendations provided are based on the images presented by the referring veterinarian/sonographer. No evaluation can be communicated regarding pathology that was not visible in the image/video clips provided.

Thank you for this referral. If the clinical or image interpretation does not parallel your findings or if I can be of any further assistance please contact me.

Remo Lobetti, BVSc, MMedVet (Med), PhD, Dipl. ECVIM (Internal Medicine)

[info@sonopath.com](mailto:info@sonopath.com)