



**PATIENT**

Riley Breon

**SPECIES**

Canine

**BREED**

Shepherd Mix

**SEX**

Intact Male

**AGE**

6 years

**WEIGHT**

70 lbs

**INTERPRETED BY**

Remo Lobetti, BVSc,  
MMedVet (Med),  
PhD, Dipl. ECVIM

**IMAGING  
PERFORMED BY**

Sara Hansen

**HOSPITAL NAME**

VCA Salem AH

**REFERRING VET**

VCA Salem

**INVOICE**

13555

**DATE**

6.30.23

**PRESENTING CLINICAL SIGNS**

History: Chronic GI signs for the past year.

**ULTRASONOGRAPHIC EXAMINATION OF THE ABDOMEN**

**Urinary System**

The urinary bladder is full, with a normal thickness and smooth appearance of the wall. Normal anechoic urine with no sediment or uroliths evident.

Normal appearance of the trigone area, proximal urethra, and iliac blood vessels.

Normal appearance and size of the iliac lymph nodes. Ureters not visualized, which can be considered a normal finding.

Normal renal size (left kidney 7.00 cm) (right kidney 6.50 cm), architecture, echogenic appearance, cortico-medullary differentiation, which maintains a 1:3 cortex to medulla ratio, pelvis, and capsule. No infarcts, mineralization or renoliths evident.

**Reproductive System**

Normal appearance and size of the testes and prostate.

**Adrenal Glands**

Normal shape, echogenic appearance, size (left 2.62 cm in length x 0.54 x 0.42 cm) (right 2.84 cm in length x 0.89 cm), position, and appearance of the visible peri-renal vasculature.

**Spleen**

Normal size (1.70 cm) and echogenic appearance. Smooth homogenous parenchyma and regular curvilinear capsule. Normal volume of the splenic vasculature without any overt congestion or thrombosis evident. No inflammatory, neoplastic, infarction, or infiltrative changes evident.

**Liver**

Normal size, echogenic appearance, portal markings, and regular curvilinear capsule. No nodules or masses evident. Normal appearance of the hepatic and portal vasculature.

**Gallbladder**

The gallbladder is full, containing normal anechoic bile. Normal thickness and echogenic appearance of the wall. Normal size and appearance of the cystic and common bile duct.

**Gastrointestinal**

Normal appearance of the stomach, duodenum, small intestine, ileo-cecal junction, and colon with no loss of layering, 1:3 muscularis to mucosa ratio, normal wall thickness and peristaltic activity, and no distension of the lumen.

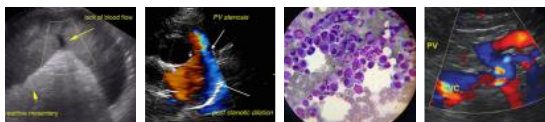
**Pancreas**

Normal size and echogenic appearance. Regular capsule. Normal echogenic appearance of the mesentery and fat surrounding the pancreas.

**Free Abdomen**

Normal mesenteric lymph nodes.

No ascites evident.



**PATIENT**

Riley Breon

**SPECIES**

Canine

**BREED**

Shepherd Mix

**SEX**

Intact Male

**AGE**

6 years

**WEIGHT**

70 lbs

**INTERPRETED BY**

Remo Lobetti, BVSc,  
 MMedVet (Med),  
 PhD, Dipl. ECVIM

**IMAGING PERFORMED BY**

Sara Hansen

**HOSPITAL NAME**

VCA Salem AH

**REFERRING VET**

VCA Salem

**INVOICE**

13555

**DATE**

6.30.23

**ULTRASONOGRAPHIC FINDINGS**

**Primary Findings**

- None

**Secondary Findings**

- None

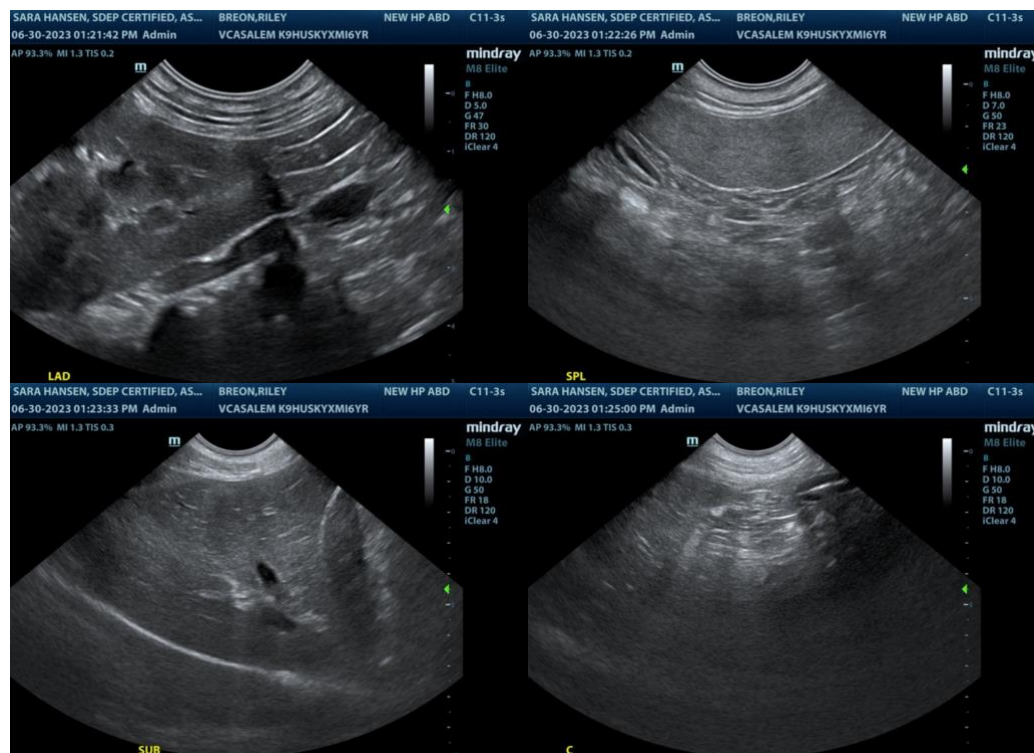
**INTERPRETATION OF THE FINDINGS & FURTHER RECOMMENDATIONS**

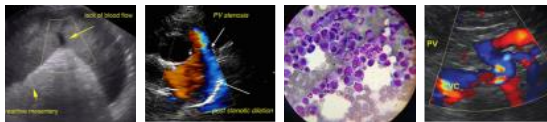
Normal ultrasound examination of the abdomen with no obvious etiology for the presenting clinical signs.

With the chronic GIT signs, etiologies to consider would be inflammatory bowel disease, dietary hypersensitivity, parasitic enteritis and exocrine pancreatic insufficiency.

Further assessment would be fecal analysis, cobalamin assay, TLI assay and endoscopy of the upper GI tract with biopsies.

Specific therapy would be dependent on an etiological diagnosis.





**PATIENT**

Riley Breon

The information and recommendations provided are based on the images presented by the referring veterinarian. No evaluation can be communicated regarding pathology that was not visible in the image/video clips provided.

**SPECIES**

Canine

Thank you for this referral. If the clinical or image interpretation does not parallel your findings or if I can be of any further assistance, please contact me.

**BREED**

Shepherd Mix

**Remo Lobetti, BVSc, MMedVet (Med), PhD, Dipl. ECVIM (Internal Medicine)**  
[info@sonopath.com](mailto:info@sonopath.com)

**SEX**

Intact Male

**AGE**

6 years

**WEIGHT**

70 lbs

**INTERPRETED BY**

Remo Lobetti, BVSc,  
MMedVet (Med),  
PhD, Dipl. ECVIM

**IMAGING  
PERFORMED BY**

Sara Hansen

**HOSPITAL NAME**

VCA Salem AH

**REFERRING VET**

VCA Salem

**INVOICE**

13555

**DATE**

6.30.23