



PATIENT PRESENTING CLINICAL SIGNS

Cody Salayko History: Possible bladder mass - blood in urine, sudden anxiety, started beginning of May, took a round of Clavamox 375mg - 1 capsule BID for ten days trazodone 100mg - 1 tablet and gabapentin 300mg 1 tablet - both were given to patient for sedation, but p vomited them up 15 minutes after o gave to p. had to give 0.75 torbugesic IV for very light sedation

SPECIES

Canine Abnormal PE/Chem/CBC/UA Results: u/a - rbc: 21 - 50 (hi)

BREED

ULTRASONOGRAPHIC EXAMINATION OF THE ABDOMEN

Urinary System

Labrador Retr The urinary bladder is full, with a normal thickness and smooth appearance of the wall. Large, irregular, mottled echogenic mass (3.40 x 4.10 cm) on the ventral wall of the bladder. Focal areas of mineralization present within the mass. Normal anechoic urine with no sediment or uroliths evident.

SEX

Neutered Male Normal appearance of the trigone area, proximal urethra, and iliac blood vessels.

AGE

Normal appearance and size of the iliac lymph nodes. Ureters not visualized, which can be considered a normal finding.

10 years, 9 mos Normal renal size (left 5.10 cm) (right 5.30 cm) with increased echogenic appearance, some loss of cortico-medullary differentiation, and normal pelvis, and capsule. No infarcts, mineralization or renoliths evident.

WEIGHT

Reproductive System

47.7 lbs Small hypoechogenic prostate.

Adrenal Glands

INTERPRETED BY

The left adrenal gland is poorly visualized but appears to be of normal shape, echogenic appearance, size, position. The right adrenal gland is not visualized.

Remo Lobetti, BVSc, MMedVet (Med), PhD, Dipl. ECVIM

Spleen

Normal size and echogenic appearance. Smooth homogenous parenchyma and regular curvilinear capsule. Normal volume of the splenic vasculature without any overt congestion or thrombosis evident. No inflammatory, neoplastic, infarction, or infiltrative changes evident.

IMAGING PERFORMED BY

Liver

Heather Normal size, echogenic appearance, portal markings, and regular curvilinear capsule. No nodules or masses evident. Normal appearance of the hepatic and portal vasculature.

HOSPITAL NAME

Gallbladder

Animal Care Clinic of Flanders The gallbladder is full, containing normal anechoic bile. Normal thickness and echogenic appearance of the wall. Normal size and appearance of the cystic and common bile duct.

REFERRING VET

Gastrointestinal

Dr. Villari Normal appearance of the stomach, duodenum, small intestine, ileo-cecal junction, and colon with no loss of layering, 1:3 muscularis to mucosa ratio, normal wall thickness and peristaltic activity, and no distension of the lumen.

INVOICE

Pancreas

13549 Normal size and echogenic appearance. Regular capsule. Normal echogenic appearance of the mesentery and fat surrounding the pancreas.

DATE

6.30.23



PATIENT *Free Abdomen*
Normal mesenteric lymph nodes.

Cody Salayko
No ascites evident.

SPECIES *Thorax*
Normal appearance of the heart. No pericardial or pleural effusion evident.

Canine

ULTRASONOGRAPHIC FINDINGS

BREED *Primary Findings*

Labrador Retr

- Urinary bladder mass

SEX *Secondary Findings*

Neutered Male

- Age-related renal changes

INTERPRETATION OF THE FINDINGS & FURTHER RECOMMENDATIONS

AGE
The appearance of the urinary bladder mass is consistent with neoplasia.

10 years, 9 mos
Further assessment would be urinalysis, three-view thoracic radiographs and catheter-assisted aspirates or biopsy of the mass. As the mass is away from the trigone area, surgical resection could be considered, bearing in mind, that it does appear to have an Infiltrative nature.

WEIGHT
47.7 lbs
Palliative therapy would be the use of NSAIDs.

INTERPRETED BY

Remo Lobetti, BVSc,
MMedVet (Med),
PhD, Dipl. ECVIM

IMAGING PERFORMED BY

Heather

HOSPITAL NAME

Animal Care Clinic
of Flanders

REFERRING VET

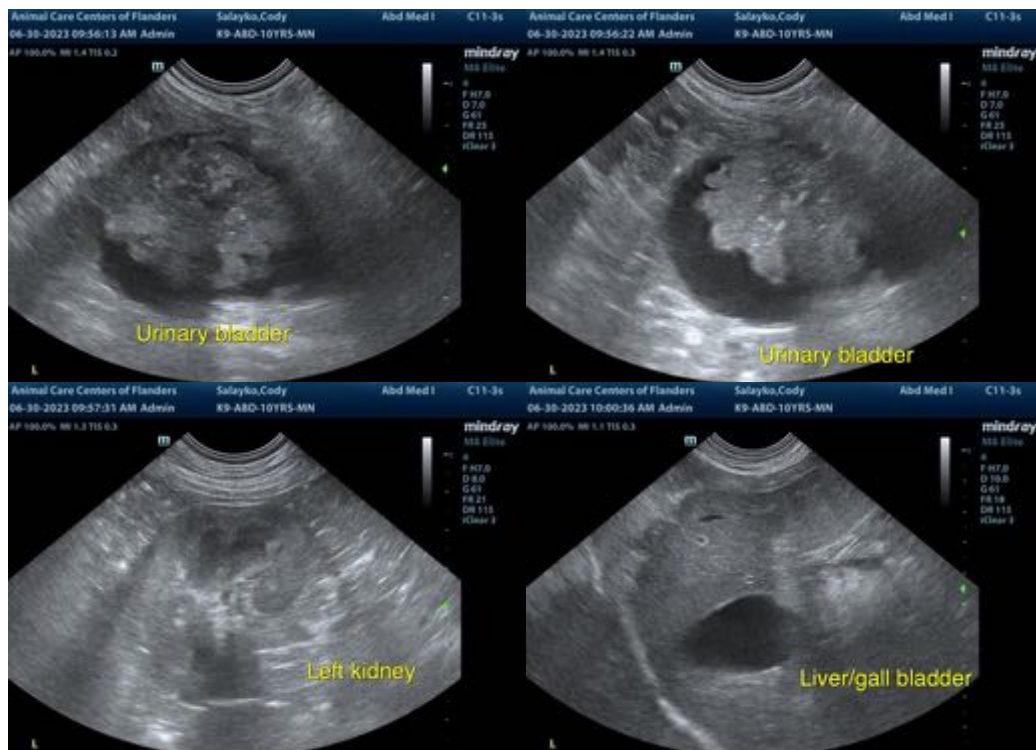
Dr. Villari

INVOICE

13549

DATE

6.30.23





PATIENT

Cody Salayko

The information and recommendations provided are based on the images presented by the referring veterinarian. No evaluation can be communicated regarding pathology that was not visible in the image/video clips provided.

SPECIES

Canine

Thank you for this referral. If the clinical or image interpretation does not parallel your findings or if I can be of any further assistance, please contact me.

Remo Lobetti, BVSc, MMedVet (Med), PhD, Dipl. ECVIM (Internal Medicine)
info@sonopath.com

BREED

Labrador Retr

SEX

Neutered Male

AGE

10 years, 9 mos

WEIGHT

47.7 lbs

INTERPRETED BY

Remo Lobetti, BVSc,
MMedVet (Med),
PhD, Dipl. ECVIM

**IMAGING
PERFORMED BY**

Heather

HOSPITAL NAME

Animal Care Clinic
of Flanders

REFERRING VET

Dr. Villari

INVOICE

13549

DATE

6.30.23