



PATIENT PRESENTING CLINICAL SIGNS

Skid Row Burdic
History: P presented 3 months ago for a chronic diarrhea. P was sent home with supportive medications (metronidazole) and P's diarrhea did not resolve per O. Due to O's schedule, they were unable to bring P in for a recheck until now. P now is having profuse diarrhea and P is also vomiting her food despite having a ravenous appetite per O. Drinking normally, No C/S per O. No current medications.

SPECIES

Feline
Abnormal PE/Chem/CBC/UA Results: PE: Perianal fecal staining, BCS 2/9, generalized muscle wasting tT4: WNL

BREED

ULTRASONOGRAPHIC EXAMINATION OF THE ABDOMEN

DLH

Urinary System

The urinary bladder is full, with a normal thickness and smooth appearance of the wall. Normal anechoic urine with no sediment or uroliths evident.

SEX

Female Spayed
Normal appearance of the trigone area, proximal urethra, and iliac blood vessels.

AGE

Normal appearance and size of the iliac lymph nodes. Ureters not visualized, which can be considered a normal finding.

14 years, 5 mos

Normal renal size (left kidney 3.40 cm) with increased echogenic appearance, some loss of cortico-medullary differentiation, and normal pelvis and capsule. No infarcts, mineralization or renoliths evident.

WEIGHT

Adrenal Glands

4.58 lbs

Normal shape, echogenic appearance, size (left 0.43 cm) (right 0.38 cm), position, and appearance of the visible peri-renal vasculature.

INTERPRETED BY

Spleen

Remo Lobetti, BVSc,
MMedVet (Med), PhD,
Dipl. ECVIM

Normal size and echogenic appearance. Smooth homogenous parenchyma and regular curvilinear capsule. Normal volume of the splenic vasculature without any overt congestion or thrombosis evident. No inflammatory, neoplastic, infarction, or infiltrative changes evident.

IMAGING PERFORMED BY

Liver

Aaron Deml, DVM

Normal size, echogenic appearance, portal markings, and regular curvilinear capsule. No nodules or masses evident. Normal appearance of the hepatic and portal vasculature.

HOSPITAL NAME

Gallbladder

Craig Road AH

The gallbladder is full, containing normal anechoic bile. Normal thickness and echogenic appearance of the wall. Normal size and appearance of the cystic and common bile duct.

REFERRING VET

Gastrointestinal

Cameron Johnson,
DVM

Ingesta within the stomach and large amount of chyme within the small intestine. Normal appearance of duodenum, small intestine, and colon with no loss of layering, 1:3 muscularis to mucosa ratio, normal wall thickness and peristaltic activity, and no distension of the lumen.

INVOICE

Pancreas

13462

Poorly visualized but appears to be of normal size and echogenic appearance, with a normal echogenic appearance of the mesentery and fat surrounding the pancreas.

DATE

Free Abdomen

6.23.23

Normal mesenteric lymph nodes.



PATIENT

Skid Row Burdic

No ascites evident.

ULTRASONOGRAPHIC FINDINGS

SPECIES

Feline

Primary Findings

- Enteropathy (?)

BREED

DLH

Secondary Findings

- Age-related renal changes

INTERPRETATION OF THE FINDINGS & FURTHER RECOMMENDATIONS

SEX

Female Spayed

Etiologies for the presenting clinical signs and possible enteropathy would be inflammatory bowel disease, parasitic enteritis, dietary hypersensitivity, and pancreatic insufficiency.

AGE

14 years, 5 mos

Further assessment would be fecal analysis, cobalamin assay, PLI assay and endoscopy of the upper GI tract with biopsies.

WEIGHT

4.58 lbs

Specific therapy would be dependent on an etiological diagnosis. Symptomatic management would be feeding a novel protein/hypoallergenic diet, cobalamin supplementation, course of Fenbendazole and possibly, prednisolone therapy.

INTERPRETED BY

Remo Lobetti, BVSc,
MMedVet (Med), PhD,
Dipl. ECVIM

IMAGING PERFORMED BY

Aaron Deml, DVM

HOSPITAL NAME

Craig Road AH

REFERRING VET

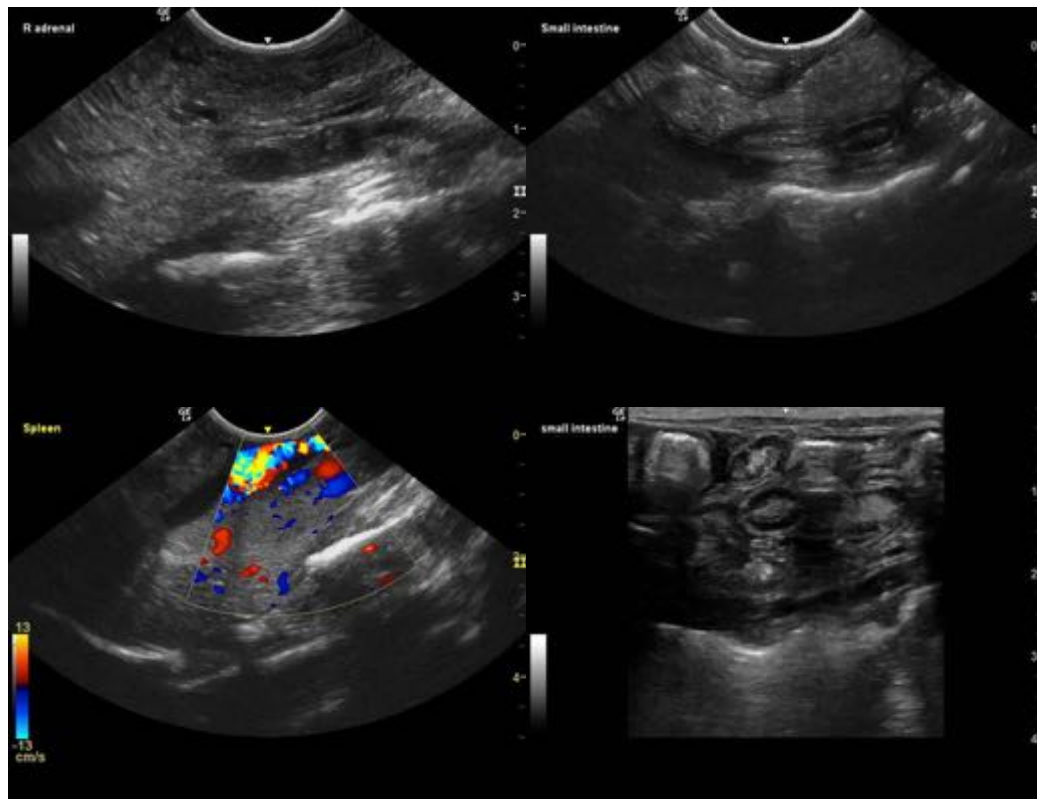
Cameron Johnson,
DVM

INVOICE

13462

DATE

6.23.23





PATIENT

Skid Row Burdic

The information and recommendations provided are based on the images presented by the referring veterinarian. No evaluation can be communicated regarding pathology that was not visible in the image/video clips provided.

SPECIES

Feline

Thank you for this referral. If the clinical or image interpretation does not parallel your findings or if I can be of any further assistance, please contact me.

Remo Lobetti, BVSc, MMedVet (Med), PhD, Dipl. ECVIM (Internal Medicine)
info@sonopath.com

BREED

DLH

SEX

Female Spayed

AGE

14 years, 5 mos

WEIGHT

4.58 lbs

INTERPRETED BY

Remo Lobetti, BVSc,
MMedVet (Med), PhD,
Dipl. ECVIM

**IMAGING
PERFORMED BY**

Aaron Deml, DVM

HOSPITAL NAME

Craig Road AH

REFERRING VET

Cameron Johnson,
DVM

INVOICE

13462

DATE

6.23.23