



PATIENT

Sammy Brown

SPECIES

Canine

BREED

Shih Mix

SEX

Neutered male

AGE

10 years

WEIGHT

14 lbs

INTERPRETED BY

Remo Lobetti, BVSc,
MMedVet (Med),
PhD, Dipl. ECVIM

IMAGING PERFORMED BY

Dr. Carney

HOSPITAL NAME

Smithfield AH

REFERRING VET

Dr. Boe

INVOICE

78280

DATE

6/2/26

PRESENTING CLINICAL SIGNS

History: Diagnosed hypothyroidism
ADR the past few days

Abnormal PE/Chem/CBC/UA Results: ALT 559 ALP 1,136 GGT 37

ULTRASONOGRAPHIC EXAMINATION OF THE ABDOMEN

Urinary System

The urinary bladder is small with a normal thickness and smooth appearance of the wall. Normal anechoic urine with no sediment or uroliths evident.

Normal appearance of the trigone area, proximal urethra, and iliac blood vessels.

Normal appearance and size of the iliac lymph nodes. Ureters not visualized, which can be considered a normal finding.

Normal renal size (left measured 4.0 cm, right measured 3.9 cm), architecture, echogenic appearance, cortico-medullary differentiation, which maintains a 1:3 cortex to medulla ratio, pelvis, and capsule. No infarcts, mineralization or renoliths evident. Small, incidental cortical cysts are present in the left kidney measuring 0.5 cm.

Small, hypoechogenic prostate measuring 0.8 cm in width.

Adrenal Glands

The left adrenal gland is normal in shape, echogenic appearance, size, position, and appearance of the visible peri-adrenal vasculature. Left adrenal gland measured 0.6 cm in width. The right adrenal gland was not visualized.

Spleen

Normal size and echogenic appearance. Smooth homogenous parenchyma and regular curvilinear capsule. Normal volume of the splenic vasculature without any overt congestion or thrombosis evident. No inflammatory, neoplastic, infarction, or infiltrative changes evident. The spleen measured 1.0 cm in width.

Liver

Normal size with a diffuse, mottled echogenic and coarse appearance, decreased portal markings and a regular curvilinear capsule. No obvious nodules or masses evident. Normal appearance of the hepatic and portal vasculature.



PATIENT

Sammy Brown

SPECIES

Canine

BREED

Shih Mix

SEX

Neutered male

AGE

10 years

WEIGHT

14 lbs

INTERPRETED BY

Remo Lobetti, BVSc,
MMedVet (Med),
PhD, Dipl. ECVIM

IMAGING PERFORMED BY

Dr. Carney

HOSPITAL NAME

Smithfield AH

REFERRING VET

Dr. Boe

INVOICE

78280

DATE

6/2/26

Gallbladder

The gallbladder is full containing normal anechoic bile. Normal thickness and echogenic appearance of the wall. Normal size and appearance of the cystic and common bile duct.

Gastrointestinal

Normal appearance of the stomach, duodenum, small intestine, ileo-cecal junction, and colon with no loss of layering, 1:3 muscularis to mucosa ratio, normal wall thickness and peristaltic activity, and no distension of the lumen. A moderate amount of ingesta is present in the stomach.

Pancreas

The visible sections of the pancreas are of normal size and echogenic appearance with a regular capsule. Normal echogenic appearance of the mesentery and fat surrounding the pancreas.

Free Abdomen

Normal mesenteric lymph nodes.

A small amount of acellular ascites is present.

ULTRASONOGRAPHIC FINDINGS

- Hepatopathy.
- Ascites.

INTERPRETATION OF THE FINDINGS & FURTHER RECOMMENDATIONS

Etiologies for the hepatopathy would be nodular hyperplasia, chronic active hepatitis, granulomatous disease and possibly infiltrative neoplasia.

The ascites is most likely secondary to the hepatopathy.

Further assessment would be FNA cytology of the liver and if possible analysis of the ascitic fluid.

A tru cut or wedge biopsy of the liver may be required for a final etiological diagnosis.

Specific therapy would be dependent on an etiological diagnosis.

Symptomatic management that can be considered would be the use of Ursodiol with regular monitoring of liver enzyme activity.



PATIENT

Sammy Brown

SPECIES

Canine

BREED

Shih Mix

SEX

Neutered male

AGE

10 years

WEIGHT

14 lbs

INTERPRETED BY

Remo Lobetti, BVSc,
MMedVet (Med),
PhD, Dipl. ECVIM

IMAGING PERFORMED BY

Dr. Carney

HOSPITAL NAME

Smithfield AH

REFERRING VET

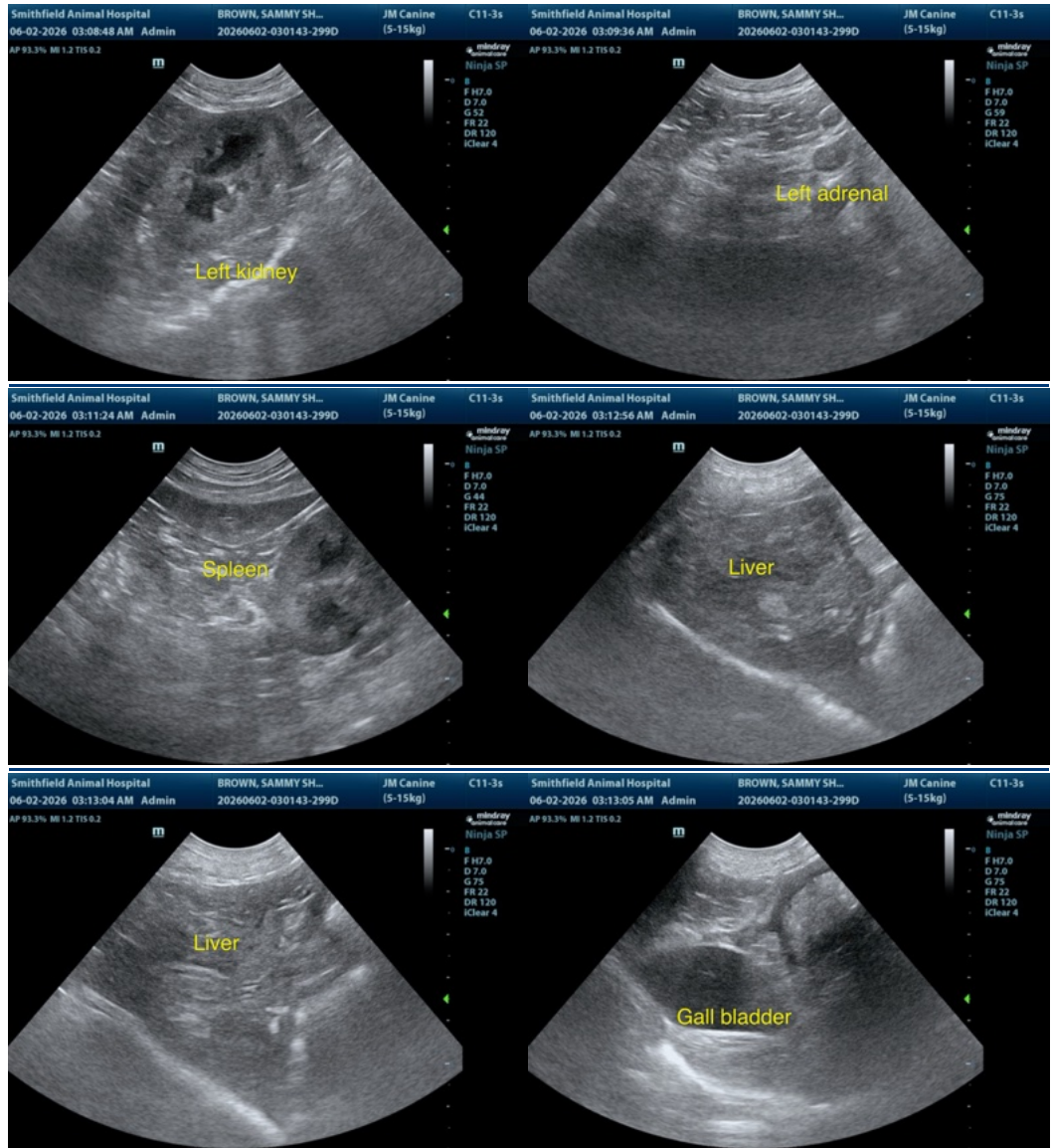
Dr. Boe

INVOICE

78280

DATE

6/2/26





PATIENT

Sammy Brown

SPECIES

Canine

BREED

Shih Mix

SEX

Neutered male

AGE

10 years

WEIGHT

14 lbs

INTERPRETED BY

Remo Lobetti, BVSc,
MMedVet (Med),
PhD, Dipl. ECVIM

IMAGING PERFORMED BY

Dr. Carney

HOSPITAL NAME

Smithfield AH

REFERRING VET

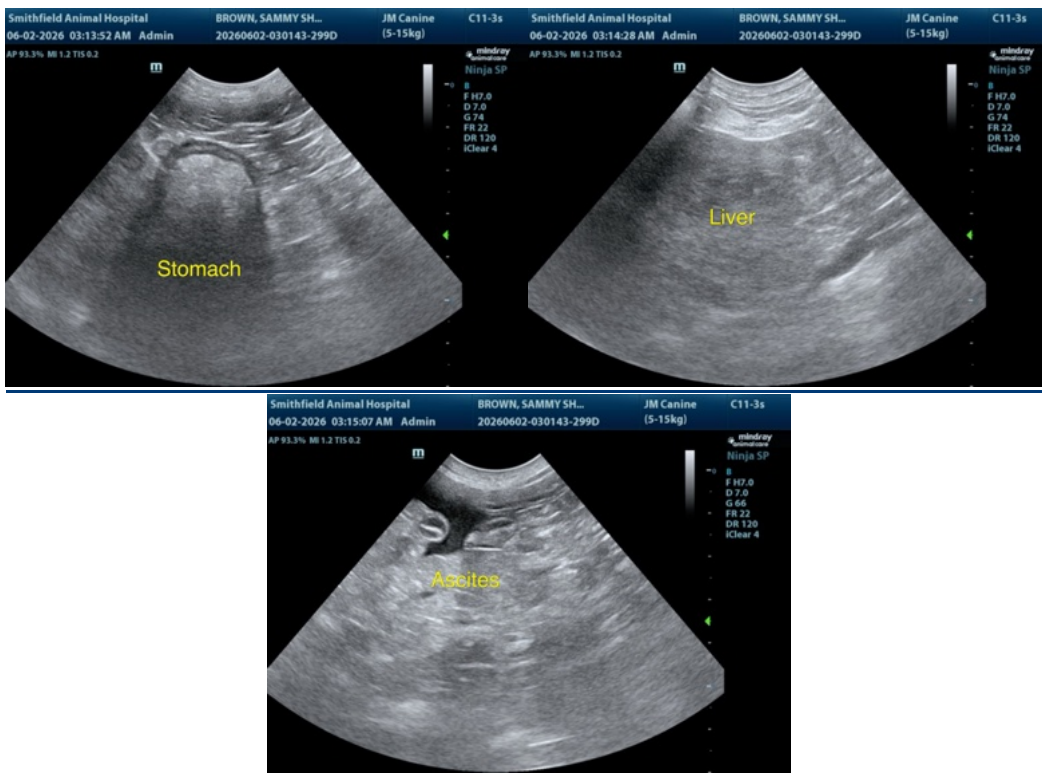
Dr. Boe

INVOICE

78280

DATE

6/2/26



The information and recommendations provided are based on the images presented by the referring veterinarian/sonographer. No evaluation can be communicated regarding pathology that was not visible in the image/video clips provided.

Thank you for this referral. If the clinical or image interpretation does not parallel your findings or if I can be of any further assistance please contact me.

Remo Lobetti, BVSc, MMedVet (Med), PhD, Dipl. ECVIM (Internal Medicine)

info@sonopath.com