



PATIENT

Elsie Rauch

SPECIES

Canine

BREED

Bichon Frise Mix

SEX

Spayed female

AGE

11 years

WEIGHT

18.6 lbs

INTERPRETED BY

Remo Lobetti, BVSc,
MMedVet (Med),
PhD, Dipl. ECVIM

IMAGING PERFORMED BY

Allison Maxey

HOSPITAL NAME

Evergreen AH

REFERRING VET

Dr. Maxey

INVOICE

78296

DATE

6/2/26

PRESENTING CLINICAL SIGNS

History: Abdominal mass effect noted by owner ~6-8 weeks ago. Has grown rapidly since first noted. No other clinical signs per owner.

Abnormal PE/Chem/CBC/UA Results: FNA cytology of abdominal mass pending.

ULTRASONOGRAPHIC EXAMINATION OF THE ABDOMEN

Urinary System

The urinary bladder is small with a normal thickness and smooth appearance of the wall. Normal anechoic urine with no sediment or uroliths evident.

Normal appearance of the trigone area and iliac blood vessels. The proximal urethra was not visualized.

Normal appearance and size of the iliac lymph nodes. Ureters not visualized, which can be considered a normal finding.

Normal renal size (left measured 5.3 cm, right measured 4.8 cm), architecture, echogenic appearance, cortico-medullary differentiation, which maintains a 1:3 cortex to medulla ratio, pelvis, and capsule. No infarcts, mineralization or renoliths evident. normal color flow pattern is evident in both kidneys.

Adrenal Glands

Normal shape, echogenic appearance, size, position, and appearance of the visible peri-adrenal vasculature. Left adrenal gland measured 0.37 cm and 0.28 cm in width. The right adrenal gland measured 0.39 cm in width.

Spleen

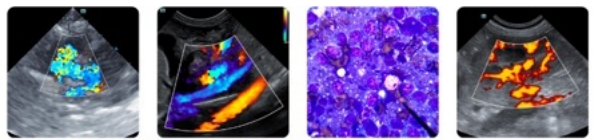
Normal size and echogenic appearance. Smooth homogenous parenchyma and regular curvilinear capsule. Normal volume of the splenic vasculature without any overt congestion or thrombosis evident. No inflammatory, neoplastic, infarction, or infiltrative changes evident. The spleen measured 1.4 cm in width.

Liver

Normal size, echogenic appearance, portal markings, and regular curvilinear capsule. No nodules or masses evident. Normal appearance of the hepatic and portal vasculature.

Gallbladder

The gallbladder is full containing normal anechoic bile. Normal thickness and echogenic appearance of the wall. Normal size and appearance of the cystic and common bile duct.



PATIENT

Elsie Rauch

SPECIES

Canine

BREED

Bichon Frise Mix

SEX

Spayed female

AGE

11 years

WEIGHT

18.6 lbs

INTERPRETED BY

Remo Lobetti, BVSc,
MMedVet (Med),
PhD, Dipl. ECVIM

IMAGING PERFORMED BY

Allison Maxey

HOSPITAL NAME

Evergreen AH

REFERRING VET

Dr. Maxey

INVOICE

78296

DATE

6/2/26

Gastrointestinal

Normal appearance of the stomach, duodenum, small intestine, ileo-cecal junction, and colon with no loss of layering, 1:3 muscularis to mucosa ratio, normal wall thickness and peristaltic activity, and no distension of the lumen.

Pancreas

The visible sections of the pancreas are of normal size and echogenic appearance with a regular capsule. Normal echogenic appearance of the mesentery and fat surrounding the pancreas.

Free Abdomen

Normal mesenteric lymph nodes.

No ascites evident.

Large, irregular, mottled echogenic cystic mass was noted in the midabdomen measuring at least 7.0 x 10.0 cm in size. Hyperechogenic appearance of the mesentery surrounding the mass. The mass is not obviously associated with any organ system.

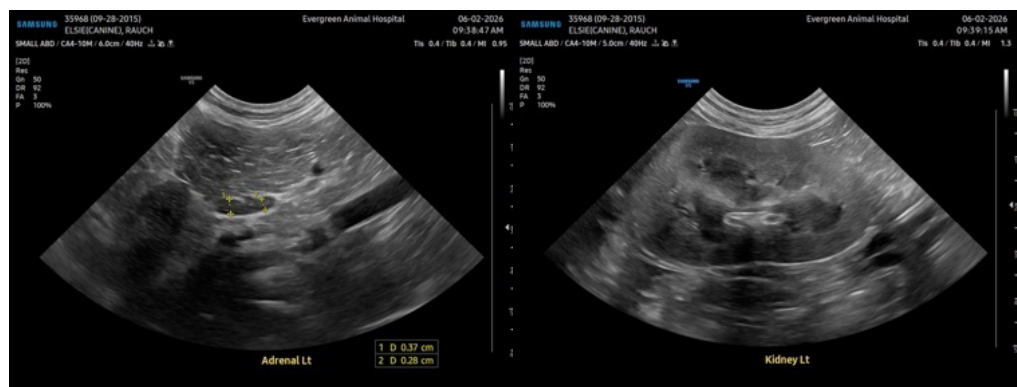
ULTRASONOGRAPHIC FINDINGS

- Abdominal mass.

INTERPRETATION OF THE FINDINGS & FURTHER RECOMMENDATIONS

The most likely etiology for the abdominal mass would be neoplasia and most likely originating from the mesentery.

Further assessment and therapy needs to be based on the pending cytology results, but could include three view thoracic radiographs and possible laparotomy as the latter could be diagnostic and therapeutic.





PATIENT

Elsie Rauch

SPECIES

Canine

BREED

Bichon Frise Mix

SEX

Spayed female

AGE

11 years

WEIGHT

18.6 lbs

INTERPRETED BY

Remo Lobetti, BVSc,
MMedVet (Med),
PhD, Dipl. ECVIM

**IMAGING
PERFORMED BY**

Allison Maxey

HOSPITAL NAME

Evergreen AH

REFERRING VET

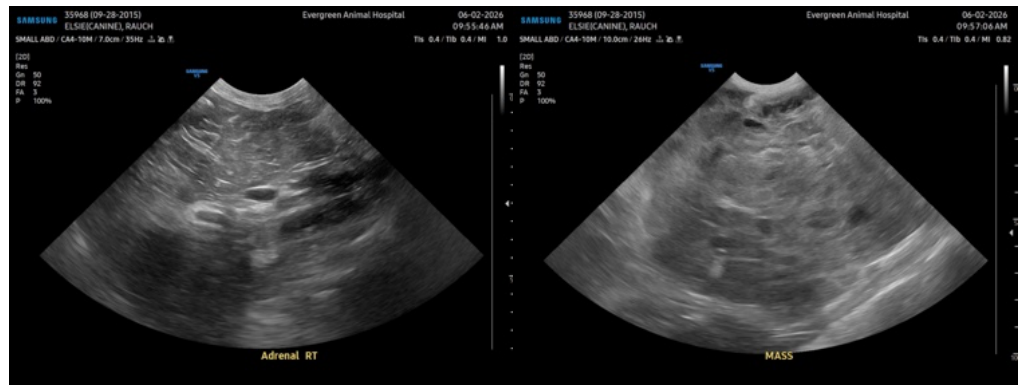
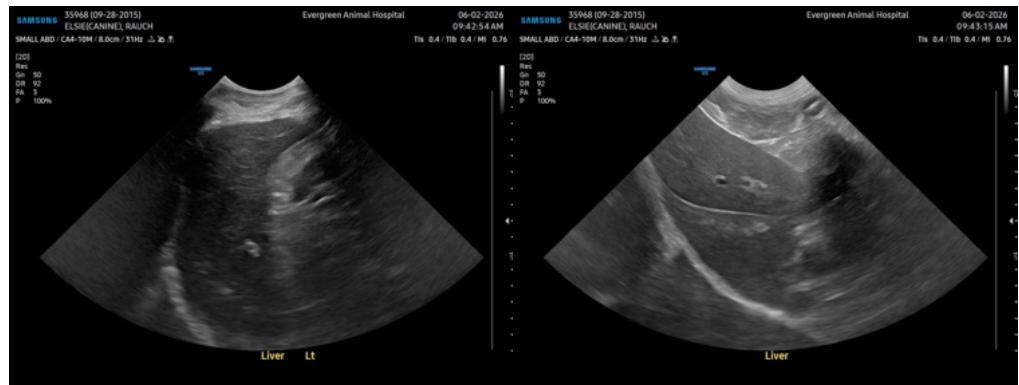
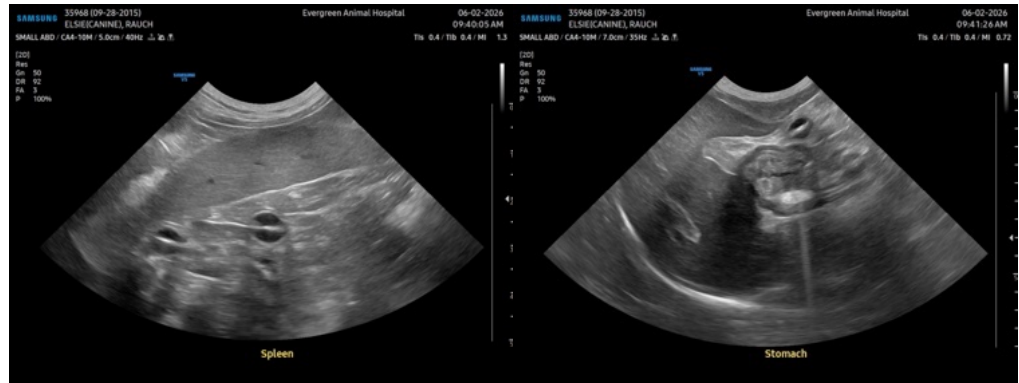
Dr. Maxey

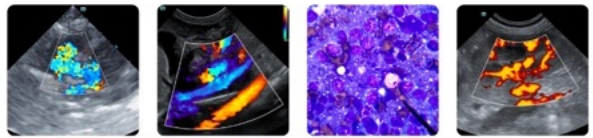
INVOICE

78296

DATE

6/2/26





PATIENT

Elsie Rauch

SPECIES

Canine

BREED

Bichon Frise Mix

SEX

Spayed female

AGE

11 years

WEIGHT

18.6 lbs

INTERPRETED BY

Remo Lobetti, BVSc,
MMedVet (Med),
PhD, Dipl. ECVIM

IMAGING PERFORMED BY

Allison Maxey

HOSPITAL NAME

Evergreen AH

REFERRING VET

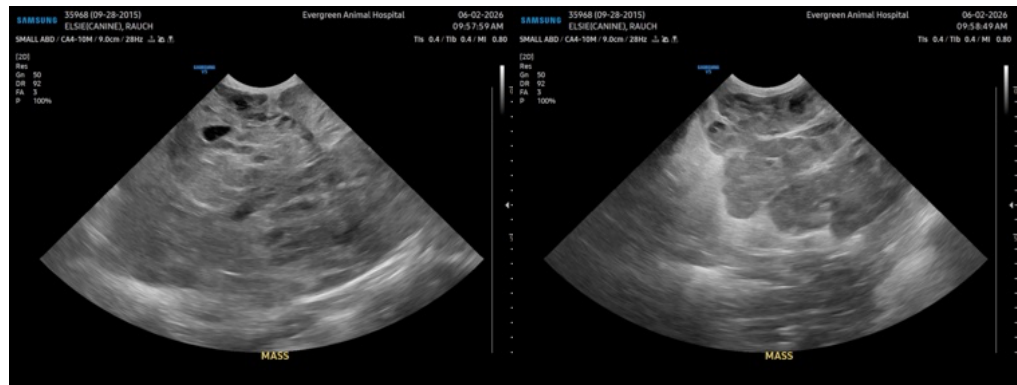
Dr. Maxey

INVOICE

78296

DATE

6/2/26



The information and recommendations provided are based on the images presented by the referring veterinarian/sonographer. No evaluation can be communicated regarding pathology that was not visible in the image/video clips provided.

Thank you for this referral. If the clinical or image interpretation does not parallel your findings or if I can be of any further assistance please contact me.

Remo Lobetti, BVSc, MMedVet (Med), PhD, Dipl. ECVIM (Internal Medicine)

info@sonopath.com