



## PATIENT

Chunk Tkachuk

## SPECIES

Canine

## BREED

Boston Cross

## SEX

Neutered male

## AGE

7 ½ years

## WEIGHT

12 kg

## INTERPRETED BY

Remo Lobetti, BVSc,  
MMedVet (Med),  
PhD, Dipl. ECVIM

## IMAGING PERFORMED BY

Danielle RVT

## HOSPITAL NAME

Orchard VC

## REFERRING VET

Dr. Wade

## INVOICE

78297

## DATE

6/2/26

## PRESENTING CLINICAL SIGNS

History: Chronic protruding anus. No improvement after medical and surgical management.

## ULTRASONOGRAPHIC EXAMINATION OF THE ABDOMEN

### *Urinary System*

The urinary bladder is full with a normal thickness and smooth appearance of the wall. Normal anechoic urine with no sediment or uroliths evident.

Normal appearance of the trigone area, proximal urethra, and iliac blood vessels.

Normal appearance and size of the iliac lymph nodes. Ureters not visualized, which can be considered a normal finding.

Normal renal size (left measured 4.1 cm, right measured 4.6 cm), architecture, echogenic appearance, cortico-medullary differentiation, which maintains a 1:3 cortex to medulla ratio, pelvis, and capsule. No infarcts, mineralization or renoliths evident. Normal color flow pattern is evident in both kidneys.

The prostate is small and hypoechogenic measuring 0.7 cm in width.

### *Adrenal Glands*

Normal shape, echogenic appearance, size, position, and appearance of the visible peri-adrenal vasculature. Left adrenal gland measured 0.42 cm and 0.53 cm in width. The right adrenal gland measured 0.64 cm and 0.54 cm in width.

### *Spleen*

Normal size and echogenic appearance. Smooth homogenous parenchyma and regular curvilinear capsule. Normal volume of the splenic vasculature without any overt congestion or thrombosis evident. No inflammatory, neoplastic, infarction, or infiltrative changes evident. The spleen measured 2.3 cm in width.

### *Liver*

Normal size, echogenic appearance, portal markings, and regular curvilinear capsule. No nodules or masses evident. Normal appearance of the hepatic and portal vasculature.

### *Gallbladder*

The gallbladder is small containing normal anechoic bile. Normal thickness and echogenic appearance of the wall. Normal size and appearance of the cystic and common bile duct.



## PATIENT

Chunk Tkachuk

## SPECIES

Canine

## BREED

Boston Cross

## SEX

Neutered male

## AGE

7 ½ years

## WEIGHT

12 kg

## INTERPRETED BY

Remo Lobetti, BVSc,  
MMedVet (Med),  
PhD, Dipl. ECVIM

## IMAGING PERFORMED BY

Danielle RVT

## HOSPITAL NAME

Orchard VC

## REFERRING VET

Dr. Wade

## INVOICE

78297

## DATE

6/2/26

## Gastrointestinal

Normal appearance of the stomach, duodenum, small intestine, ileo-cecal junction, and colon with no loss of layering, 1:3 muscularis to mucosa ratio, normal wall thickness and peristaltic activity, and no distension of the lumen. Fecal material was present in the colon.

## Pancreas

The visible sections of the pancreas are of normal size and echogenic appearance with a regular capsule. Normal echogenic appearance of the mesentery and fat surrounding the pancreas.

## Free Abdomen

Normal mesenteric lymph nodes.

No ascites evident.

## ULTRASONOGRAPHIC FINDINGS

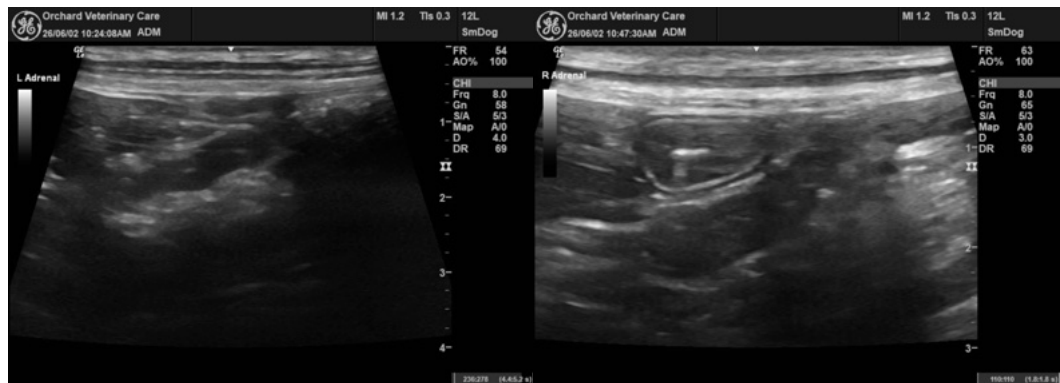
- Normal ultrasound examination of the abdomen.

## INTERPRETATION OF THE FINDINGS & FURTHER RECOMMENDATIONS

On this ultrasound there is no obvious etiology for the chronic protruding anus.

Further assessment would be colonoscopy with biopsies of both the colon and rectal wall.

Specific therapy would be dependent on an etiological diagnosis.





## PATIENT

Chunk Tkachuk

## SPECIES

Canine

## BREED

Boston Cross

## SEX

Neutered male

## AGE

7 ½ years

## WEIGHT

12 kg

## INTERPRETED BY

Remo Lobetti, BVSc,  
MMedVet (Med),  
PhD, Dipl. ECVIM

## IMAGING PERFORMED BY

Danielle RVT

## HOSPITAL NAME

Orchard VC

## REFERRING VET

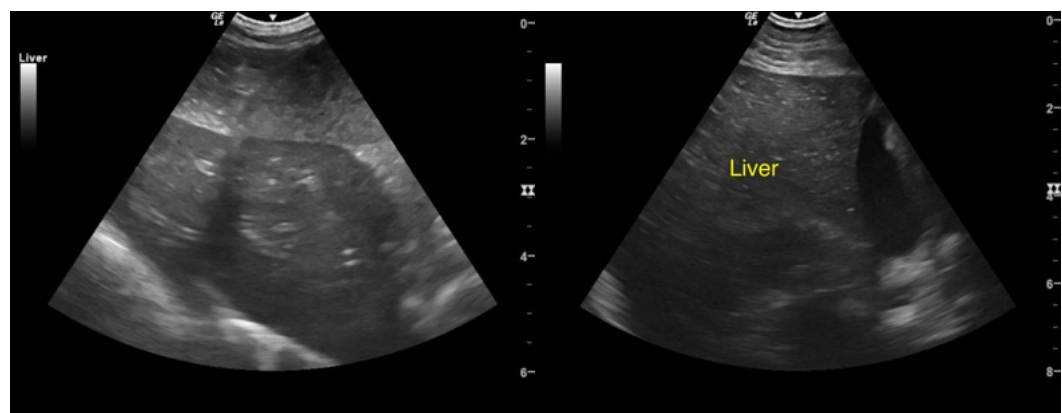
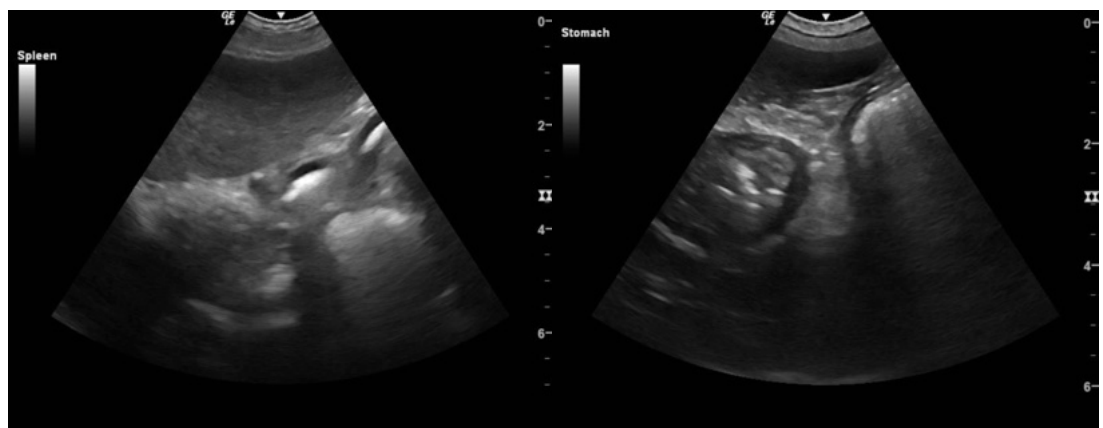
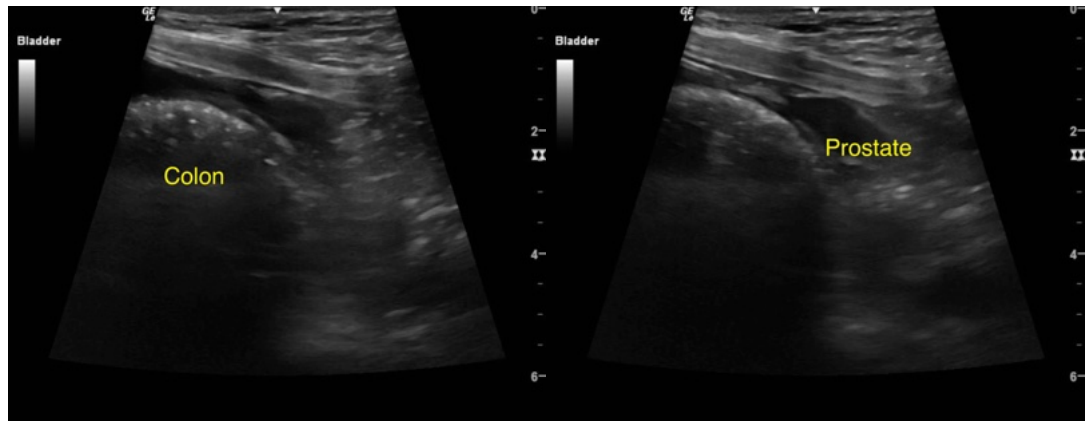
Dr. Wade

## INVOICE

78297

## DATE

6/2/26





## PATIENT

Chunk Tkachuk

## SPECIES

Canine

## BREED

Boston Cross

## SEX

Neutered male

## AGE

7 ½ years

## WEIGHT

12 kg

## INTERPRETED BY

Remo Lobetti, BVSc,  
MMedVet (Med),  
PhD, Dipl. ECVIM

## IMAGING PERFORMED BY

Danielle RVT

## HOSPITAL NAME

Orchard VC

## REFERRING VET

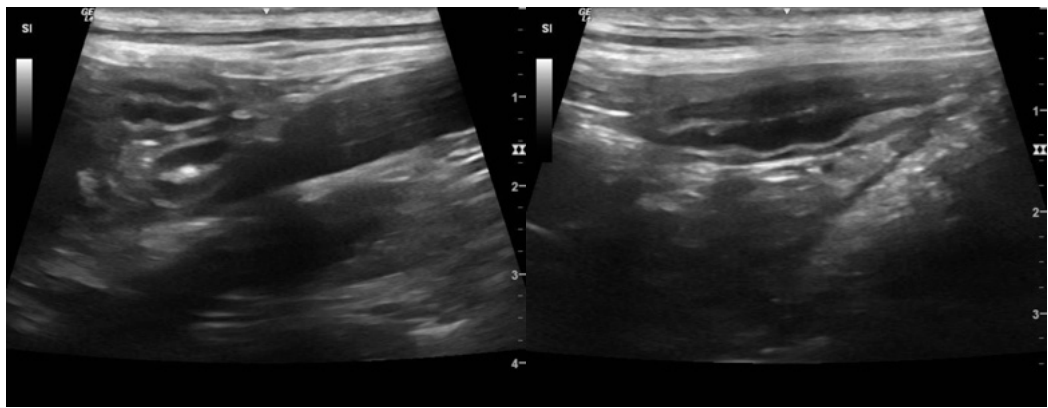
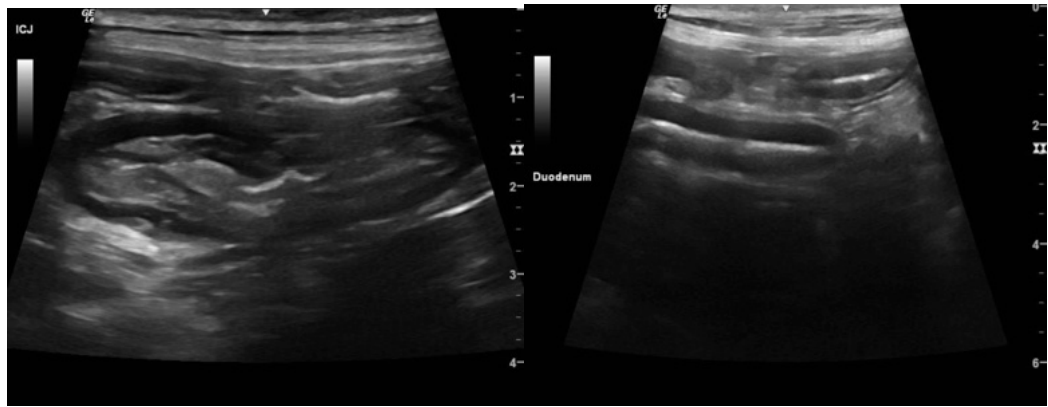
Dr. Wade

## INVOICE

78297

## DATE

6/2/26



The information and recommendations provided are based on the images presented by the referring veterinarian/sonographer. No evaluation can be communicated regarding pathology that was not visible in the image/video clips provided.

Thank you for this referral. If the clinical or image interpretation does not parallel your findings or if I can be of any further assistance please contact me.

Remo Lobetti, BVSc, MMedVet (Med), PhD, Dipl. ECVIM (Internal Medicine)

[info@sonopath.com](mailto:info@sonopath.com)