



PATIENT	PRESENTING CLINICAL SIGNS
Nimbus Cuppage	History: Stanguria and pollakiuria x 1 month - owner reports interrupted/unsteady stream of urine. No improvement with antibiotics.
SPECIES	Abnormal PE/Chem/CBC/UA Results: CBC/Chem - normal. UA (free catch) - small amount of blood.
Canine	ULTRASONOGRAPHIC EXAMINATION OF THE ABDOMEN
BREED	Urinary System
Samoyed	The urinary bladder is full with a normal thickness and smooth appearance of the wall. Normal anechoic urine with no sediment or uroliths evident.
	Normal appearance of the trigone area, proximal urethra, and iliac blood vessels.
SEX	Normal appearance and size of the iliac lymph nodes. Ureters not visualized, which can be considered a normal finding.
Neutered Male	
AGE	Normal renal size (left kidney 6.40 cm) (right kidney 6.10 cm), architecture, echogenic appearance, cortico-medullary differentiation, which maintains a 1:3 cortex to medulla ratio, pelvis, and capsule. No infarcts, mineralization or renoliths evident.
5 years	Reproductive System
WEIGHT	Enlarged prostate (2.80 x 3.00 cm) with an increased echogenic appearance and normal regular capsule. Normal appearance of the periprostatic tissue.
82 lbs	Adrenal Glands
	Normal shape, echogenic appearance, size (left: 2.74 cm in length x 0.55 x 0.44 cm) (right: 0.70 cm), position, and appearance of the visible peri-renal vasculature.
INTERPRETED BY	Spleen
Remo Lobetti, BVSc, MMedVet (Med), PhD, Dipl. ECVIM	Normal size and echogenic appearance. Smooth homogenous parenchyma and regular curvilinear capsule. Normal volume of the splenic vasculature without any overt congestion or thrombosis evident. No inflammatory, neoplastic, infarction, or infiltrative changes evident.
IMAGING PERFORMED BY	Liver
Elyse Hauer	Normal size, echogenic appearance, portal markings, and regular curvilinear capsule. No nodules or masses evident. Normal appearance of the hepatic and portal vasculature.
HOSPITAL NAME	Gallbladder
Mariposa VH	The gallbladder is full containing normal anechoic bile. Normal thickness and echogenic appearance of the wall. Normal size and appearance of the cystic and common bile duct.
REFERRING VET	Gastrointestinal
Alan Poon	Normal appearance of the stomach, duodenum, small intestine, ileo-cecal junction, and colon with no loss of layering, 1:3 muscularis to mucosa ratio, normal wall thickness and peristaltic activity, and no distension of the lumen.
INVOICE	Pancreas
	Normal size and echogenic appearance. Regular capsule. Normal echogenic appearance of the mesentery and fat surrounding the pancreas.

13412

DATE

6.19.23



PATIENT *Free Abdomen*
Normal mesenteric lymph nodes (0.90 x 1.40 cm).
Nimbus Cuppage
No ascites evident.

SPECIES **ULTRASONOGRAPHIC FINDINGS**

Canine **Primary Findings**

BREED

- Prostomegaly

Samoyed

Secondary Findings

- None

SEX

INTERPRETATION OF THE FINDINGS & FURTHER RECOMMENDATIONS

Neutered Male

The appearance of the prostate would be consistent with neoplasia with prostatitis a less likely differential diagnosis.

AGE

5 years

Further assessment would be urinalysis, urine culture, and prostatic wash. Although FNA can be done there is a risk of seeding from the FNA.

WEIGHT

82 lbs

Palliative management of the prostatic neoplasia would be NSAIDs as prostatectomy is generally not a feasible option and chemotherapy ineffective.

INTERPRETED BY

Remo Lobetti, BVSc,
MMedVet (Med),
PhD, Dipl. ECVIM

**IMAGING
PERFORMED BY**

Elyse Hauer

HOSPITAL NAME

Mariposa VH

REFERRING VET

Alan Poon

INVOICE

13412

DATE

6.19.23



PATIENT

Nimbus Cuppage

SPECIES

Canine

BREED

Samoyed

SEX

Neutered Male

AGE

5 years

WEIGHT

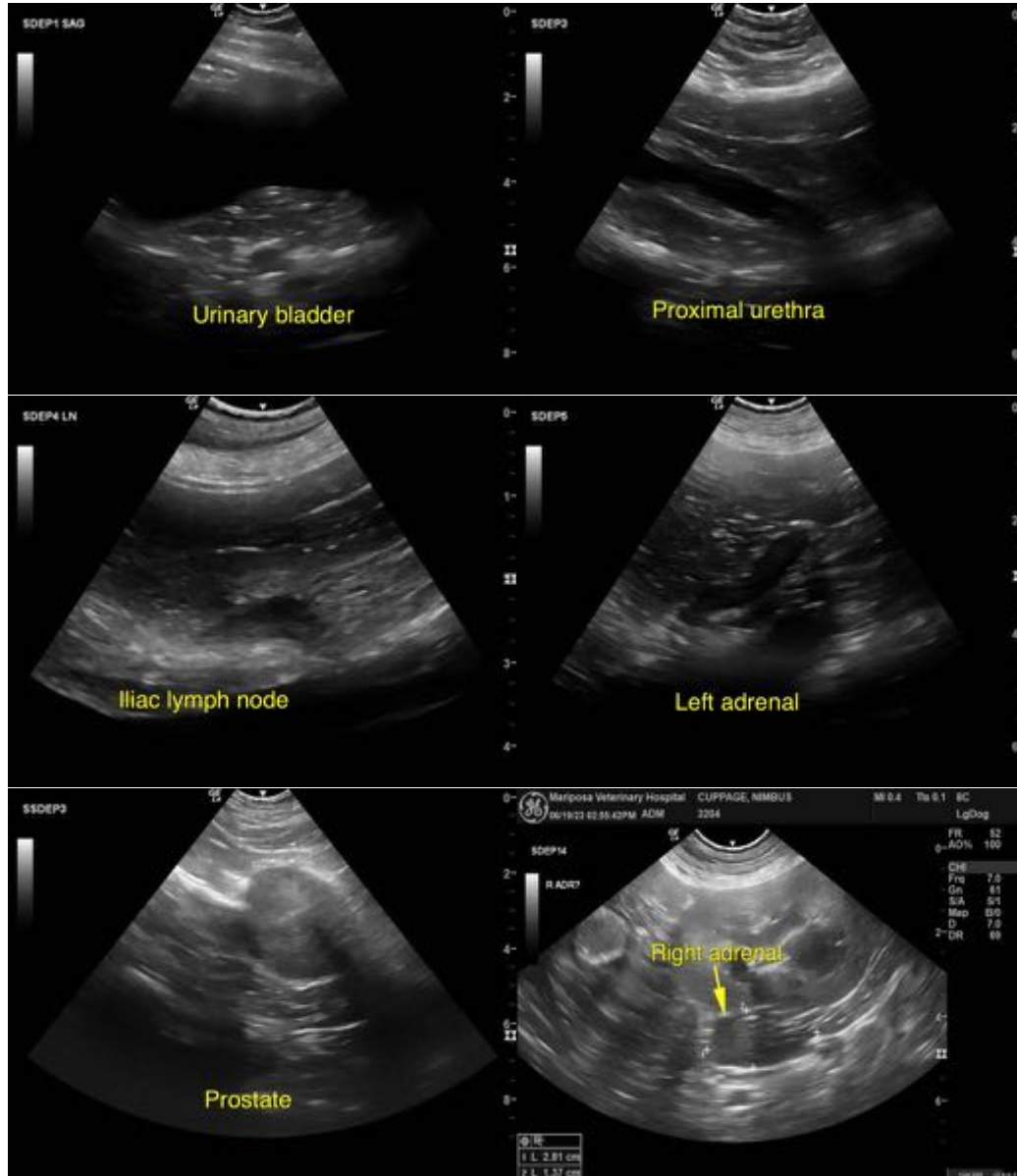
82 lbs

INTERPRETED BY

Remo Lobetti, BVSc,
MMedVet (Med),
PhD, Dipl. ECVIM

IMAGING PERFORMED BY

Elyse Hauer



HOSPITAL NAME

Mariposa VH

The information and recommendations provided are based on the images presented by the referring veterinarian. No evaluation can be communicated regarding pathology that was not visible in the image/video clips provided.

REFERRING VET

Alan Poon

Thank you for this referral. If the clinical or image interpretation does not parallel your findings or if I can be of any further assistance, please contact me.

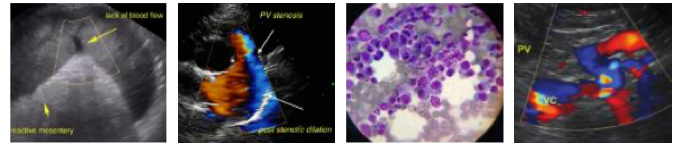
Remo Lobetti, BVSc, MMedVet (Med), PhD, Dipl. ECVIM (Internal Medicine)
info@sonopath.com

INVOICE

13412

DATE

6.19.23



PATIENT

Nimbus Cuppage

SPECIES

Canine

BREED

Samoyed

SEX

Neutered Male

AGE

5 years

WEIGHT

82 lbs

INTERPRETED BY

Remo Lobetti, BVSc,
MMedVet (Med),
PhD, Dipl. ECVIM

**IMAGING
PERFORMED BY**

Elyse Hauer

HOSPITAL NAME

Mariposa VH

REFERRING VET

Alan Poon

INVOICE

13412

DATE

6.19.23