



## PATIENT

Shelby Zapotocky

## SPECIES

Canine

## BREED

Scottish Terrier

## SEX

Spayd female

## AGE

10 years

## WEIGHT

26.5 lbs

## INTERPRETED BY

Remo Lobetti, BVSc,  
MMedVet (Med),  
PhD, Dipl. ECVIM

## IMAGING PERFORMED BY

Cristian Diaz

## HOSPITAL NAME

St Georges VH

## REFERRING VET

Dr. Ng

## INVOICE

78801

## DATE

6/17/26

## PRESENTING CLINICAL SIGNS

History: elevated ALP rising alp despite ursodiol, UTI and treating with amoxi.  
ALP 2114, WBC 4-10, RBC 11-20, sg 1.009, Coccobacilli.  
Patient is on ursodiol

## ULTRASONOGRAPHIC EXAMINATION OF THE ABDOMEN

### *Urinary System*

The urinary bladder is full with a normal thickness and smooth appearance of the wall. Normal anechoic urine with no sediment or uroliths evident.

Normal appearance of the trigone area, proximal urethra, and iliac blood vessels.

Normal appearance and size of the iliac lymph nodes. Ureters not visualized, which can be considered a normal finding.

Normal renal size (left measured 5.5 cm, right measured 5.0 cm), architecture, echogenic appearance, cortico-medullary differentiation, which maintains a 1:3 cortex to medulla ratio, pelvis, and capsule. No infarcts, mineralization or renoliths evident. Normal color flow pattern is evident in both kidneys.

### *Adrenal Glands*

The adrenal glands were not clearly visualized, but appears to be of normal shape, echogenic appearance and size.

### *Spleen*

Normal size and echogenic appearance. Smooth homogenous parenchyma and regular curvilinear capsule. Normal volume of the splenic vasculature without any overt congestion or thrombosis evident. No inflammatory, neoplastic, infarction, or infiltrative changes evident. The spleen measured 1.8 cm in width.

### *Liver*

The liver is enlarged with rounded edges, diffuse increased echogenic appearance, normal portal markings, and regular curvilinear capsule. No nodules or masses evident. Normal appearance of the hepatic and portal vasculature.

### *Gallbladder*

The gallbladder is full containing a scant amount of non-adhered, hyperechogenic sediment. Normal thickness and echogenic appearance of the wall. Normal size and appearance of the cystic and common bile duct.



**PATIENT**

Shelby Zapotocky

**SPECIES**

Canine

**BREED**

Scottish Terrier

**SEX**

Spayd female

**AGE**

10 years

**WEIGHT**

26.5 lbs

**INTERPRETED BY**

Remo Lobetti, BVSc,  
MMedVet (Med),  
PhD, Dipl. ECVIM

**IMAGING PERFORMED BY**

Cristian Diaz

**HOSPITAL NAME**

St Georges VH

**REFERRING VET**

Dr. Ng

**INVOICE**

78801

**DATE**

6/17/26

**Gastrointestinal**

Normal appearance of the stomach, duodenum, small intestine, ileo-cecal junction, and colon with no loss of layering, 1:3 muscularis to mucosa ratio, normal wall thickness and peristaltic activity, and no distension of the lumen.

**Pancreas**

The visible sections of the pancreas are of normal size and echogenic appearance with a regular capsule. Normal echogenic appearance of the mesentery and fat surrounding the pancreas.

**Free Abdomen**

Normal mesenteric lymph nodes.

No ascites evident.

**ULTRASONOGRAPHIC FINDINGS**

- Hepatopathy.

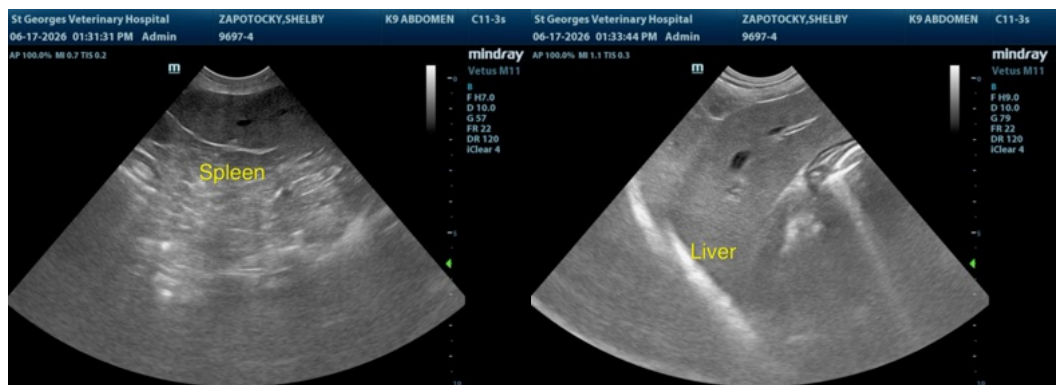
**INTERPRETATION OF THE FINDINGS & FURTHER RECOMMENDATIONS**

The most likely etiology for the hepatopathy would be breed specific hepatopathy with reactive hyperplasia, vacuolar and metabolic differential diagnosis.

Hepatitis and infiltrative neoplasia would be highly unlikely differential diagnosis.

Further assessment that could be considered would be FNA cytology of the liver; however, a tru cut or wedge biopsy may be required for a final etiological diagnosis.

Specific therapy would be dependent on an etiological diagnosis.





**PATIENT**

Shelby Zapotocky

**SPECIES**

Canine

**BREED**

Scottish Terrier

**SEX**

Spayd female

**AGE**

10 years

**WEIGHT**

26.5 lbs

**INTERPRETED BY**

Remo Lobetti, BVSc,  
MMedVet (Med),  
PhD, Dipl. ECVIM

**IMAGING  
PERFORMED BY**

Cristian Diaz

**HOSPITAL NAME**

St Georges VH

**REFERRING VET**

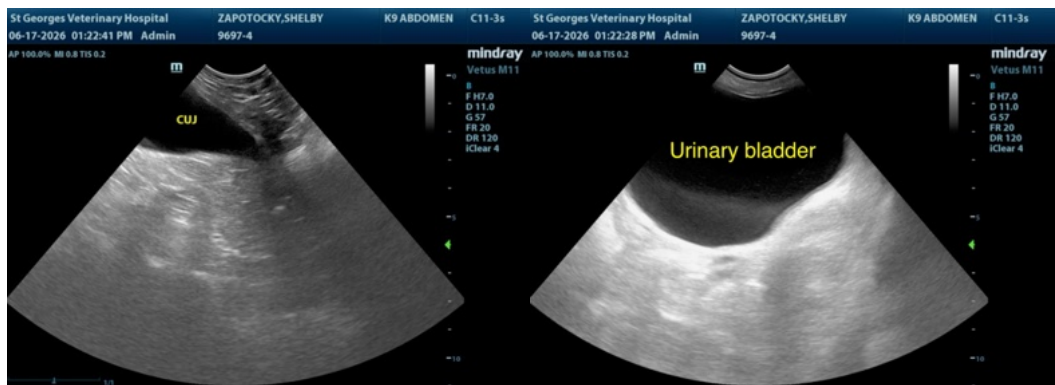
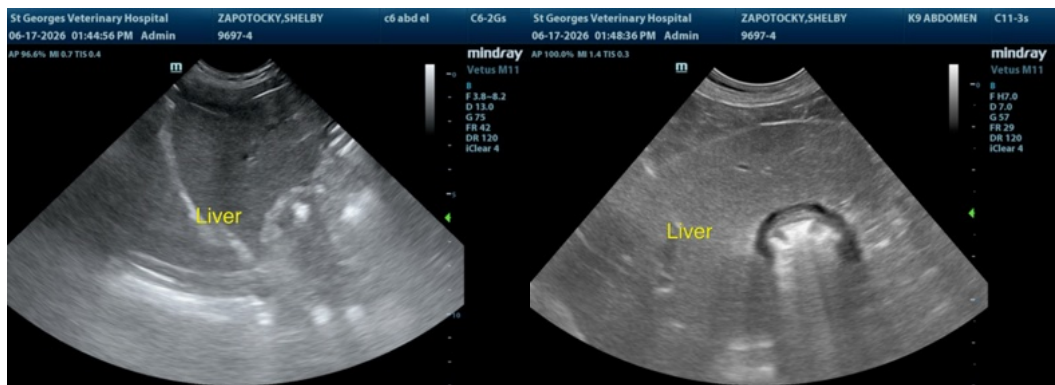
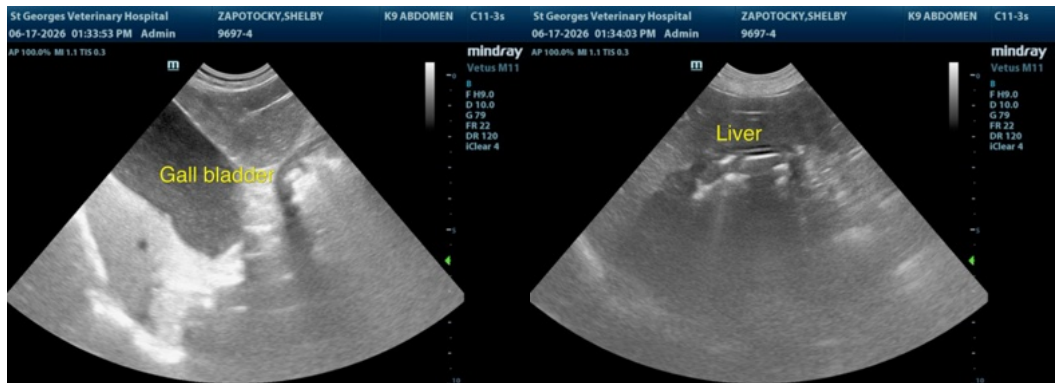
Dr. Ng

**INVOICE**

78801

**DATE**

6/17/26



The information and recommendations provided are based on the images presented by the referring veterinarian/sonographer. No evaluation can be communicated regarding pathology that was not visible in the image/video clips provided.

Thank you for this referral. If the clinical or image interpretation does not parallel your findings or if I can be of any further assistance please contact me.

Remo Lobetti, BVSc, MMedVet (Med), PhD, Dipl. ECVIM (Internal Medicine)

[info@sonopath.com](mailto:info@sonopath.com)