



## PATIENT

Emmo Yarmas

## SPECIES

Feline

## BREED

Domestic Shorthair

## SEX

Neutered male

## AGE

15 years

## WEIGHT

10.4 lbs

## INTERPRETED BY

Remo Lobetti, BVSc,  
MMedVet (Med),  
PhD, Dipl. ECVIM

## IMAGING PERFORMED BY

Dr. Marguiles

## HOSPITAL NAME

Fairland AH

## REFERRING VET

Dr. Marguiles

## INVOICE

78803

## DATE

6/17/26

## PRESENTING CLINICAL SIGNS

History: P has longstanding history of chronic vomiting and sensitive stomach. Recent labwork ran at annual visit and elevated calcium was noted. Hypercalcemia panel results are pending, but wanted to also check for any underlying causes of elevated calcium (lymphoma, etc). PE WNL

## ULTRASONOGRAPHIC EXAMINATION OF THE ABDOMEN

### *Urinary System*

The urinary bladder is full with a normal thickness and smooth appearance of the wall. Normal anechoic urine with no sediment or uroliths evident.

Normal appearance of the trigone area, proximal urethra, and iliac blood vessels.

Normal appearance and size of the iliac lymph nodes. Ureters not visualized, which can be considered a normal finding.

Normal renal size (left measured 4.0 cm, right measured 4.0 cm), architecture, echogenic appearance, cortico-medullary differentiation, which maintains a 1:3 cortex to medulla ratio, pelvis, and capsule. No infarcts, mineralization or renoliths evident. Normal color flow pattern is evident.

### *Adrenal Glands*

The adrenal glands were not visualized.

### *Spleen*

Normal size and echogenic appearance. Smooth homogenous parenchyma and regular curvilinear capsule. Normal volume of the splenic vasculature without any overt congestion or thrombosis evident. No inflammatory, neoplastic, infarction, or infiltrative changes evident. The spleen measured 0.6 cm in width.

### *Liver*

Normal size, echogenic appearance, portal markings, and regular curvilinear capsule. No nodules or masses evident. Normal appearance of the hepatic and portal vasculature.

### *Gallbladder*

The gallbladder is small containing normal anechoic bile. Normal thickness and echogenic appearance of the wall. Normal size and appearance of the cystic and common bile duct.



## PATIENT

Emmo Yarmas

## SPECIES

Feline

## BREED

Domestic Shorthair

## SEX

Neutered male

## AGE

15 years

## WEIGHT

10.4 lbs

## INTERPRETED BY

Remo Lobetti, BVSc,  
MMedVet (Med),  
PhD, Dipl. ECVIM

## IMAGING PERFORMED BY

Dr. Marguiles

## HOSPITAL NAME

Fairland AH

## REFERRING VET

Dr. Marguiles

## INVOICE

78803

## DATE

6/17/26

## *Gastrointestinal*

Normal appearance of the stomach, duodenum, ileo-cecal junction, and colon with no loss of layering, 1:3 muscularis to mucosa ratio, normal wall thickness and peristaltic activity, and no distension of the lumen. The small intestine (up to 2.5 cm) with no loss of layering but with an increase in the muscularis to mucosa ratio, normal peristaltic activity and no distension of the lumen.

## *Pancreas*

The visible sections of the pancreas are of normal size and echogenic appearance with a regular capsule. Normal echogenic appearance of the mesentery and fat surrounding the pancreas.

## *Free Abdomen*

Normal mesenteric lymph nodes.

No ascites evident.

## ULTRASONOGRAPHIC FINDINGS

- Enteropathy.

## INTERPRETATION OF THE FINDINGS & FURTHER RECOMMENDATIONS

Etiologies for the enteropathy would be parasitic enteritis, dietary hypersensitivity and inflammatory bowel disease with lymphoma an important differential diagnosis as hypercalcemia is present.

Further assessment would be fecal analysis, cobalamin and folate assay and endoscopy of the upper GI tract with biopsies.

Specific therapy would be dependent on an etiological diagnosis.

Symptomatic management of the enteropathy that can be considered would be feeding small, frequent meals of a novel protein/hypoallergenic diet, course of Fenbendazole, cobalamin supplementation and if there is not a satisfactory improvement then a course of Prednisolone would then be indicated.



## PATIENT

Emmo Yarmas

## SPECIES

Feline

## BREED

Domestic Shorthair

## SEX

Neutered male

## AGE

15 years

## WEIGHT

10.4 lbs

## INTERPRETED BY

Remo Lobetti, BVSc,  
MMedVet (Med),  
PhD, Dipl. ECVIM

## IMAGING PERFORMED BY

Dr. Marguiles

## HOSPITAL NAME

Fairland AH

## REFERRING VET

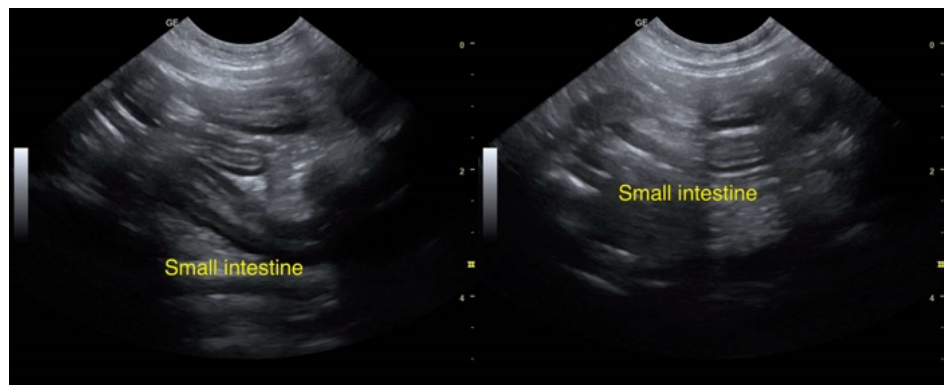
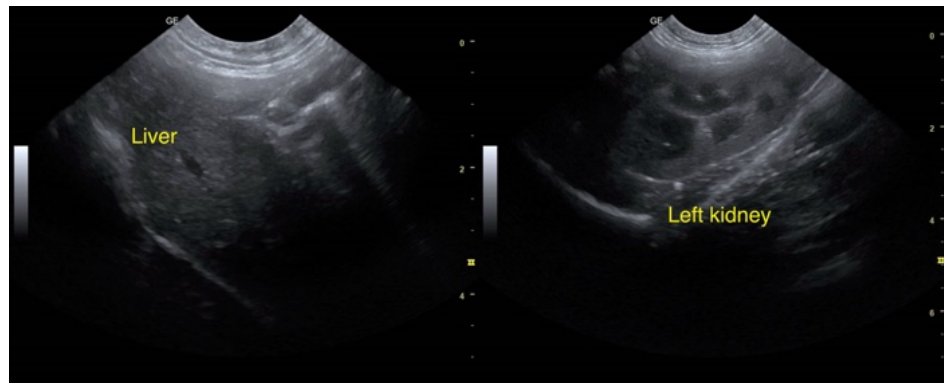
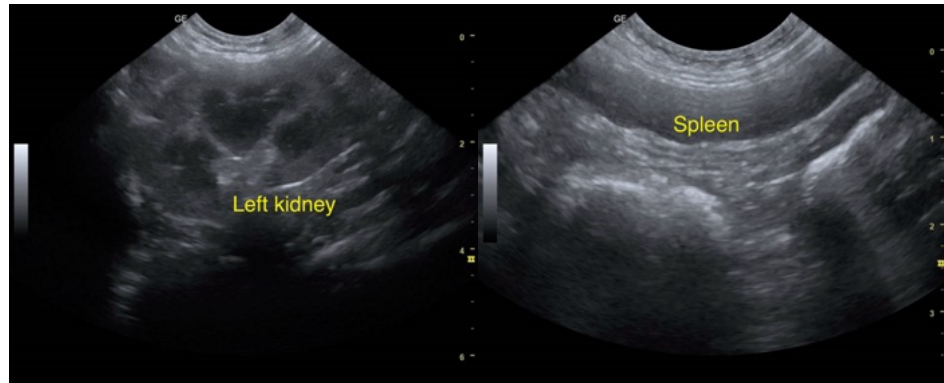
Dr. Marguiles

## INVOICE

78803

## DATE

6/17/26





## PATIENT

Emmo Yarmas

## SPECIES

Feline

## BREED

Domestic Shorthair

## SEX

Neutered male

## AGE

15 years

## WEIGHT

10.4 lbs

## INTERPRETED BY

Remo Lobetti, BVSc,  
MMedVet (Med),  
PhD, Dipl. ECVIM

## IMAGING PERFORMED BY

Dr. Marguiles

## HOSPITAL NAME

Fairland AH

## REFERRING VET

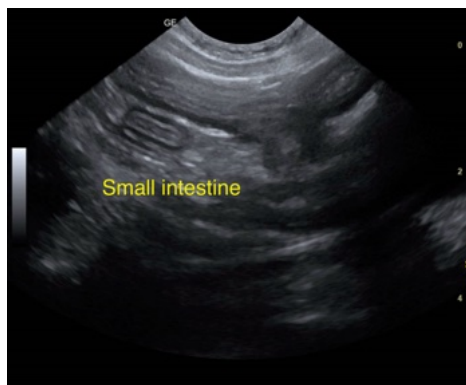Dr. Marguiles

## INVOICE

78803

## DATE

6/17/26



The information and recommendations provided are based on the images presented by the referring veterinarian/sonographer. No evaluation can be communicated regarding pathology that was not visible in the image/video clips provided.

Thank you for this referral. If the clinical or image interpretation does not parallel your findings or if I can be of any further assistance please contact me.

Remo Lobetti, BVSc, MMedVet (Med), PhD, Dipl. ECVIM (Internal Medicine)

[info@sonopath.com](mailto:info@sonopath.com)