



PATIENT

Colt Manuel

SPECIES

Canine

BREED

Akita

SEX

Neutered male

AGE

10 years

WEIGHT

107 lbs

INTERPRETED BY

Remo Lobetti, BVSc,
MMedVet (Med),
PhD, Dipl. ECVIM

IMAGING PERFORMED BY

Dr. Kelly Vida

HOSPITAL NAME

Sherrills Ford AH

REFERRING VET

Dr. Vida

INVOICE

78800

DATE

6/17/26

PRESENTING CLINICAL SIGNS

History: History of chronic Alkp and GGT elevation over past several months but recent lab work had elevation in ALT.

6/2026 labs: ALT: 135, Alkp: 414, GGT: 87

Performed abdominal brief ultrasound of liver/gallbladder and spleen to rule out any concerns prior to a dental procedure.

ULTRASONOGRAPHIC EXAMINATION OF THE ABDOMEN

Spleen

Normal size and echogenic appearance. Smooth homogenous parenchyma and regular curvilinear capsule. Normal volume of the splenic vasculature without any overt congestion or thrombosis evident. No inflammatory, neoplastic, infarction, or infiltrative changes evident. The spleen measured 2.0 cm in width.

Liver

Normal size, echogenic appearance, portal markings, and regular curvilinear capsule. No nodules or masses evident. Normal appearance of the hepatic and portal vasculature.

Gallbladder

The gallbladder is full containing normal anechoic bile. Normal thickness and echogenic appearance of the wall. Normal size and appearance of the cystic and common bile duct.

ULTRASONOGRAPHIC FINDINGS

- Normal ultrasonographic appearance of the liver, spleen and gallbladder.

INTERPRETATION OF THE FINDINGS & FURTHER RECOMMENDATIONS

Although the liver appears ultrasonographically normal, with the elevated liver enzyme activity, an underlying hepatopathy such as reactive hyperplasia, vacuolar and metabolic should still be considered.

Further assessment that can be considered would be FNA cytology of the liver; however, a tru cut or wedge biopsy may be required for a final etiological diagnosis.

Specific therapy would be dependent on an etiological diagnosis.

Symptomatic management that can be considered would be the use of the Ursodiol with regular monitoring of liver enzyme activity.



PATIENT

Colt Manuel

SPECIES

Canine

BREED

Akita

SEX

Neutered male

AGE

10 years

WEIGHT

107 lbs

INTERPRETED BY

Remo Lobetti, BVSc,
MMedVet (Med),
PhD, Dipl. ECVIM

IMAGING PERFORMED BY

Dr. Kelly Vida

HOSPITAL NAME

Sherrills Ford AH

REFERRING VET

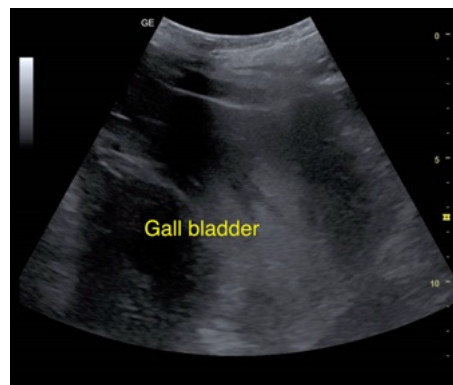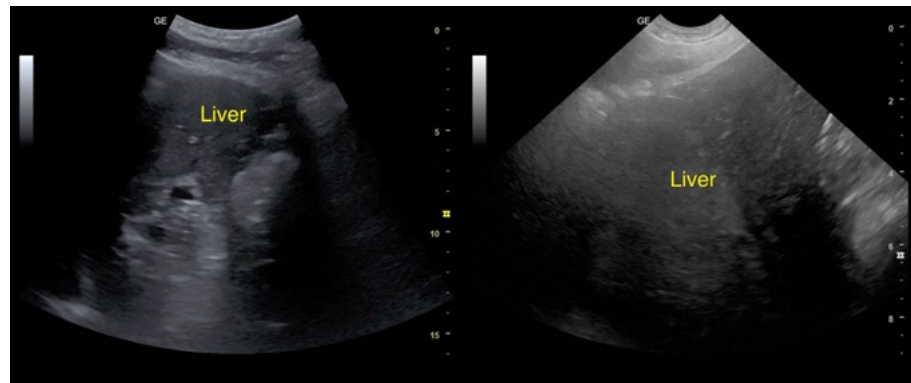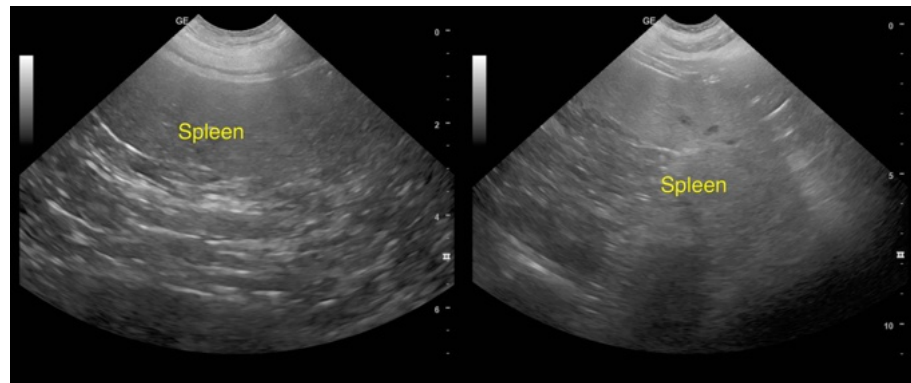
Dr. Vida

INVOICE

78800

DATE

6/17/26



The information and recommendations provided are based on the images presented by the referring veterinarian/sonographer. No evaluation can be communicated regarding pathology that was not visible in the image/video clips provided.

Thank you for this referral. If the clinical or image interpretation does not parallel your findings or if I can be of any further assistance please contact me.

Remo Lobetti, BVSc, MMedVet (Med), PhD, Dipl. ECVIM (Internal Medicine)

info@sonopath.com