PAUS
Pet Animal Ultrasound Service
4paus.com 781-635-5677

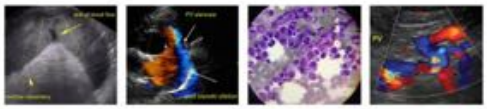

SonoPath
Clinical Sonography & Telecytology
EDUCATIONAL TELECONSULTATION SERVICES™
1-800-838-4268 info@sonopath.com SonoPath.com

PATIENT

Tuukka Berardi

SPECIES

Feline

BREED

DSH

SEX

Female Spayed

AGE

9 years

WEIGHT

16.2 lbs

INTERPRETED BY

Remo Lobetti, BVSc, MMedVet (Med), PhD, Dipl. ECVIM

IMAGING PERFORMED BY

Pamela Harrigan, RDCS

HOSPITAL NAME

Norfolk County VS

REFERRING VET

Emily McCabe, DVM

INVOICE

13391

DATE

6.16.23

PRESENTING CLINICAL SIGNS

History: Presented for annual exam on 5/27 with complaint of "urine odor". On PE, p had urine scalding at vulva with swelling. Attempted cysto but visualized intra-mural structural (r/o tumor, polyp, inflammation, clot), so did not perform cysto. Free catch urine performed.
Study limited to urinary system

Abnormal PE/Chem/CBC/UA Results: Blood 2+, RBC 21-50 (note no bacteria or WBC)

LIMITED ULTRASONOGRAPHIC EXAMINATION

Urinary System
The urinary bladder is full with focal irregular thickening of the dorsal bladder wall (approximately 1.00 cm in length). The lesion appears to be intramural, with a mottled, echogenic appearance, and small amount of shadowing. The rest of the bladder wall has a normal thickness and smooth appearance. Normal anechoic urine with no sediment or uroliths evident.

Normal appearance of the trigone area, proximal urethra.

Illiac Lymph Nodes
Not visualized.

Kidneys
Both kidneys measure 4.00 cm in length. Nothing further to add, as there are no other images submitted.

ULTRASONOGRAPHIC FINDINGS

Findings

- Focal thickening of the urinary bladder wall

Secondary Findings

- None

INTERPRETATION OF THE FINDINGS & FURTHER RECOMMENDATIONS

Etiologies for the focal thickening of the bladder wall would be neoplasia, granulomatous reaction, chronic cystitis, adhered hematoma, and adhered mineralized sediment.

Further assessment would be urine culture, and if possible, a catheter-assisted aspirate or biopsy of the lesion. Cystotomy with resection of that section of the bladder wall may however be required for a final etiological diagnosis, as well as being therapeutic.

PAUS
Pet Animal Ultrasound Service
4paus.com 781-635-5677

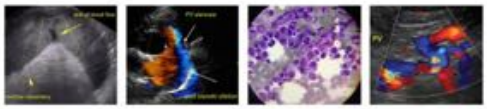

SonoPath
Clinical Sonography & Telecytology
EDUCATIONAL TELECONSULTATION SERVICES™
1-800-838-4268 info@sonopath.com SonoPath.com

PATIENT

Tuukka Berardi

SPECIES

Feline

BREED

DSH

SEX

Female Spayed

AGE

9 years

WEIGHT

16.2 lbs

INTERPRETED BY

Remo Lobetti, BVSc, MMedVet (Med), PhD, Dipl. ECVIM

IMAGING PERFORMED BY

Pamela Harrigan, RDCS

HOSPITAL NAME

Norfolk County VS

REFERRING VET

Emily McCabe, DVM

INVOICE

13391

DATE

6.16.23

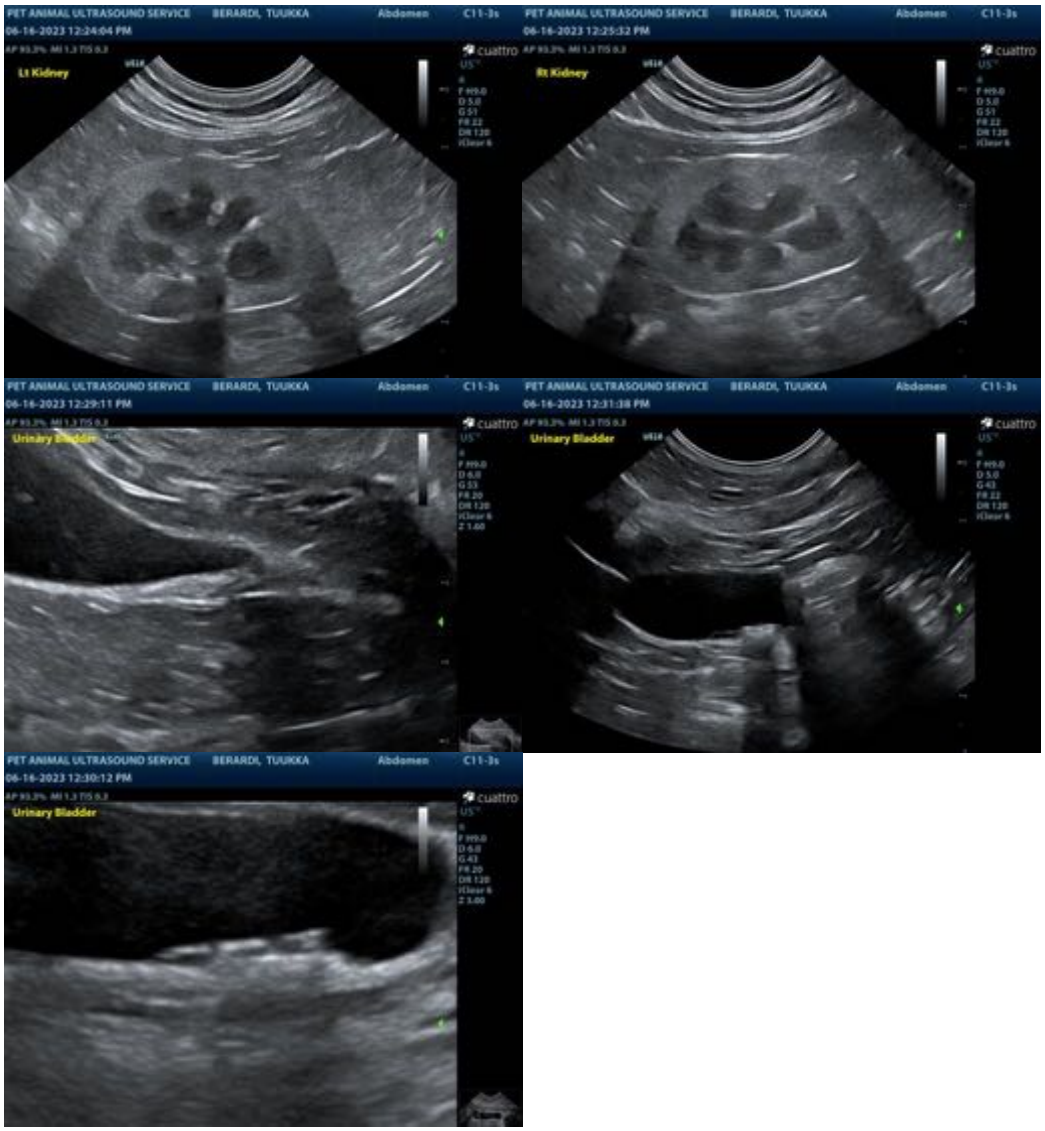

The information and recommendations provided are based on the images presented by the referring veterinarian. No evaluation can be communicated regarding pathology that was not visible in the image/video clips provided.

Thank you for this referral. If the clinical or image interpretation does not parallel your findings or if I can be of any further assistance, please contact me.

Remo Lobetti, BVSc, MMedVet (Med), PhD, Dipl. ECVIM (Internal Medicine)
info@sonopath.com