



PATIENT

Remi Winquist

SPECIES

Canine

BREED

Husky

SEX

Neutered Male

AGE

7.5 Years

WEIGHT

25.2 lbs

INTERPRETED BY

Remo Lobetti, BVSc,
MMedVet (Med), PhD,
Dipl. ECVIM (Internal
Medicine)

IMAGING PERFORMED BY

Dr. Gary Jimmerson

HOSPITAL NAME

Willamette Veterinary
Hospital

REFERRING VET

Dr. Gary Jimmerson

INVOICE

16019

DATE

05/09/26

PRESENTING CLINICAL SIGNS

Duplicate case - images not sending via DICOM, files uploaded below via thumb drive

LIMITED ULTRASONOGRAPHIC EXAMINATION

Full urinary bladder with a normal thickness and smooth appearance of the wall. Normal anechoic urine with no sediment or uroliths evident.

Normal appearance of the trigone area, proximal urethra, and iliac blood vessels.

Normal appearance and size of the iliac lymph nodes. Ureters not visualized, which can be considered a normal finding.

Small hypoechogenic prostate.

Normal renal size, with increased echogenic appearance, loss of corticomedullary differentiation, normal pelvis and capsule. No infarcts, mineralization or renoliths are evident. Normal color flow pattern evident in both kidneys. The left kidney measured 6.4 cm in length. The right kidney measured 5.6 cm in length.

Irregular and cystic appearance of the left adrenal gland measuring approximately 0.9 cm x 1.4 cm in size but maintaining normal position and appearance of the visible periadrenal vasculature.

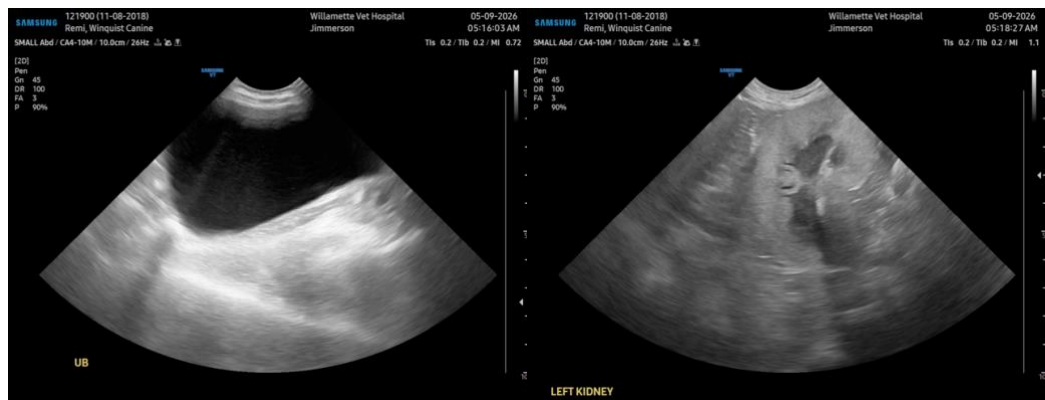
ULTRASONOGRAPHIC FINDINGS

- Renal disease
- Left adrenal pathology

INTERPRETATION OF THE FINDINGS & FURTHER RECOMMENDATIONS

The appearance of the kidneys will be consistent with chronic kidney disease. The left adrenal gland is most likely an incidental finding.

Further assessment would be blood pressure. Management of the renal disease would be feeding a renal diet, enteric phosphate binders, and possibly the use of either an ace inhibitor or receptor blocker.





PATIENT

Remi Winquist

SPECIES

Canine

BREED

Husky

SEX

Neutered Male

AGE

7.5 Years

WEIGHT

25.2 lbs

INTERPRETED BY

Remo Lobetti, BVSc,
MMedVet (Med), PhD,
Dipl. ECVIM (Internal
Medicine)

IMAGING PERFORMED BY

Dr. Gary Jimmerson

HOSPITAL NAME

Willamette Veterinary
Hospital

REFERRING VET

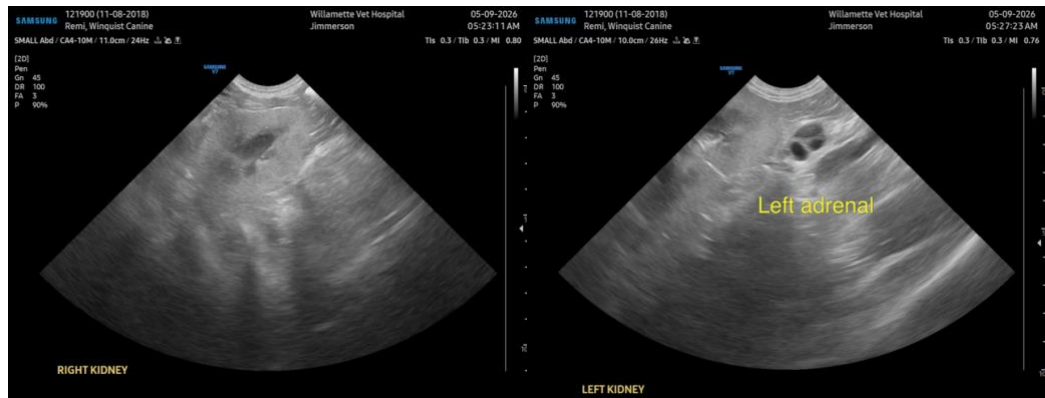
Dr. Gary Jimmerson

INVOICE

16019

DATE

05/09/26



The information and recommendations provided are based on the images presented by the referring veterinarian/sonographer. No evaluation can be communicated regarding pathology that was not visible in the image/video clips provided.

Thank you for this referral. If the clinical or image interpretation does not parallel your findings or if I can be of any further assistance, please contact me.

Remo Lobetti, BVSc, MMedVet (Med), PhD, Dipl. ECVIM (Internal Medicine)

info@sonopath.com