



PATIENT

Beau Patterson

SPECIES

Canine

BREED

Australian Shepherd

SEX

Neutered Male

AGE

12 Years

WEIGHT

69.1 lbs

INTERPRETED BY

Remo Lobetti, BVSc,
MMedVet (Med), PhD,
Dipl. ECVIM (Internal
Medicine)

IMAGING PERFORMED BY

Janel Schietzelt DVM

HOSPITAL NAME

Dreaming Summit
Animal Hospital

REFERRING VET

Janel Schietzelt DVM

INVOICE

15992

DATE

05/08/26

PRESENTING CLINICAL SIGNS

Patient presents for routine ultrasound as part of senior screening. Owner reports more "lumps and bumps" externally and just wanting to make sure internally is doing well. Normal appetite, no pu/pd, no vomiting or diarrhea reported. FNA/cytology of subcutaneous masses pending (suspect lipomas). *Vitals WNL other than patient is 9/9 body condition score. Moderate to heavy periodontal disease present. -Neoplastic screening is main goal of ultrasound

Abnormal PE/Chem/CBC/UA Results: Mild hypertriglyceridemia (253) -2+ struvite crystalluria - Remainder WNL including normal liver values and total T4 (1.3) at that time -Fecal negative

ULTRASONOGRAPHIC EXAMINATION OF THE ABDOMEN

Urinary System

Small urinary bladder with a normal thickness and smooth appearance of the wall. Normal anechoic urine with no sediment or uroliths evident.

Normal appearance of the trigone area, proximal urethra, and iliac blood vessels.

Normal appearance and size of the iliac lymph nodes. Ureters not visualized, which can be considered a normal finding.

Small hypoechogenic prostate.

Normal renal size, architecture, echogenic appearance, cortico-medullary differentiation, which maintains a 1:3 cortex to medulla ratio, pelvis, and capsule. No infarcts, mineralization or renoliths evident. The left kidney measured 6.2 cm in length. The right kidney measured 6.9 cm in length. Normal color flow evident in both kidneys.

Adrenal Glands

Normal shape, echogenic appearance, size, position, and appearance of the visible peri-adrenal vasculature. The left adrenal gland measured 1.97 cm length x 0.57 cm and 0.54 cm in width. The right adrenal gland measured 0.50 cm in width.

Spleen

Normal size and echogenic appearance. Smooth homogenous parenchyma and regular curvilinear capsule. Normal volume of the splenic vasculature without any overt congestion or thrombosis evident. No inflammatory, neoplastic, infarction, or infiltrative changes evident. The spleen measured 2.3 cm in width.

Liver

Normal size, echogenic appearance, portal markings, and regular curvilinear capsule. No nodules or masses evident. Normal appearance of the hepatic and portal vasculature.

Gallbladder

Full gallbladder containing normal anechoic bile. Normal thickness and echogenic appearance of the wall. Normal size and appearance of the cystic and common bile duct.



PATIENT

Beau Patterson

SPECIES

Canine

BREED

Australian Shepherd

SEX

Neutered Male

AGE

12 Years

WEIGHT

69.1 lbs

INTERPRETED BY

Remo Lobetti, BVSc,
MMedVet (Med), PhD,
Dipl. ECVIM (Internal
Medicine)

IMAGING PERFORMED BY

Janel Schietzelt DVM

HOSPITAL NAME

Dreaming Summit
Animal Hospital

REFERRING VET

Janel Schietzelt DVM

INVOICE

15992

DATE

05/08/26

Gastrointestinal

Normal appearance of the stomach, duodenum, small intestine, ileo-cecal junction, and colon with no loss of layering, 1:3 muscularis to mucosa ratio, normal wall thickness and peristaltic activity, and no distension of the lumen.

Pancreas

Visible sections of the pancreas are of normal size and echogenic appearance with a regular capsule. Normal echogenic appearance of the mesentery and fat surrounding the pancreas.

Free Abdomen

Normal mesenteric lymph nodes.

No ascites evident.

Large amount of intra-abdominal fat accumulation.

ULTRASONOGRAPHIC FINDINGS

- Normal ultrasound examination of the abdomen.

INTERPRETATION OF THE FINDINGS & FURTHER RECOMMENDATIONS

No evidence of visceral pathology.



PATIENT

Beau Patterson

SPECIES

Canine

BREED

Australian Shepherd

SEX

Neutered Male

AGE

12 Years

WEIGHT

69.1 lbs

INTERPRETED BY

Remo Lobetti, BVSc,
MMedVet (Med), PhD,
Dipl. ECVIM (Internal
Medicine)

**IMAGING
PERFORMED BY**

Janel Schietzelt DVM

HOSPITAL NAME

Dreaming Summit
Animal Hospital

REFERRING VET

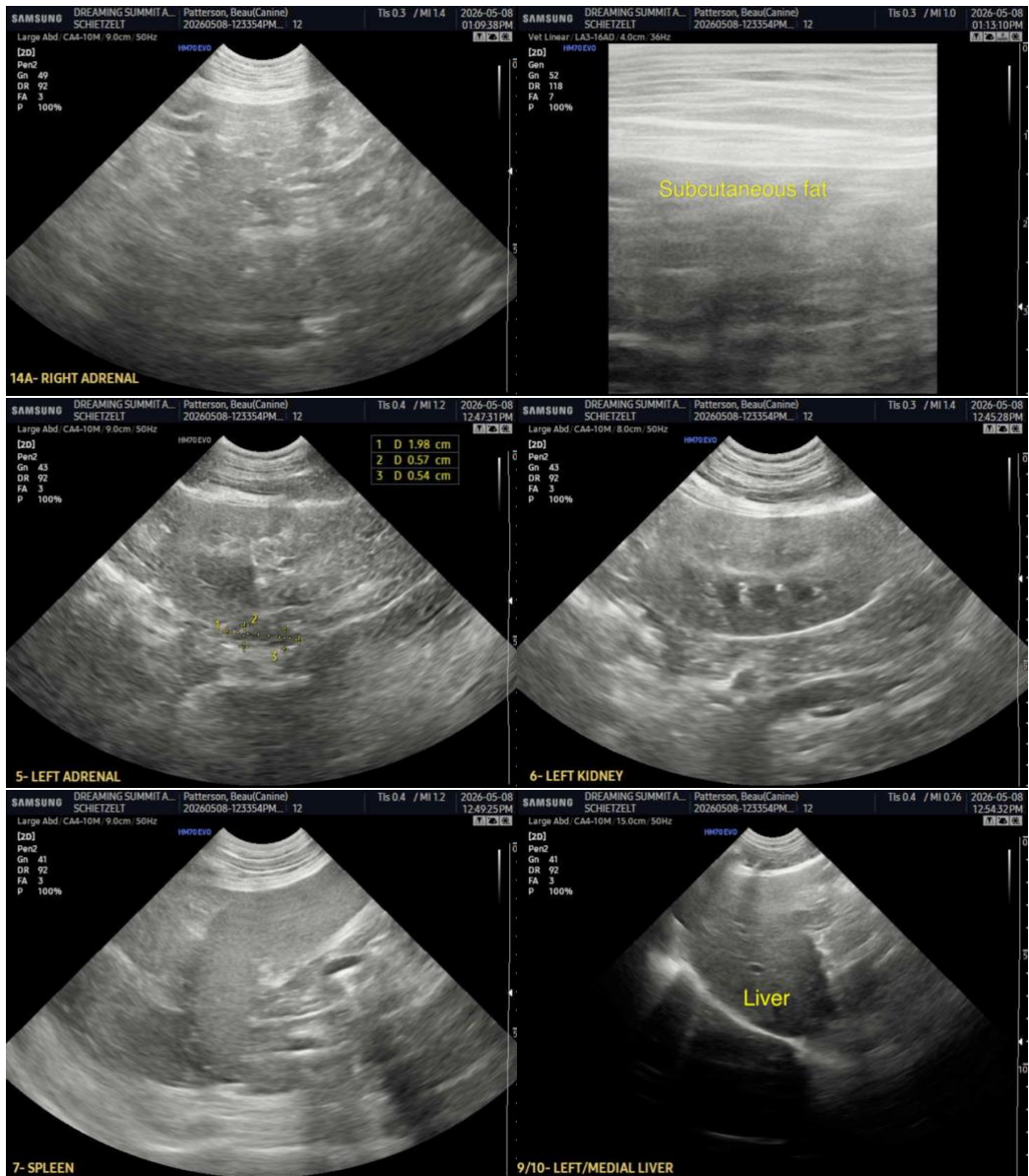
Janel Schietzelt DVM

INVOICE

15992

DATE

05/08/26





PATIENT

Beau Patterson

SPECIES

Canine

BREED

Australian Shepherd

SEX

Neutered Male

AGE

12 Years

WEIGHT

69.1 lbs

INTERPRETED BY

Remo Lobetti, BVSc,
MMedVet (Med), PhD,
Dipl. ECVIM (Internal
Medicine)

IMAGING PERFORMED BY

Janel Schietzelt DVM

HOSPITAL NAME

Dreaming Summit
Animal Hospital

REFERRING VET

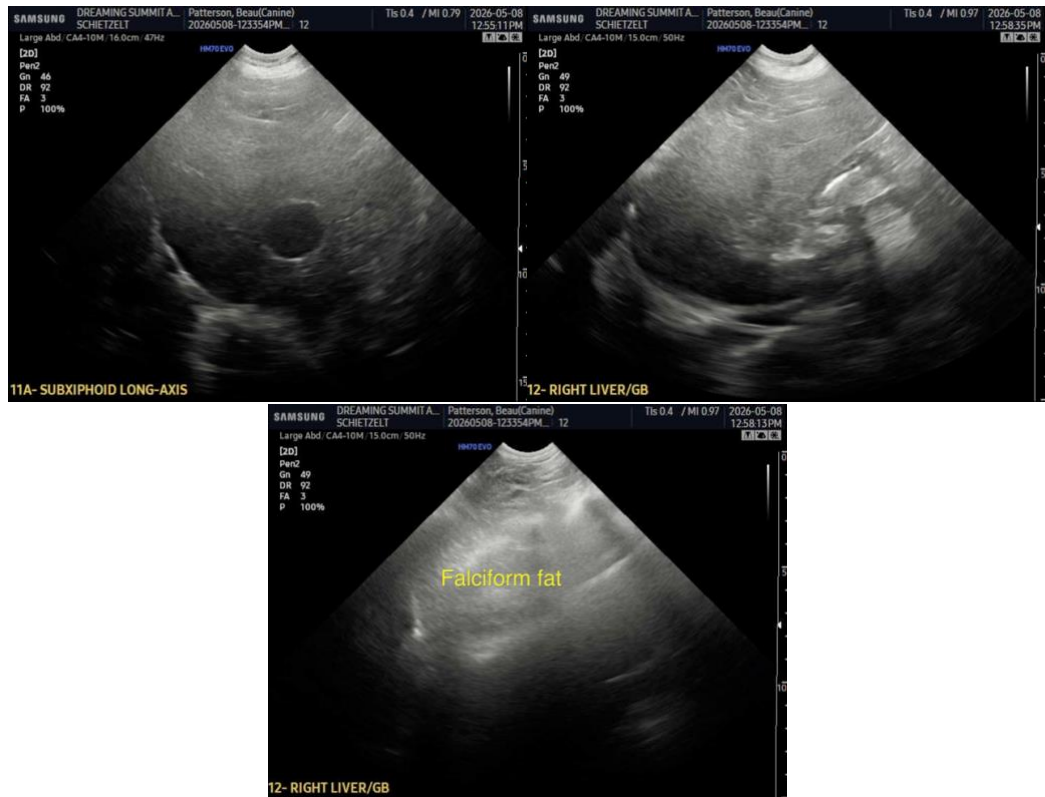
Janel Schietzelt DVM

INVOICE

15992

DATE

05/08/26



The information and recommendations provided are based on the images presented by the referring veterinarian/sonographer. No evaluation can be communicated regarding pathology that was not visible in the image/video clips provided.

Thank you for this referral. If the clinical or image interpretation does not parallel your findings or if I can be of any further assistance, please contact me.

Remo Lobetti, BVSc, MMedVet (Med), PhD, Dipl. ECVIM (Internal Medicine)

info@sonopath.com