



## PATIENT

Annie Downs

## SPECIES

Canine

## BREED

Norfolk Terrier

## SEX

FS

## AGE

11 months

## WEIGHT

6 kg

## INTERPRETED BY

Remo Lobetti, BVSc,  
MMedVet (Med),  
PhD, Dipl. ECVIM

## IMAGING PERFORMED BY

Dr. Caroline Tan

## HOSPITAL NAME

Bowness Animal  
Hospital

## REFERRING VET

Dr. Satnam Dhothar

## INVOICE

11914

## DATE

5/8/2026

## PRESENTING CLINICAL SIGNS

Attending reports that main concern so hyporexic No VD will eat from owners hand. Recent labs had elevated cystatin B but normal urea and creat.

Abnormal PE/Chem/CBC/UA Results: High cystatin b Rest of labs unremarkable.

## ULTRASONOGRAPHIC EXAMINATION OF THE ABDOMEN

### Urinary System

Full urinary bladder containing a small amount of both floating and dependent hyperechogenic sediment, as well as a few small uroliths. Normal thickness and smooth appearance of the wall.

Normal appearance of the trigone area, proximal urethra, and iliac blood vessels.

Normal appearance and size of the iliac lymph nodes. Ureters not visualized, which can be considered a normal finding.

Normal renal size, architecture, echogenic appearance, cortico-medullary differentiation, which maintains a 1:3 cortex to medulla ratio, pelvis, and capsule. No infarcts, mineralization or renoliths evident. Left kidney measures 3.7 cm and the right kidney measures 3.9 cm.

### Adrenal Glands

Normal shape, echogenic appearance, size, position, and appearance of the visible peri-adrenal vasculature. Left adrenal gland measures 0.36 cm and 0.26 cm in width. Right adrenal gland measures 0.54 cm in width.

### Spleen

Normal size and echogenic appearance. Smooth homogenous parenchyma and regular curvilinear capsule. Normal volume of the splenic vasculature without any overt congestion or thrombosis evident. No inflammatory, neoplastic, infarction, or infiltrative changes evident. The spleen measures 1.3 cm in width.

### Liver

Normal size with a diffuse mottled echogenic coarse and appearance, normal portal markings, and regular curvilinear capsule. Nodules are diffuse, hypoechogenic, and parenchymal and measure up to 1.0 cm in size. No masses evident. Normal appearance of the hepatic and portal vasculature.

### Gallbladder

Full containing a small amount of hyperechogenic sediment as well as few small choleliths. Normal thickness and echogenic appearance of the wall. Normal size and appearance of the cystic and common bile duct.

### Gastrointestinal

Normal appearance of the stomach, duodenum (0.47 cm), small intestine (0.29 cm), ileo-cecal junction, and colon (0.1 cm) with no loss of layering, 1:3 muscularis to mucosa ratio, normal wall thickness and peristaltic activity, and no distension of the lumen. Fecal material is present within the colon.



## PATIENT

Annie Downs

## SPECIES

Canine

## BREED

Norfolk Terrier

## SEX

FS

## AGE

11 months

## WEIGHT

6 kg

## INTERPRETED BY

Remo Lobetti, BVSc,  
MMedVet (Med),  
PhD, Dipl. ECVIM

## IMAGING PERFORMED BY

Dr. Caroline Tan

## HOSPITAL NAME

Bowness Animal  
Hospital

## REFERRING VET

Dr. Satnam Dhothar

## INVOICE

11914

## DATE

5/8/2026

## Pancreas

Normal size and echogenic appearance. Regular capsule. Normal echogenic appearance of the mesentery and fat surrounding the pancreas.

## Free Abdomen

Normal mesenteric lymph nodes.

No ascites evident.

## ULTRASONOGRAPHIC FINDINGS

- Nodular hepatopathy.
- Urinary bladder sediment with uroliths.
- Gallbladder sediment with choleliths.

## INTERPRETATION OF THE FINDINGS & FURTHER RECOMMENDATIONS

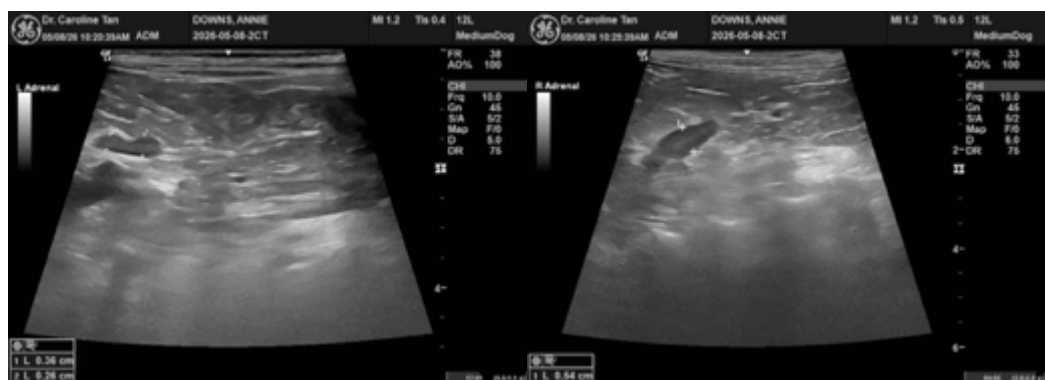
Etiologies for the nodular hepatopathy would be nodular hyperplasia, granulomatous disease, chronic active hepatitis, infiltrative neoplasia and possibly emerging hepatocutaneous syndrome.

The most likely etiology for the urinary bladder sediment would be incidental crystalluria with bacterial cystitis a possible differential diagnosis.

Both the gallbladder sediment and the choleliths can be considered incidental findings.

Further assessment would be urinalysis, possibly urine culture, and FNA cytology of the liver, a Tru-cut or wedge biopsy of the liver may however be required for a final etiological diagnosis.

Specific therapy would be dependent on an etiological diagnosis.





## PATIENT

Annie Downs

## SPECIES

Canine

## BREED

Norfolk Terrier

## SEX

FS

## AGE

11 months

## WEIGHT

6 kg

## INTERPRETED BY

Remo Lobetti, BVSc,  
MMedVet (Med),  
PhD, Dipl. ECVIM

## IMAGING PERFORMED BY

Dr. Caroline Tan

## HOSPITAL NAME

Bowness Animal  
Hospital

## REFERRING VET

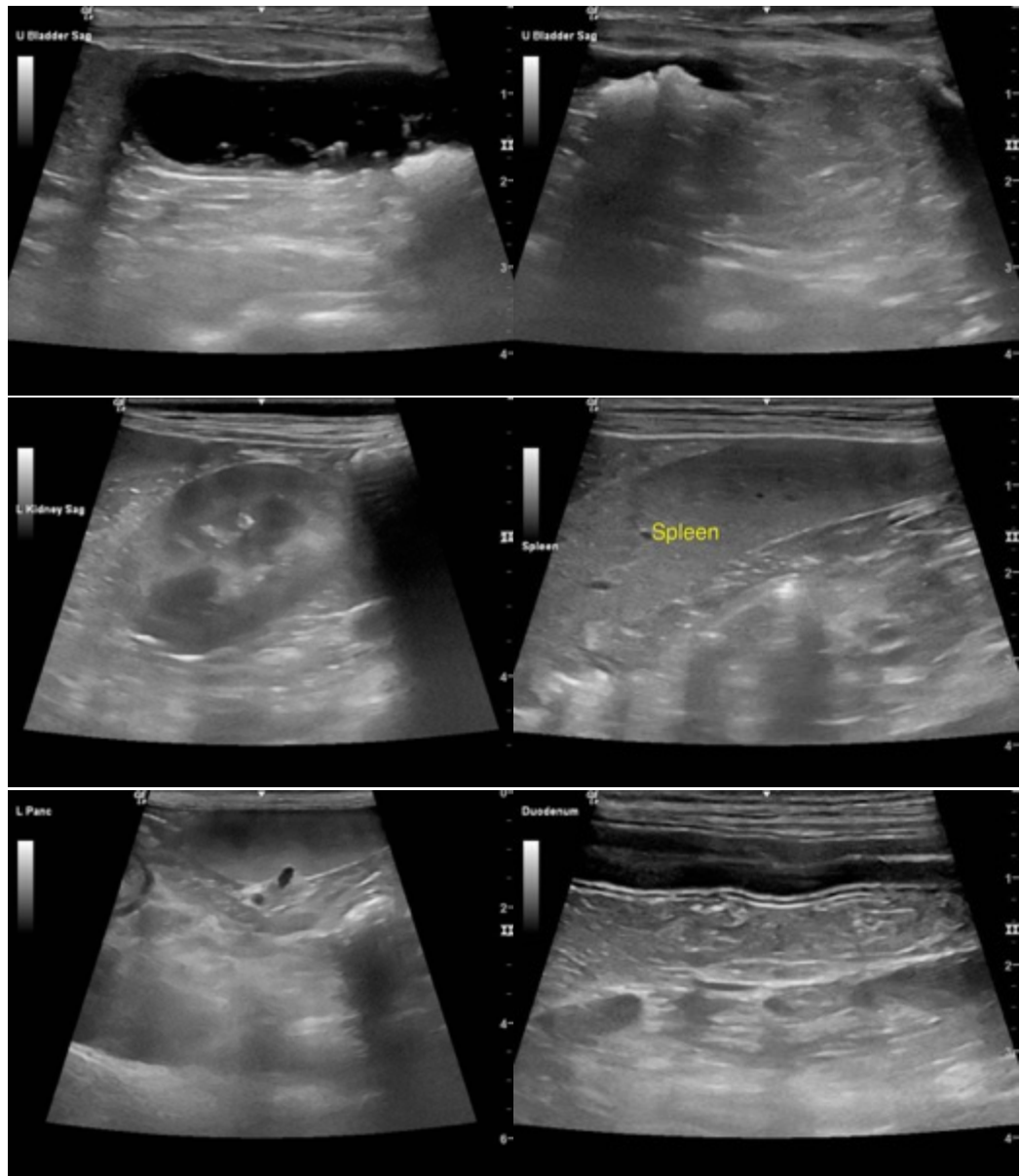
Dr. Satnam Dhothar

## INVOICE

11914

## DATE

5/8/2026





## PATIENT

Annie Downs

## SPECIES

Canine

## BREED

Norfolk Terrier

## SEX

FS

## AGE

11 months

## WEIGHT

6 kg

## INTERPRETED BY

Remo Lobetti, BVSc,  
MMedVet (Med),  
PhD, Dipl. ECVIM

## IMAGING PERFORMED BY

Dr. Caroline Tan

## HOSPITAL NAME

Bowness Animal  
Hospital

## REFERRING VET

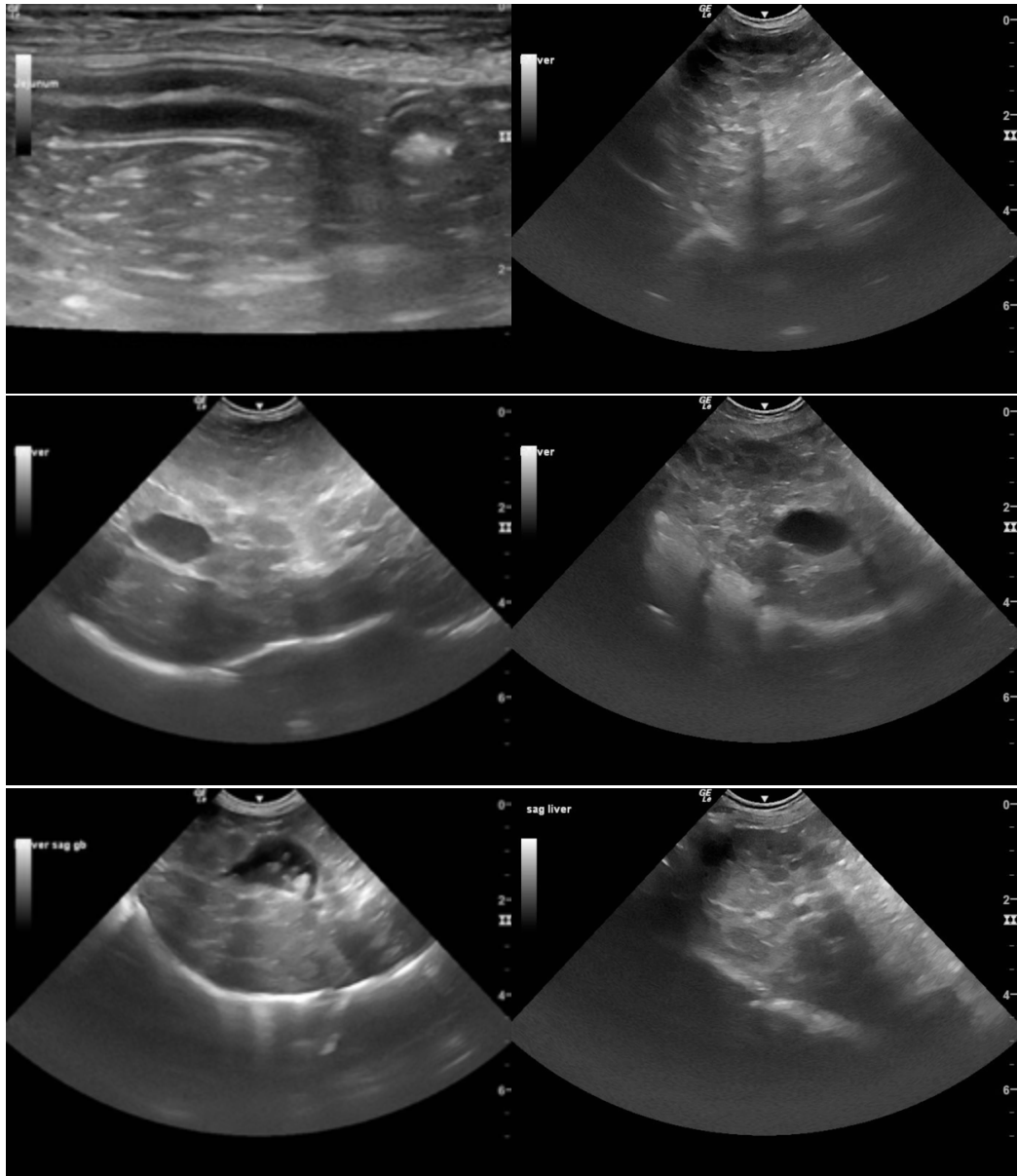
Dr. Satnam Dhothar

## INVOICE

11914

## DATE

5/8/2026



The information and recommendations provided are based on the images presented by the referring veterinarian. No evaluation can be communicated regarding pathology that was not visible in the image/video clips provided.

Thank you for this referral. If the clinical or image interpretation does not parallel your findings or if I can be of any further assistance, please contact me.

Remo Lobetti, BVSc, MMedVet (Med), PhD, Dipl. ECVIM (Internal Medicine)

[info@sonopath.com](mailto:info@sonopath.com)