



PATIENT

Phoebe Potts

SPECIES

Canine

BREED

Pomeranian

SEX

Spayed female

AGE

10 years

WEIGHT

8.8 lbs

INTERPRETED BY

Remo Lobetti, BVSc,
MMedVet (Med),
PhD, Dipl. ECVIM

IMAGING PERFORMED BY

Jenna Smith CVT

HOSPITAL NAME

Annville Cleona VA

REFERRING VET

Dr. Keck

INVOICE

75269

DATE

5/7/26

PRESENTING CLINICAL SIGNS

History: Owner declined recommended ultrasound in February. Rx. Denamarin started in March and Clavamox in January. May 5, 2026 seizures occurred and Phoebe presented to the emergency clinic and was prescribed Gabapentin and Methocarbamol for back pain. Suspect liver neoplasia.
Abnormal PE/Chem/CBC/UA Results: Elevated ALT since January 2026. January ALT=500 and February ALT = 700, and ALT = 659 in March.

ULTRASONOGRAPHIC EXAMINATION OF THE ABDOMEN

Urinary System

The urinary bladder is full with a normal thickness and smooth appearance of the wall. Normal anechoic urine with no sediment or uroliths evident.

Normal appearance of the trigone area, proximal urethra, and iliac blood vessels.

Normal appearance and size of the iliac lymph nodes. Ureters not visualized, which can be considered a normal finding.

Normal renal size (left measured 3.1 cm, right measured 3.4 cm), architecture, echogenic appearance, cortico-medullary differentiation, which maintains a 1:3 cortex to medulla ratio, pelvis, and capsule. No infarcts, mineralization or renoliths evident. Normal color flow pattern is noted in both kidneys.

Adrenal Glands

The right adrenal gland is normal in shape, echogenic appearance, size, position, and appearance of the visible peri-adrenal vasculature. Right adrenal gland measured 0.41 cm in width. The left adrenal gland was poorly visualized, but appears to be of normal shape, echogenic appearance and size.

Spleen

Normal size and echogenic appearance. Smooth homogenous parenchyma and regular curvilinear capsule. Normal volume of the splenic vasculature without any overt congestion or thrombosis evident. No inflammatory, neoplastic, infarction, or infiltrative changes evident. The spleen measured 0.8 cm in width.

Liver

Normal size with a diffuse, increased echogenic, coarse and nodular appearance, portal markings, and regular curvilinear capsule. Nodules are hypoechoic, parenchymal and measure up to 0.6 x 1.1 cm in size. No masses evident. Normal appearance of the hepatic and portal vasculature.



PATIENT

Phoebe Potts

SPECIES

Canine

BREED

Pomeranian

SEX

Spayed female

AGE

10 years

WEIGHT

8.8 lbs

INTERPRETED BY

Remo Lobetti, BVSc,
MMedVet (Med),
PhD, Dipl. ECVIM

IMAGING PERFORMED BY

Jenna Smith CVT

HOSPITAL NAME

Annville Cleona VA

REFERRING VET

Dr. Keck

INVOICE

75269

DATE

5/7/26

Gallbladder

The gallbladder is full containing normal anechoic bile. Normal thickness and echogenic appearance of the wall. Normal size and appearance of the cystic and common bile duct.

Gastrointestinal

Normal appearance of the stomach, duodenum, small intestine, ileo-cecal junction, and colon with no loss of layering, 1:3 muscularis to mucosa ratio, normal wall thickness and peristaltic activity, and no distension of the lumen.

Pancreas

The visible sections of the pancreas are of normal size and echogenic appearance with a regular capsule. Normal echogenic appearance of the mesentery and fat surrounding the pancreas.

Free Abdomen

Normal mesenteric lymph nodes.

No ascites evident.

ULTRASONOGRAPHIC FINDINGS

- Nodular hepatopathy.

INTERPRETATION OF THE FINDINGS & FURTHER RECOMMENDATIONS

Etiologies for the nodular hepatopathy would be nodular hyperplasia, chronic active hepatitis, granulomatous hepatitis and possibly neoplasia.

Further assessment would be FNA cytology of the liver. However, a tru cut or wedge biopsy may be required for a final etiological diagnosis.

Specific therapy would be dependent on an etiological diagnosis.

Symptomatic management that can be considered would be to continue with the current therapy and to add Ursodiol with regular monitoring of liver enzyme activity.



PATIENT

Phoebe Potts

SPECIES

Canine

BREED

Pomeranian

SEX

Spayed female

AGE

10 years

WEIGHT

8.8 lbs

INTERPRETED BY

Remo Lobetti, BVSc,
MMedVet (Med),
PhD, Dipl. ECVIM

IMAGING PERFORMED BY

Jenna Smith CVT

HOSPITAL NAME

Annville Cleona VA

REFERRING VET

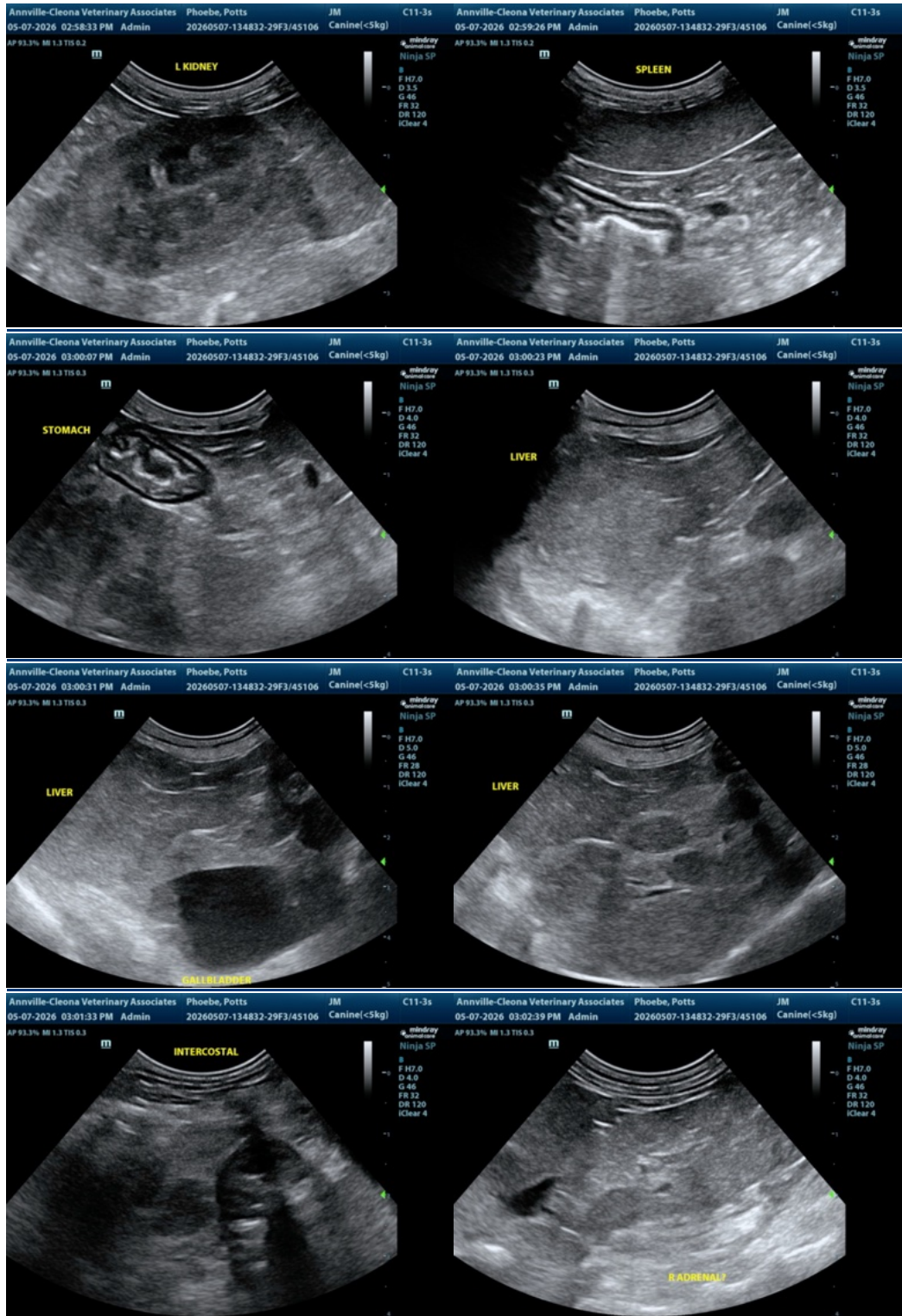
Dr. Keck

INVOICE

75269

DATE

5/7/26





PATIENT

Phoebe Potts

SPECIES

Canine

BREED

Pomeranian

SEX

Spayed female

AGE

10 years

WEIGHT

8.8 lbs

INTERPRETED BY

Remo Lobetti, BVSc,
MMedVet (Med),
PhD, Dipl. ECVIM

IMAGING PERFORMED BY

Jenna Smith CVT

HOSPITAL NAME

Annville Cleona VA

REFERRING VET

Dr. Keck

INVOICE

75269

DATE

5/7/26

The information and recommendations provided are based on the images presented by the referring veterinarian/sonographer. No evaluation can be communicated regarding pathology that was not visible in the image/video clips provided.

Thank you for this referral. If the clinical or image interpretation does not parallel your findings or if I can be of any further assistance please contact me.

Remo Lobetti, BVSc, MMedVet (Med), PhD, Dipl. ECVIM (Internal Medicine)

info@sonopath.com