



PATIENT

Lilli Buchanan

SPECIES

Canine

BREED

Chihuahua

SEX

FS

AGE

16 years

WEIGHT

5.1 lbs

INTERPRETED BY

Remo Lobetti, BVSc,
MMedVet (Med),
PhD, Dipl. ECVIM

IMAGING PERFORMED BY

Dr. Danielle Shemanski

HOSPITAL NAME

Western New York
Veterinary Services

REFERRING VET

Dr. Brenda Buck

INVOICE

11896

DATE

5/6/2026

PRESENTING CLINICAL SIGNS

Frequent urination accidents. O reported on 5/6 that P vomited a few times and stool was more loose than normal History: Urinating more often, like every 3 hours. Still having accidents in the house. She urinated in her bed when sleeping on Tuesday. Owner notes that the patient's urine smells odd. Urinalysis taken on April 30, 2026 showed significant nonhyaline casts and Ddx include significant tubular injury but may also be potentially inappropriate concentration only. Urine monitoring recommended for persistence of casts.

CLINICAL SIGNS: Frequent urination.

MEDICATIONS: Clindamycin 25mg 1/2 tab BID for 7 days, repeat one week each month.

Abnormal PE/Chem/CBC/UA Results: April 30, 2026 Blood Chemistry: WNL Urinalysis: Normal, other than significant non-hyaline casts (>1/LPF)

ULTRASONOGRAPHIC EXAMINATION OF THE ABDOMEN

Urinary System

Small urinary bladder with a normal thickness and smooth appearance of the wall. Normal anechoic urine with no sediment or uroliths evident.

Normal appearance of the trigone area, proximal urethra, and iliac blood vessels.

Normal appearance and size of the iliac lymph nodes. Ureters not visualized, which can be considered a normal finding.

Normal renal size (left 3.4 cm, right 3.0 cm), with increased echogenic appearance, some loss of cortico-medullary differentiation, and normal pelvis, and capsule. No infarcts, mineralization or renoliths evident.

Adrenal Glands

Normal shape, echogenic appearance, size, position, and appearance of the visible peri-adrenal vasculature.

Left adrenal measures 1.36 cm in length x 0.42 cm and 0.52 cm in width. The right adrenal measures 2.1 cm in length x 0.56 cm and 0.63 cm in width.

Spleen

Normal size and echogenic appearance. Smooth homogenous parenchyma and regular curvilinear capsule. Normal volume of the splenic vasculature without any overt congestion or thrombosis evident. No inflammatory, neoplastic, infarction, or infiltrative changes evident. The spleen measures 0.7 cm in width.

Liver

Normal size, echogenic appearance, portal markings, and regular curvilinear capsule. No nodules or masses evident. Normal appearance of the hepatic and portal vasculature.

Gallbladder



PATIENT

Lilli Buchanan

SPECIES

Canine

BREED

Chihuahua

SEX

FS

AGE

16 years

WEIGHT

5.1 lbs

Full containing normal anechoic bile. Normal thickness and echogenic appearance of the wall. Normal size and appearance of the cystic and common bile duct.

Gastrointestinal

Normal appearance of the stomach, duodenum, small intestine, ileo-cecal junction, and colon with no loss of layering, 1:3 muscularis to mucosa ratio, normal wall thickness and peristaltic activity, and no distension of the lumen. Small amount of ingesta present within the stomach.

Pancreas

Normal size and echogenic appearance. Regular capsule. Normal echogenic appearance of the mesentery and fat surrounding the pancreas.

Free Abdomen

Normal mesenteric lymph nodes.

No ascites evident.

Thorax

Normal appearance of the heart. No pleural or pericardial effusion evident.

ULTRASONOGRAPHIC FINDINGS

- Age related renal changes versus early chronic kidney disease.

INTERPRETATION OF THE FINDINGS & FURTHER RECOMMENDATIONS

In essence, a normal ultrasound examination of the abdomen.

INTERPRETED BY

Remo Lobetti, BVSc,
MMedVet (Med),
PhD, Dipl. ECVIM

IMAGING PERFORMED BY

Dr. Danielle Shemanski

HOSPITAL NAME

Western New York
Veterinary Services

REFERRING VET

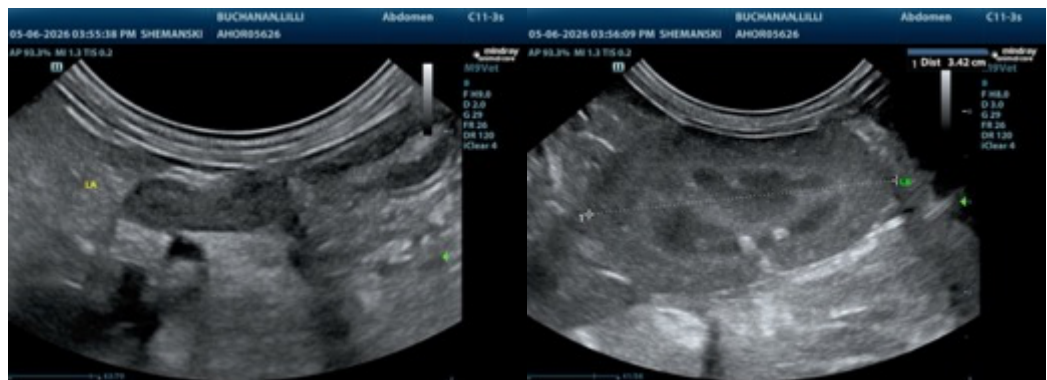Dr. Brenda Buck

INVOICE

11896

DATE

5/6/2026





PATIENT

Lilli Buchanan

SPECIES

Canine

BREED

Chihuahua

SEX

FS

AGE

16 years

WEIGHT

5.1 lbs

INTERPRETED BY

Remo Lobetti, BVSc,
MMedVet (Med),
PhD, Dipl. ECVIM

IMAGING PERFORMED BY

Dr. Danielle Shemanski

HOSPITAL NAME

Western New York
Veterinary Services

REFERRING VET

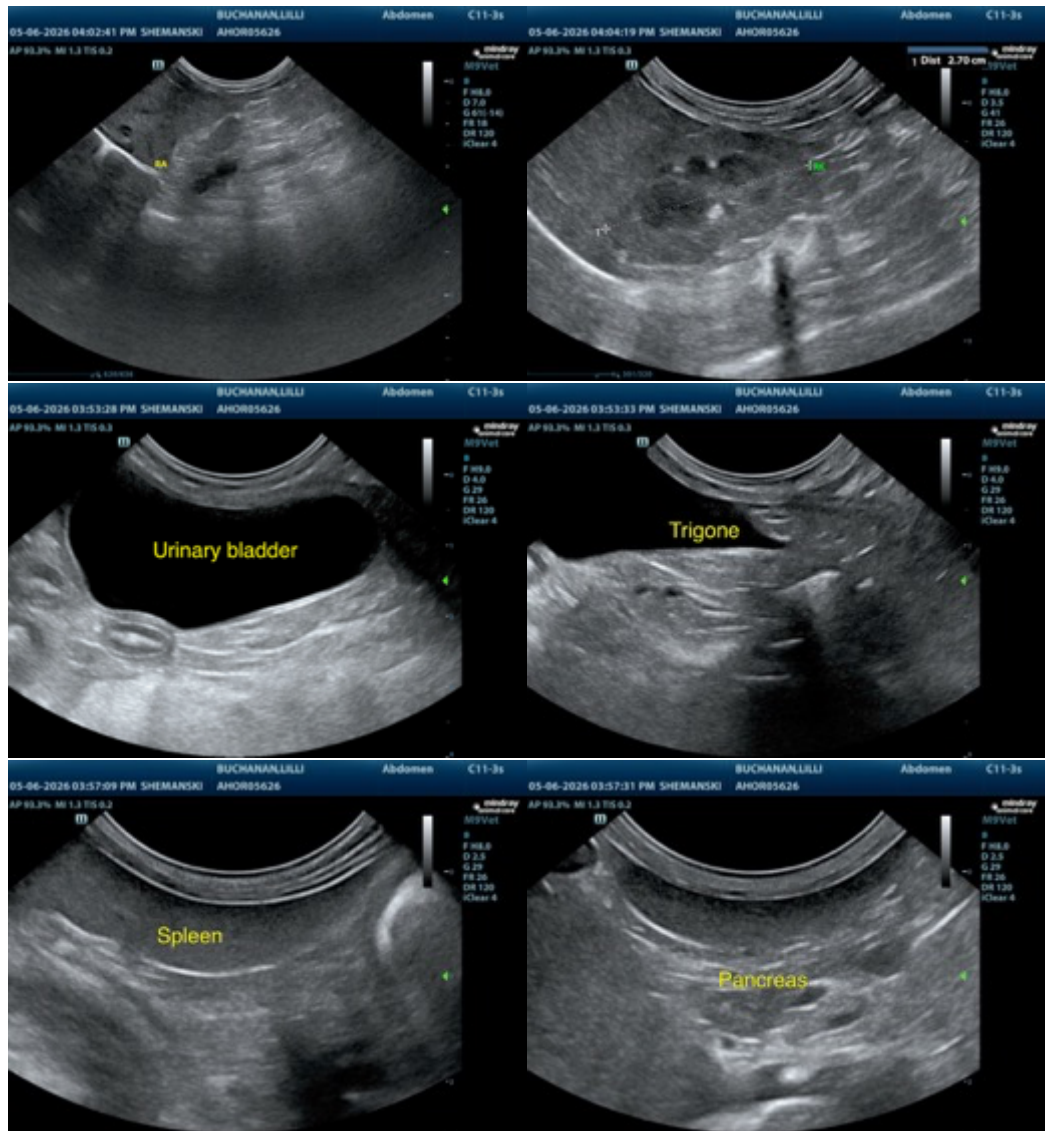
Dr. Brenda Buck

INVOICE

11896

DATE

5/6/2026





PATIENT

Lilli Buchanan

SPECIES

Canine

BREED

Chihuahua

SEX

FS

AGE

16 years

WEIGHT

5.1 lbs

INTERPRETED BY

Remo Lobetti, BVSc,
MMedVet (Med),
PhD, Dipl. ECVIM

IMAGING PERFORMED BY

Dr. Danielle Shemanski

HOSPITAL NAME

Western New York
Veterinary Services

REFERRING VET

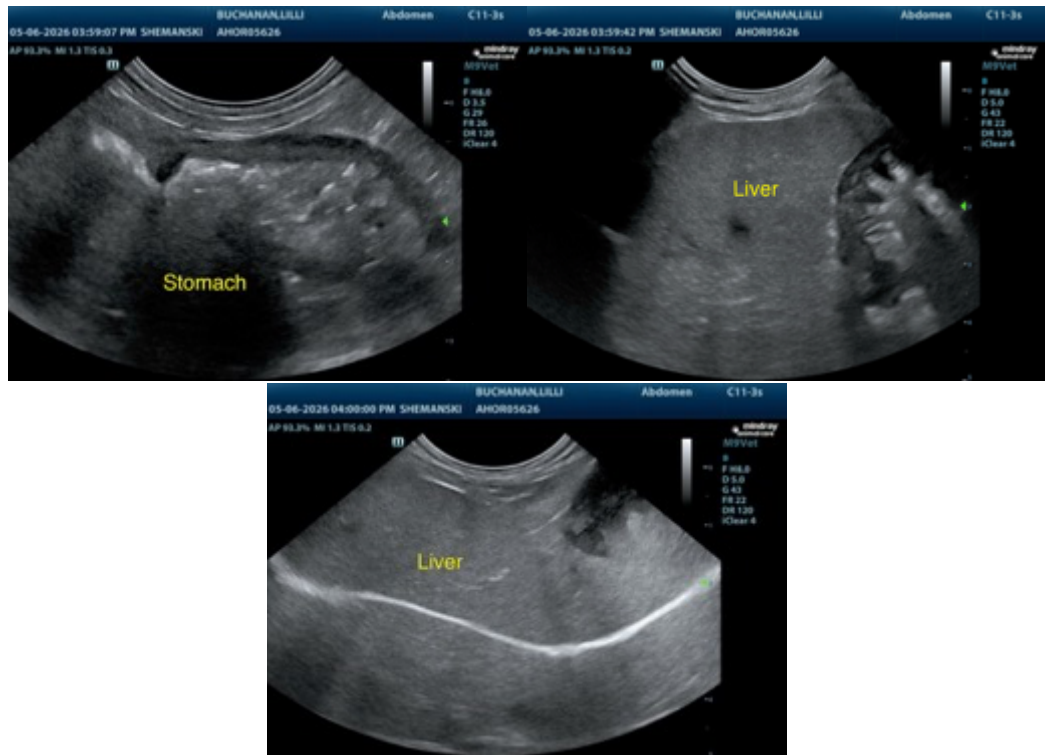
Dr. Brenda Buck

INVOICE

11896

DATE

5/6/2026



The information and recommendations provided are based on the images presented by the referring veterinarian. No evaluation can be communicated regarding pathology that was not visible in the image/video clips provided.

Thank you for this referral. If the clinical or image interpretation does not parallel your findings or if I can be of any further assistance, please contact me.

Remo Lobetti, BVSc, MMedVet (Med), PhD, Dipl. ECVIM (Internal Medicine)

info@sonopath.com