

PATIENT

Meeshe Mercado

SPECIES

Feline

BREED

Persian

SEX

Neutered male

AGE

1 year

WEIGHT

8.4 lbs

INTERPRETED BY

Remo Lobetti, BVSc,
MMedVet (Med), PhD,
Dipl. ECVIM (Internal
Medicine)

IMAGING PERFORMED BY

Denise Bruno, LVT,
RDMS

HOSPITAL NAME

House Call

REFERRING VET

Dr. Shieh

INVOICE

75228

DATE

5/5/26

PRESENTING CLINICAL SIGNS

History: Big belly - suspect FIP vs hernia. Discharge report attached

ULTRASONOGRAPHIC EXAMINATION OF THE ABDOMEN

Urinary System

The urinary bladder is full with a normal thickness and smooth appearance of the wall. Normal anechoic urine with no sediment or uroliths evident.

Normal appearance of the trigone area, proximal urethra, and iliac blood vessels.

Normal appearance and size of the iliac lymph nodes. Ureters not visualized, which can be considered a normal finding.

Normal renal size, architecture, echogenic appearance, cortico-medullary differentiation, which maintains a 1:3 cortex to medulla ratio, pelvis, and capsule. No infarcts or renoliths evident. Focal mineralization is evident in the right kidney. A few, small, incidental cortical cysts are present in both kidneys. The left kidney measured 4.0 cm. The right kidney measured 4.2 cm. Normal color flow pattern is evident in both kidneys.

Adrenal Glands

Normal shape, echogenic appearance, size, position, and appearance of the visible peri-adrenal vasculature. The left adrenal gland measured 1.1 cm in length x 0.47 cm in width. The right adrenal gland measured 1.04 cm in length x 0.32 cm in width.

Spleen

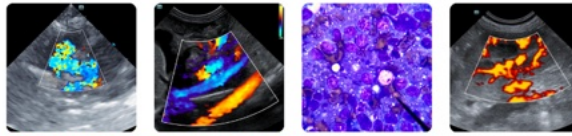
Normal size and echogenic appearance. Smooth homogenous parenchyma and regular curvilinear capsule. Normal volume of the splenic vasculature without any overt congestion or thrombosis evident. No inflammatory, neoplastic, infarction, or infiltrative changes evident. The spleen measured 0.7 cm in width.

Liver

Normal size, echogenic appearance, portal markings, and regular curvilinear capsule. No nodules or masses evident. Normal appearance of the hepatic and portal vasculature.

Gallbladder

The gallbladder is full containing a small amount of non-adhered, hyperechogenic sediment. Normal thickness and echogenic appearance of the wall. Normal size and appearance of the cystic and common bile duct.



PATIENT

Meeshe Mercado

SPECIES

Feline

BREED

Persian

SEX

Neutered male

AGE

1 year

WEIGHT

8.4 lbs

INTERPRETED BY

Remo Lobetti, BVSc,
MMedVet (Med), PhD,
Dipl. ECVIM (Internal
Medicine)

**IMAGING
PERFORMED BY**

Denise Bruno, LVT,
RDMS

HOSPITAL NAME

House Call

REFERRING VET

Dr. Shieh

INVOICE

75228

DATE

5/5/26

Gastrointestinal

Normal appearance of the stomach, duodenum, small intestine, ileo-cecal junction, and colon with no loss of layering, 1:3 muscularis to mucosa ratio, normal wall thickness and peristaltic activity, and no distension of the lumen. A moderate amount of ingesta is present in the stomach compatible with a recent meal. The small intestine measured 0.25 cm.

Pancreas

The visible sections of the pancreas are of normal size and echogenic appearance with a regular capsule. Normal echogenic appearance of the mesentery and fat surrounding the pancreas.

Free Abdomen

Focal, enlarged mesenteric lymph node measuring 1.2 x 1.6 cm in size with a hyperechogenic appearance, rounded shape and few, hypoechogenic nodules. The rest of the mesenteric lymph nodes are of normal size and appearance.

A large amount of cellular ascites is present.

Small, incidental, umbilical hernia is present with no abnormal content present.

ULTRASONOGRAPHIC FINDINGS

- Ascites.
- Focal mesenteric lymphadenomegaly.
- Gallbladder sediment.

INTERPRETATION OF THE FINDINGS & FURTHER RECOMMENDATIONS

The renal cysts and mineralization. Can be considered incidental findings.

Etiologies for the focal lymphadenomegaly would be lymphadenitis and possibly infiltrative neoplasia.

The gallbladder sediment can be considered an incidental finding.

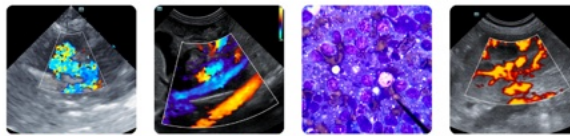
Further assessment would be three view thoracic radiographs, analysis of the ascitic fluid and FNA cytology of the focal, mesenteric lymphadenomegaly.

Specific therapy would be dependent on an etiological diagnosis.

Imaging performed by



dbimaginesound@gmail.com
917-647-4318



Clinical Sonography & Telectylogy
Educational Teleconsultation Services™

SonoPath

FOSTERING THE ART OF VETERINARY MEDICINE™

SonoPath.com info@sonopath.com 1.800.838.4268

PATIENT

Meeshe Mercado

SPECIES

Feline

BREED

Persian

SEX

Neutered male

AGE

1 year

WEIGHT

8.4 lbs

INTERPRETED BY

Remo Lobetti, BVSc,
MMedVet (Med), PhD,
Dipl. ECVIM (Internal
Medicine)

IMAGING PERFORMED BY

Denise Bruno, LVT,
RDMS

HOSPITAL NAME

House Call

REFERRING VET

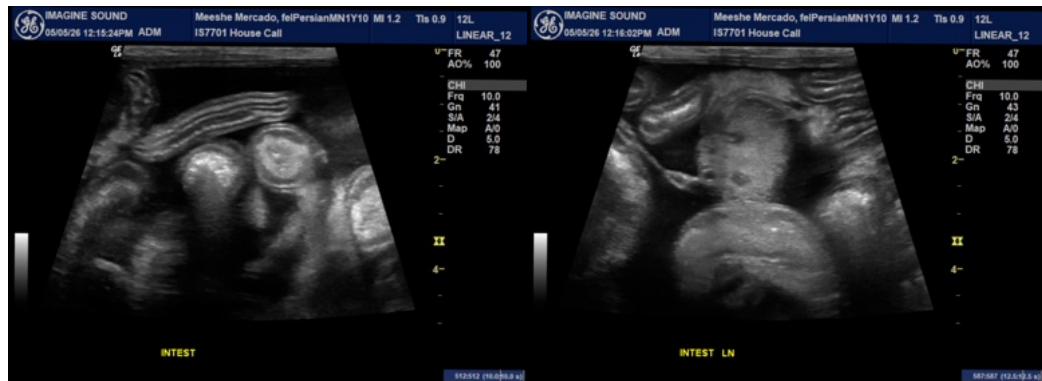
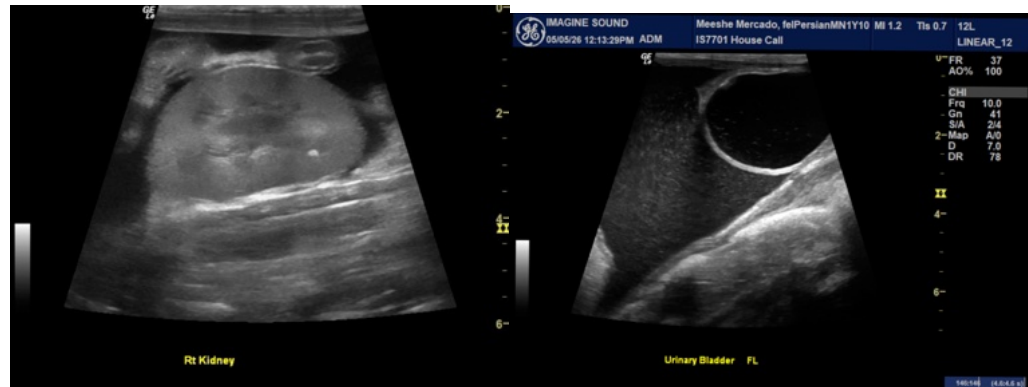
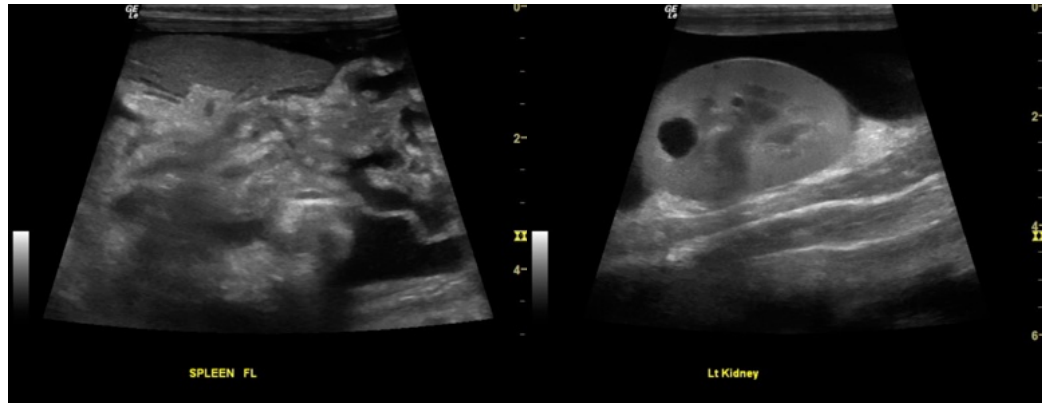
Dr. Shieh

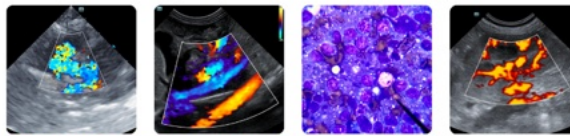
INVOICE

75228

DATE

5/5/26





PATIENT

Meeshe Mercado

SPECIES

Feline

BREED

Persian

SEX

Neutered male

AGE

1 year

WEIGHT

8.4 lbs

INTERPRETED BY

Remo Lobetti, BVSc, MMedVet (Med), PhD, Dipl. ECVIM (Internal Medicine)

IMAGING PERFORMED BY

Denise Bruno, LVT, RDMS

HOSPITAL NAME

House Call

REFERRING VET

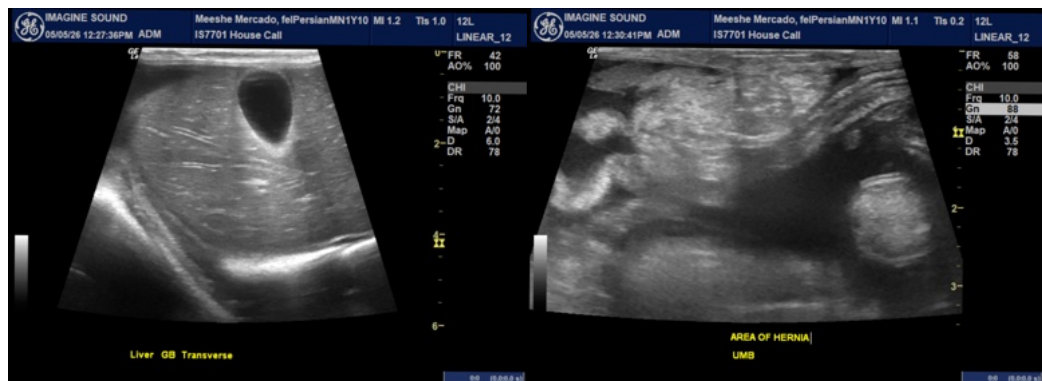
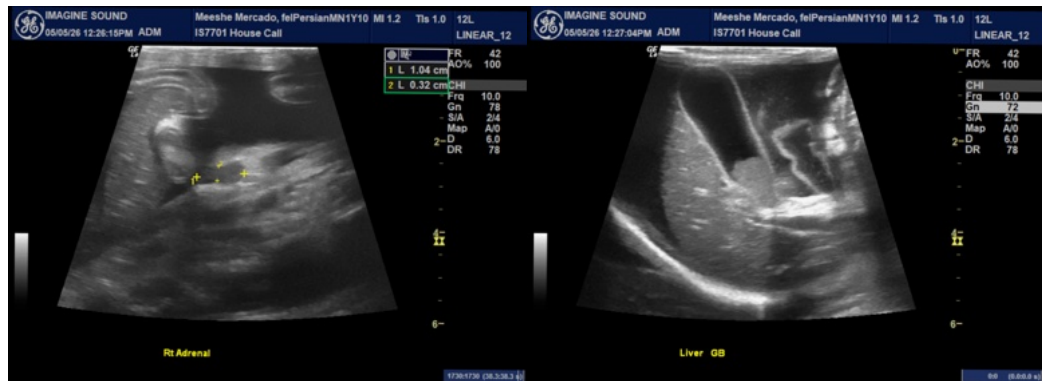
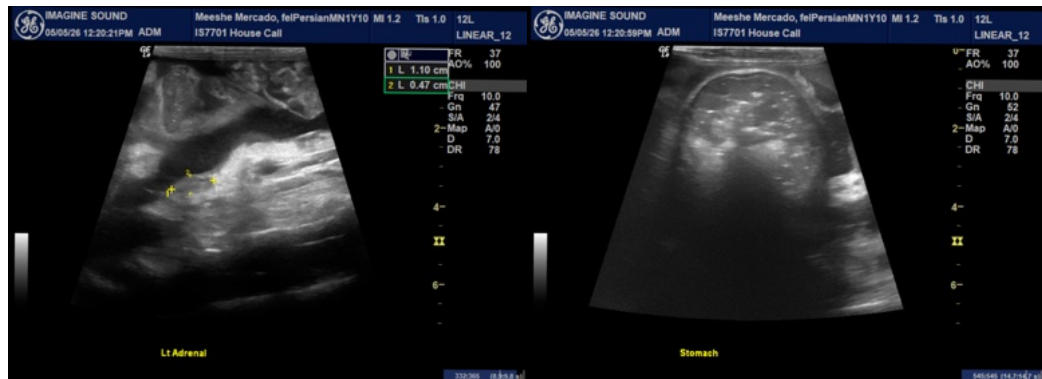
Dr. Shieh

INVOICE

75228

DATE

5/5/26



The information and recommendations provided are based on the images presented by the referring veterinarian/sonographer. No evaluation can be communicated regarding pathology that was not visible in the image/video clips provided.

Thank you for this referral. If the clinical or image interpretation does not parallel your findings or if I can be of any further assistance please contact me.

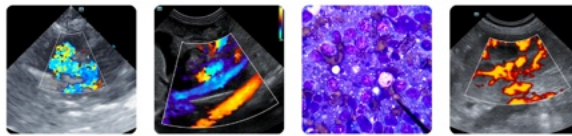
Remo Lobetti, BVSc, MMedVet (Med), PhD, Dipl. ECVIM (Internal Medicine)

info@sonopath.com

Imaging
performed by



dbimagesound@gmail.com
917-647-4318



Clinical Sonography & Telectology
Educational Teleconsultation Services™

SonoPath

FOSTERING THE ART OF VETERINARY MEDICINE™

SonoPath.com info@sonopath.com 1.800.838.4268

PATIENT

Meeshe Mercado

SPECIES

Feline

BREED

Persian

SEX

Neutered male

AGE

1 year

WEIGHT

8.4 lbs

INTERPRETED BY

Remo Lobetti, BVSc,
MMedVet (Med), PhD,
Dipl. ECVIM (Internal
Medicine)

**IMAGING
PERFORMED BY**

Denise Bruno, LVT,
RDMS

HOSPITAL NAME

House Call

REFERRING VET

Dr. Shieh

INVOICE

75228

DATE

5/5/26