



PATIENT

Meeka Gavin

SPECIES

Canine

BREED

Husky Mix

SEX

Spayed female

AGE

11 years

WEIGHT

25.9 kg

INTERPRETED BY

Remo Lobetti, BVSc,
MMedVet (Med),
PhD, Dipl. ECVIM

IMAGING PERFORMED BY

Dr. Caroline Tan

HOSPITAL NAME

Fen Vet Airdrie

REFERRING VET

Dr. Creelman

INVOICE

75163

DATE

5/4/26

PRESENTING CLINICAL SIGNS

History: Chronic clinical signs including intermittent inappetence, persistent soft stools, urinary changes, and suspected pain that have not resolved after a previous workup. No change during a brief trial of onsiar. She noted that Meeka has been lethargic, often just laying by the front door and not moving much. Her appetite has also remained picky, with some days where she shows no interest in her food for hours or goes the entire day without eating. - Interestingly, Kylie felt that Meeka's urinary urgency seemed to increase while on Onsiar, describing her as needing to "freak out and want to go outside quite a lot." No reports of V

Abnormal PE/Chem/CBC/UA Results: Labs pending.

ULTRASONOGRAPHIC EXAMINATION OF THE ABDOMEN

Urinary System

The urinary bladder is small with a normal thickness and smooth appearance of the wall. A scant amount of floating, hyperechogenic sediment.

Normal appearance of the trigone area, proximal urethra, and iliac blood vessels.

Normal appearance and size of the iliac lymph nodes. Ureters not visualized, which can be considered a normal finding.

Normal renal size (left measured 7.0 cm, right measured 6.6 cm), architecture, echogenic appearance, cortico-medullary differentiation, which maintains a 1:3 cortex to medulla ratio, pelvis, and capsule. No infarcts, mineralization or renoliths evident.

Adrenal Glands

Normal shape, echogenic appearance, size, position, and appearance of the visible peri-adrenal vasculature. Left adrenal gland measured 0.38 cm and 0.37 cm in width. The right adrenal gland measured 0.37 cm and 0.47 cm in width.

Spleen

Normal size and echogenic appearance. Smooth homogenous parenchyma and regular curvilinear capsule. Normal volume of the splenic vasculature without any overt congestion or thrombosis evident. No inflammatory, neoplastic, infarction, or infiltrative changes evident. The spleen measured 1.8 cm in width.

Liver

Normal size, echogenic appearance, portal markings, and regular curvilinear capsule. No nodules or masses evident. Normal appearance of the hepatic and portal vasculature.



PATIENT

Gallbladder

Meeka Gavin

The gallbladder is full containing normal anechoic bile. Normal thickness and echogenic appearance of the wall. Normal size and appearance of the cystic and common bile duct.

SPECIES

Canine

Gastrointestinal

BREED

Husky Mix

Normal appearance of the stomach, duodenum, small intestine, ileo-cecal junction, and colon with no loss of layering, 1:3 muscularis to mucosa ratio, normal wall thickness and peristaltic activity, and no distension of the lumen. The duodenum measured 0.47 cm, small intestine measured 0.44 cm.

SEX

Spayed female

Pancreas

AGE

11 years

The visible sections of the pancreas are of normal size and echogenic appearance with a regular capsule. Normal echogenic appearance of the mesentery and fat surrounding the pancreas.

WEIGHT

25.9 kg

Free Abdomen

Normal mesenteric lymph nodes.

INTERPRETED BY

No ascites evident.

Remo Lobetti, BVSc,
MMedVet (Med),
PhD, Dipl. ECVIM

ULTRASONOGRAPHIC FINDINGS

- Normal ultrasound examination of the abdomen.

IMAGING PERFORMED BY

INTERPRETATION OF THE FINDINGS & FURTHER RECOMMENDATIONS

Dr. Caroline Tan

On this ultrasound there is no obvious etiology for the presenting clinical signs.

HOSPITAL NAME

Fen Vet Airdrie

Further assessment and therapy would be based on the pending urinalysis, urine culture and blood work results.

REFERRING VET

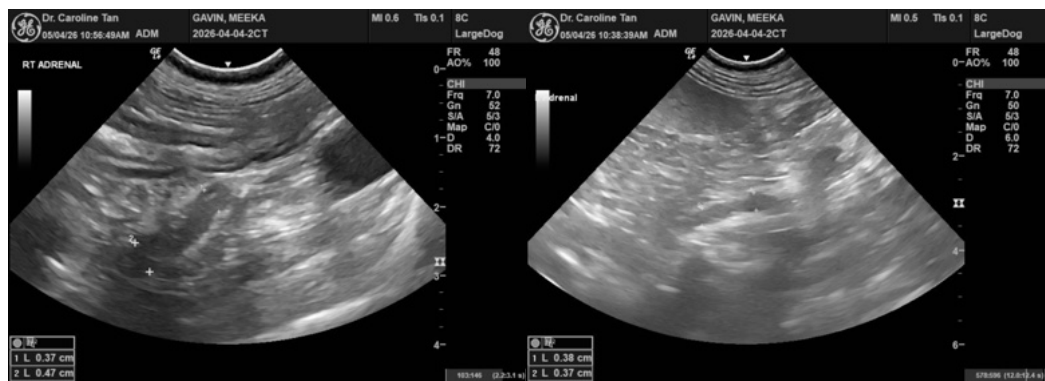
Dr. Creelman

INVOICE

75163

DATE

5/4/26





PATIENT

Meeka Gavin

SPECIES

Canine

BREED

Husky Mix

SEX

Spayed female

AGE

11 years

WEIGHT

25.9 kg

INTERPRETED BY

Remo Lobetti, BVSc,
MMedVet (Med),
PhD, Dipl. ECVIM

IMAGING PERFORMED BY

Dr. Caroline Tan

HOSPITAL NAME

Fen Vet Airdrie

REFERRING VET

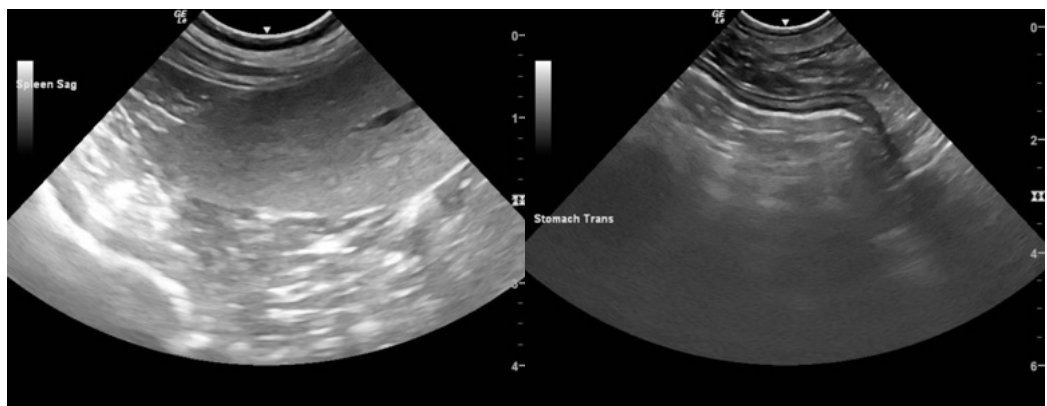
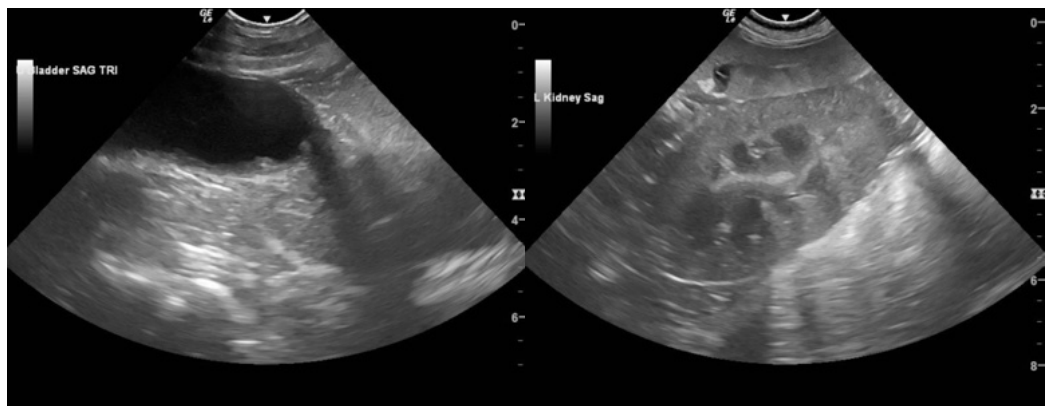
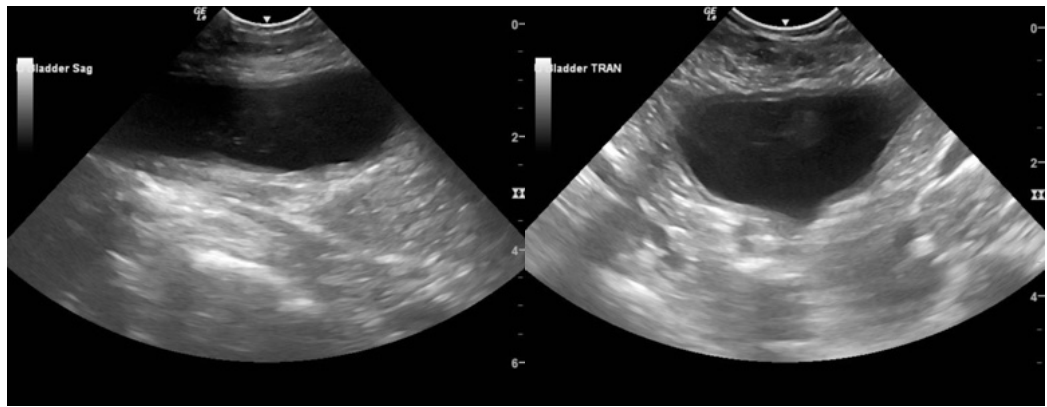
Dr. Creelman

INVOICE

75163

DATE

5/4/26





PATIENT

Meeka Gavin

SPECIES

Canine

BREED

Husky Mix

SEX

Spayed female

AGE

11 years

WEIGHT

25.9 kg

INTERPRETED BY

Remo Lobetti, BVSc,
MMedVet (Med),
PhD, Dipl. ECVIM

IMAGING PERFORMED BY

Dr. Caroline Tan

HOSPITAL NAME

Fen Vet Airdrie

REFERRING VET

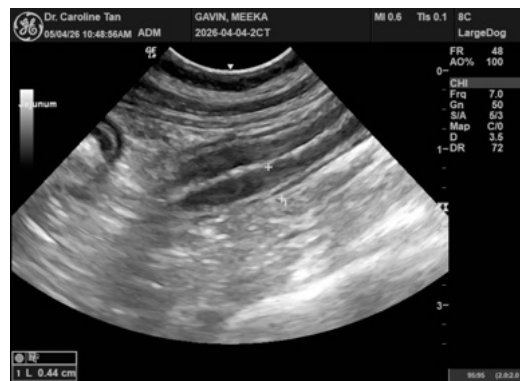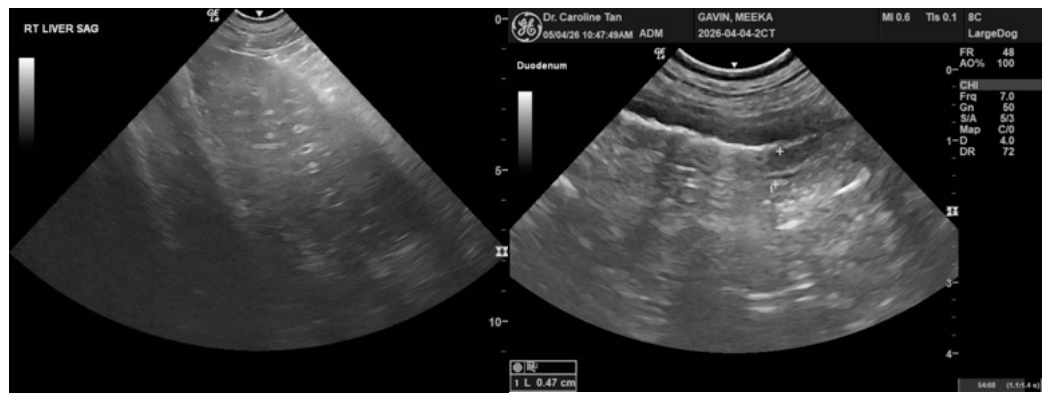
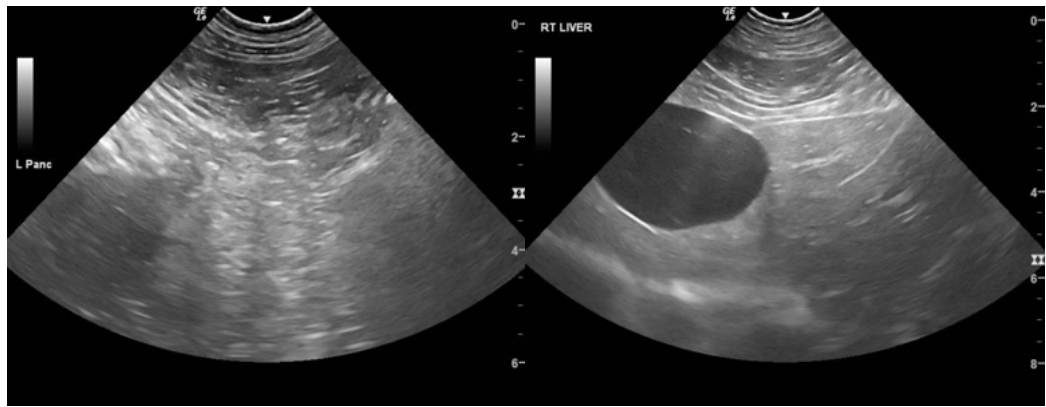
Dr. Creelman

INVOICE

75163

DATE

5/4/26



The information and recommendations provided are based on the images presented by the referring veterinarian/sonographer. No evaluation can be communicated regarding pathology that was not visible in the image/video clips provided.

Thank you for this referral. If the clinical or image interpretation does not parallel your findings or if I can be of any further assistance please contact me.

Remo Lobetti, BVSc, MMedVet (Med), PhD, Dipl. ECVIM (Internal Medicine)

info@sonopath.com