



PATIENT

Charlie Stalonas

SPECIES

Canine

BREED

Mixed

SEX

Neutered Male

AGE

9 Years

WEIGHT

54.6

INTERPRETED BY

Remo Lobetti, BVSc,
MMedVet (Med),
PhD, Dipl. ECVIM

IMAGING PERFORMED BY

Dr. Klein

HOSPITAL NAME

Alison Animal Hospital

REFERRING VET

Dr. Kleikn

INVOICE

75564

DATE

5/30/26

PRESENTING CLINICAL SIGNS

Pt is presented for AUS to monitor a splenic mass that was first diagnosed at a previous vet approx 4 years ago. Normal CBC. Chem WNL with the exception of a slightly elevated ALT 239 (WNL 18-121), GGT 18 (WNL 0-13) No C/S/V/D. Please compare this scan to that attached prior scan.

ULTRASONOGRAPHIC EXAMINATION OF THE ABDOMEN

Urinary System

Small urinary bladder with a normal thickness and smooth appearance of the wall. Normal anechoic urine with no sediment or uroliths evident.

Normal appearance of the trigone area, proximal urethra, and iliac blood vessels.

Normal appearance and size of the iliac lymph nodes. Ureters not visualized, which can be considered a normal finding.

Normal renal size, architecture, echogenic appearance, cortico-medullary differentiation, which maintains a 1:3 cortex to medulla ratio, pelvis, and capsule. No infarcts, mineralization or renoliths evident. Left kidney measured 6.1 cm. Right kidney measured 6.4 cm. Normal color flow pattern evident in both kidneys.

Reproductive System

Small, hypoechogenic prostate.

Adrenal Glands

Not visualized.

Spleen

Normal size (2.0 cm in width) and echogenic appearance. Smooth homogenous parenchyma and regular curvilinear capsule. Normal volume of the splenic vasculature without any overt congestion or thrombosis evident. A focal hyperechogenic parenchymal nodule is noted in the body of the spleen, measuring approximately 0.80 cm in size.

Liver

Normal size, echogenic appearance, portal markings, and regular curvilinear capsule. No nodules or masses evident. Normal appearance of the hepatic and portal vasculature.

Gallbladder

Full containing a small amount of non-adhered hyperechogenic sediment. Normal thickness and echogenic appearance of the wall. Normal size and appearance of the cystic and common bile duct.

Gastrointestinal

Normal appearance of the stomach, duodenum, small intestine, ileo-cecal junction, and colon with no loss of layering, 1:3 muscularis to mucosa ratio, normal wall thickness and peristaltic activity, and no distension of the lumen.



PATIENT

Charlie Stalonas

SPECIES

Canine

BREED

Mixed

SEX

Neutered Male

AGE

9 Years

WEIGHT

54.6

INTERPRETED BY

Remo Lobetti, BVSc,
MMedVet (Med),
PhD, Dipl. ECVIM

IMAGING PERFORMED BY

Dr. Klein

HOSPITAL NAME

Alison Animal Hospital

REFERRING VET

Dr. Kleikn

INVOICE

75564

DATE

5/30/26

Pancreas

Visible sections present normal size and echogenic appearance. Regular capsule. Normal echogenic appearance of the mesentery and fat surrounding the pancreas.

Free Abdomen

Normal mesenteric lymph nodes.

No ascites evident.

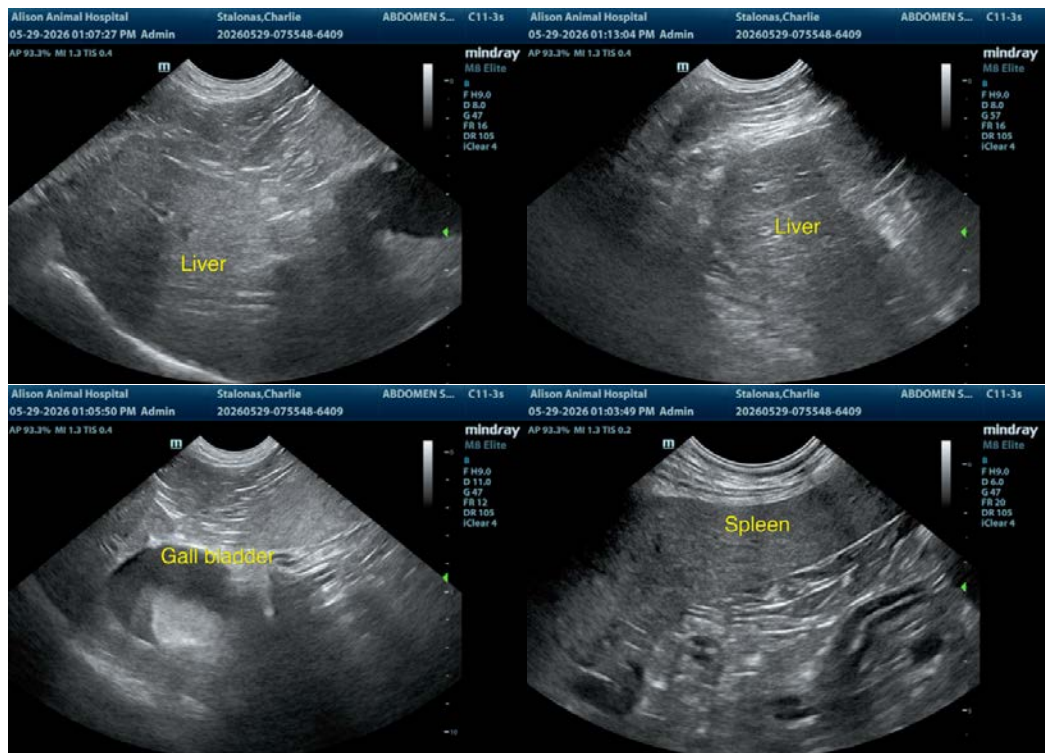
ULTRASONOGRAPHIC FINDINGS

- Splenic nodule.
- Gallbladder sediment.

INTERPRETATION OF THE FINDINGS & FURTHER RECOMMENDATIONS

In essence this is a normal ultrasound examination of the abdomen, as the splenic nodule can be considered an incidental finding, most likely represent either an organized hematoma or granuloma.

The previously reported hepatic nodule was not evident on this ultrasound.





PATIENT

Charlie Stalonas

SPECIES

Canine

BREED

Mixed

SEX

Neutered Male

AGE

9 Years

WEIGHT

54.6

INTERPRETED BY

Remo Lobetti, BVSc,
MMedVet (Med),
PhD, Dipl. ECVIM

IMAGING PERFORMED BY

Dr. Klein

HOSPITAL NAME

Alison Animal Hospital

REFERRING VET

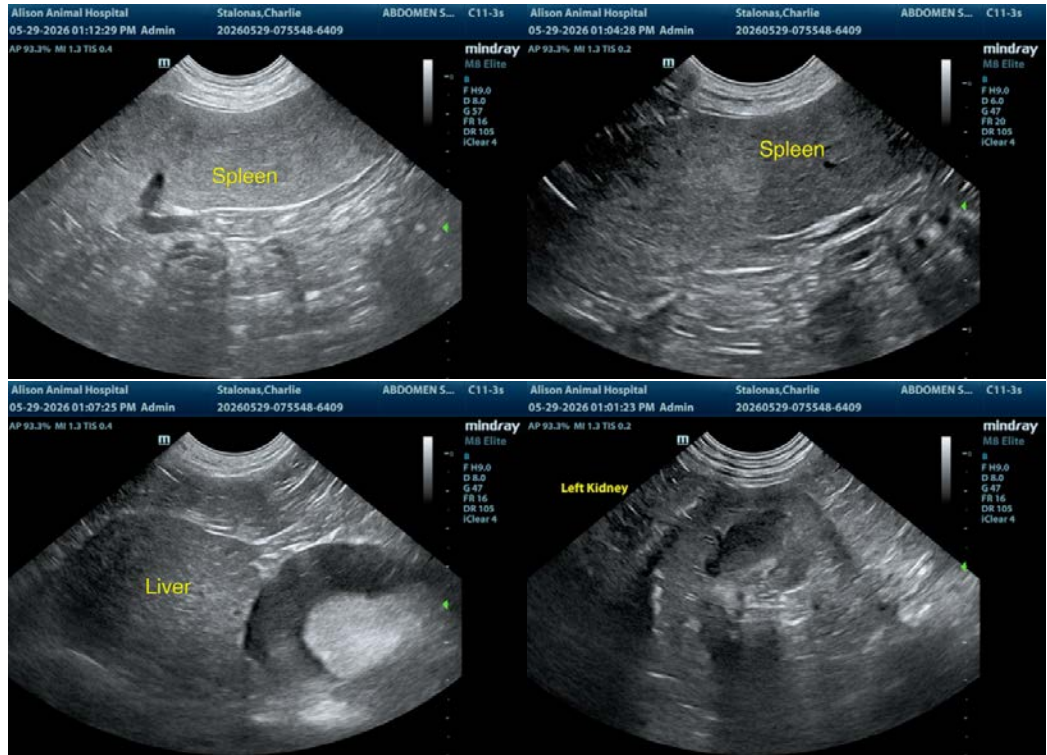
Dr. Kleikn

INVOICE

75564

DATE

5/30/26



The information and recommendations provided are based on the images presented by the referring veterinarian. No evaluation can be communicated regarding pathology that was not visible in the image/video clips provided.

Thank you for this referral. If the clinical or image interpretation does not parallel your findings or if I can be of any further assistance, please contact me.

Remo Lobetti, BVSc, MMedVet (Med), PhD, Dipl. ECVIM (Internal Medicine)

info@sonopath.com