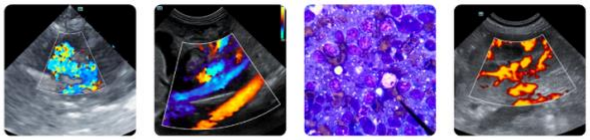

PATIENT
Hercules Desousa

SPECIES
Canine

BREED
Great Dane

SEX
Neutered Male

AGE
7 Years 6 Months

WEIGHT
153 Pounds

INTERPRETED BY
Remo Lobetti BVSc, MMedVet, PhD, DECVIM

IMAGING PERFORMED BY
Dr. Paul Kim

HOSPITAL NAME
Ridgefield Park AH

REFERRING VET
Dr. Daniel Dima

INVOICE
37268

DATE
5/28/26

PRESENTING CLINICAL SIGNS

History: The patient presented 6 days ago with hematuria and pollakiuria for 2 days.
Upon palpation of the abdomen, a painful mass was noted.

Abnormal PE/Chem/CBC/UA Results: UA complete: Protein 2+ HIGH Blood 1+ HIGH WBC 11-20 0 - 3/ HPF HIGH Bacteria Rods 26-50/ HPF HIGH Superchem: Total Protein 8.6 5.0 - 7.4 g/dL HIGH Albumin 2.4 2.7 - 4.4 g/dL LOW Globulin 6.2 1.6 - 3.6 g/dL HIGH A/G Ratio 0.4 0.8 - 2.0 LOW Urine culture: Organism #1 Escherichia coli Approximately 100,000 colonies/ml.

ULTRASONOGRAPHIC EXAMINATION OF THE ABDOMEN

Urinary System

Small urinary bladder with a normal thickness but irregular appearance of the wall. Normal anechoic urine with no sediment present. A few small uroliths were evident, measuring up to 1.1 cm in size. Normal appearance of the trigone area, proximal urethra, and iliac blood vessels. Normal appearance and size of the iliac lymph nodes. Ureters not visualized, which can be considered a normal finding.

The prostate was not visualized.

Normal renal size, architecture, echogenic appearance, cortico-medullary differentiation, which maintains a 1:3 cortex to medulla ratio, pelvis, and capsule. No infarcts, mineralization or renoliths evident. The left kidney measured 8.0 cm. The right kidney measured 8.2 cm.

Adrenal Glands

Normal shape, echogenic appearance, size, position, and appearance of the visible peri-adrenal vasculature. The left adrenal gland measured 2.77 cm in length x 0.73 cm in width. The right adrenal gland measured 2.2 cm in length x 0.61 cm in width.

Spleen

Normal size (2.6 cm in width) and echogenic appearance. Smooth homogenous parenchyma and regular curvilinear capsule. Normal volume of the splenic vasculature without any overt congestion or thrombosis evident. No inflammatory, neoplastic, infarction, or infiltrative changes evident.

Liver

Normal size, echogenic appearance, portal markings, and regular curvilinear capsule. No nodules or masses evident. Normal appearance of the hepatic and portal vasculature.

Gallbladder

Full gallbladder, containing normal anechoic bile. Normal thickness and echogenic appearance of the wall. Normal size and appearance of the cystic and common bile duct.

Gastrointestinal

Normal appearance of the stomach, duodenum, small intestine, ileo-cecal junction, and colon with no loss of layering, 1:3 muscularis to mucosa ratio, normal wall thickness and peristaltic activity, and no distension of the lumen.

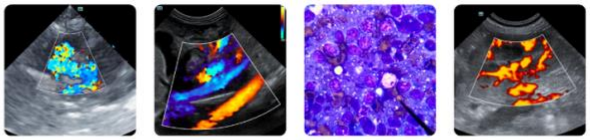

PATIENT

Hercules Desousa

SPECIES

Canine

BREED

Great Dane

SEX

Neutered Male

AGE

7 Years 6 Months

WEIGHT

153 Pounds

INTERPRETED BY

Remo Lobetti BVSc, MMedVet, PhD, DECVIM

IMAGING PERFORMED BY

Dr. Paul Kim

HOSPITAL NAME

Ridgefield Park AH

REFERRING VET

Dr. Daniel Dima

INVOICE

37268

DATE

5/28/26

Pancreas

Visible sections of the pancreas are of normal size and echogenic appearance with a regular capsule. Normal echogenic appearance of the mesentery and fat surrounding the pancreas. The left pancreas measured 1.1 cm in width.

Free Abdomen

Normal mesenteric lymph nodes.

No ascites evident.

Mottled echogenic circumscribed mass was noted in the cranial abdomen, possibly originating off the tail of the spleen. The mass measured approximately 5.0 cm x 6.0 cm in size.

ULTRASONOGRAPHIC FINDINGS

- Abdominal mass
- Uroliths
- Urinary bladder pathology

INTERPRETATION OF THE FINDINGS & FURTHER RECOMMENDATIONS

Etiologies for the abdominal mass would be neoplasia, granuloma, and organized hematoma.

The most likely etiology for the appearance of the urinary bladder wall would be secondary to the bacterial cystitis and the uroliths, with emerging neoplasia and unlikely differential diagnosis.

Further assessment would be three view thoracic radiographs, echocardiography to evaluate the right atrium and right auricle, and possibly FNA cytology of the abdominal mass. Laparotomy could be considered, as it may be both diagnostic and therapeutic with further specific therapy dependent on an etiological diagnosis.

SonoPath
FOSTERING THE ART OF VETERINARY MEDICINE™

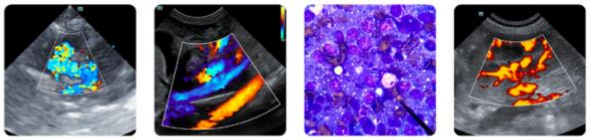

Clinical Sonography & Telecytology
Educational Teleconsultation Services™

SonoPath.com info@sonopath.com 1.800.838.4268

PATIENT

Hercules Desousa

SPECIES

Canine

BREED

Great Dane

SEX

Neutered Male

AGE

7 Years 6 Months

WEIGHT

153 Pounds

INTERPRETED BY

Remo Lobetti BVSc, MMedVet, PhD, DECVIM

IMAGING PERFORMED BY

Dr. Paul Kim

HOSPITAL NAME

Ridgefield Park AH

REFERRING VET

Dr. Daniel Dima

INVOICE

37268

DATE

5/28/26

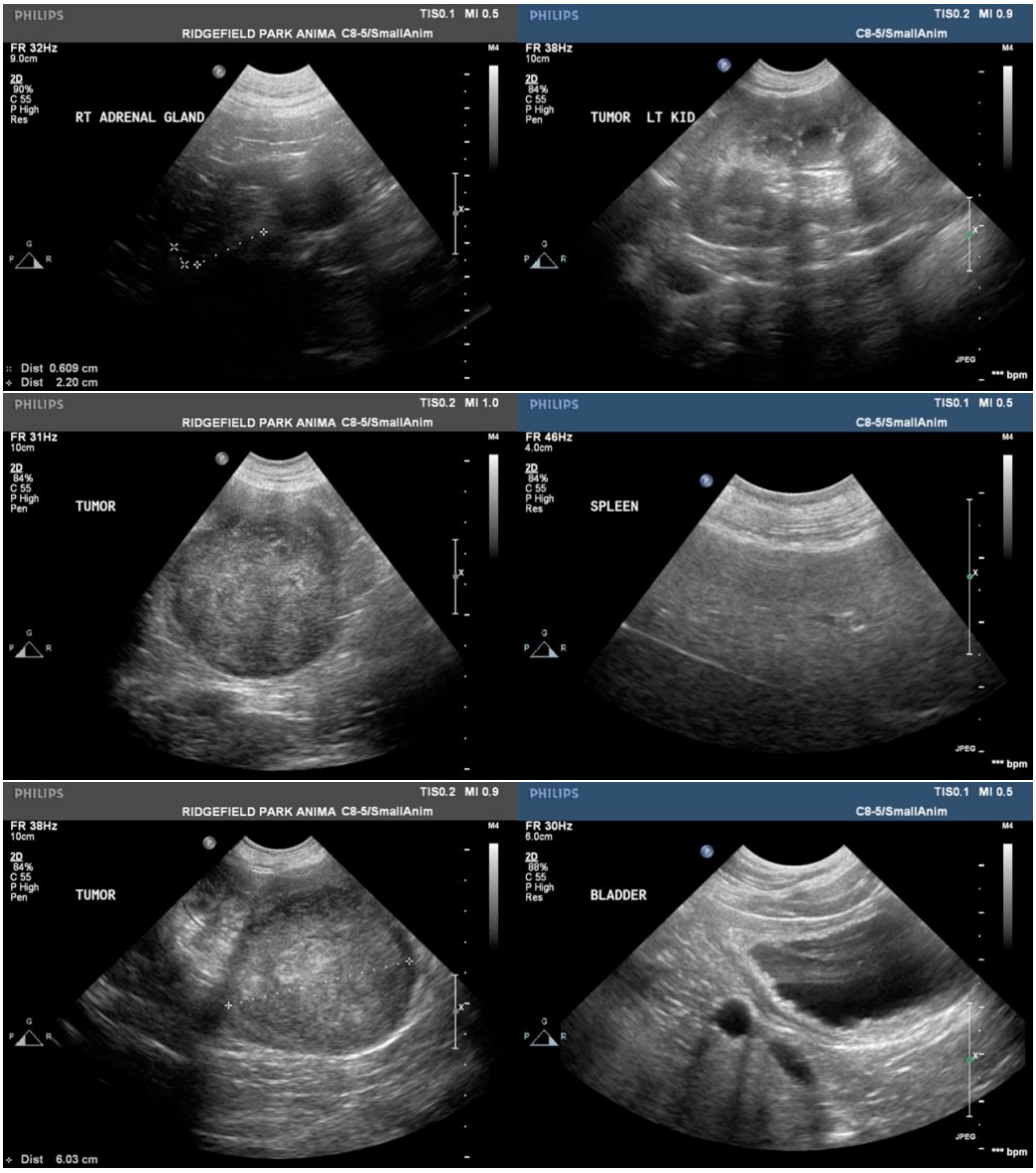

PATIENT

Hercules Desousa

SPECIES

Canine

BREED

Great Dane

SEX

Neutered Male

AGE

7 Years 6 Months

WEIGHT

153 Pounds

INTERPRETED BY

Remo Lobetti BVSc, MMedVet, PhD, DECVIM

IMAGING PERFORMED BY

Dr. Paul Kim

HOSPITAL NAME

Ridgefield Park AH

REFERRING VET

Dr. Daniel Dima

INVOICE

37268

DATE

5/28/26

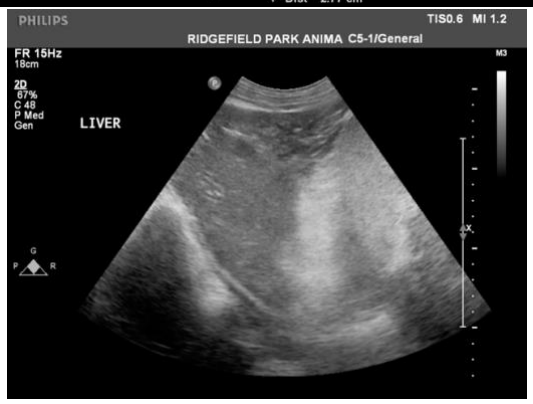

The information and recommendations provided are based on the images presented by the referring veterinarian/sonographer. No evaluation can be communicated regarding pathology that was not visible in the image/video clips provided.

Thank you for this referral. If the clinical or image interpretation does not parallel your findings or if I can be of any further assistance, please contact me.

Remo Lobetti, BVSc, MMedVet (Med), PhD, Dipl. ECVIM (Internal Medicine)

info@sonopath.com