



PATIENT

Gypsy Epstein

SPECIES

Canine

BREED

Pitbull

SEX

Spayed Female

AGE

11.5

WEIGHT

31.4

INTERPRETED BY

Remo Lobetti, BVSc,
MMedVet (Med),
PhD, Dipl. ECVIM

IMAGING PERFORMED BY

Dr. Leah Richter

HOSPITAL NAME

Allied VE & Referral

REFERRING VET

Dr. Leah Richter

INVOICE

37271

DATE

5/28/26

PRESENTING CLINICAL SIGNS

History: Presented on 5/20 for lethargy and a decreasing appetite over the course of the last month. BW was suggestive of pancreatitis and Gypsy was discharged with supportive outpatient medications (cerenia, proviable, omeprazole). TXR to investigate the cough were consistent with age-related changes or chronic bronchitis. Since discharge and initiating treatment, Gypsy has improved overall. Still a small amount of diarrhea, but gas is improved and appetite is normal.

Abnormal PE/Chem/CBC/UA Results: 5/20/26 CBC: WNL Chem: Amylase >2500 (H), Lipase 5926 (H), otherwise WNL CPL: 1412 (H) UA (cysto): USG 1.022, quiet sediment AXR (Idexx): Age-related pulmonary changes or chronic bronchitis. Concurrent acute infectious/inflammatory bronchitis or pneumonitis considered possible. No evidence of pneumonia.

ULTRASONOGRAPHIC EXAMINATION OF THE ABDOMEN

Urinary System

Full urinary bladder with a normal thickness and smooth appearance of the wall. Normal anechoic urine with no sediment or uroliths evident. Normal appearance of the trigone area, proximal urethra, and iliac blood vessels. Normal appearance and size of the iliac lymph nodes. Ureters not visualized, which can be considered a normal finding.

Normal renal size, architecture, echogenic appearance, cortico-medullary differentiation, which maintains a 1:3 cortex to medulla ratio, pelvis, and capsule. No infarcts, mineralization or renoliths evident. The left kidney measured 6.7 cm. The right kidney measured 7.3 cm. Normal color flow pattern was evident in both kidneys.

Adrenal Glands

Normal shape, echogenic appearance, size, position, and appearance of the visible peri-adrenal vasculature. The left adrenal gland measured 0.51 cm in width. The right adrenal gland measured 0.61 cm in width.

Spleen

Normal size (2.9 cm in width) and echogenic appearance. Smooth homogenous parenchyma and regular curvilinear capsule. Normal volume of the splenic vasculature without any overt congestion or thrombosis evident. No inflammatory, neoplastic, infarction, or infiltrative changes evident.

Liver

Normal size, echogenic appearance, portal markings, and regular curvilinear capsule. No nodules or masses evident. Normal appearance of the hepatic and portal vasculature.

Gallbladder

Full gallbladder, containing normal anechoic bile. Normal thickness and echogenic appearance of the wall. Normal size and appearance of the cystic and common bile duct.

Gastrointestinal



PATIENT

Gypsy Epstein

Normal appearance of the stomach, duodenum, small intestine, ileo-cecal junction, and colon with no loss of layering, 1:3 muscularis to mucosa ratio, normal wall thickness and peristaltic activity, and no distension of the lumen.

SPECIES

Canine

Pancreas

Visible sections of the pancreas are of normal size and echogenic appearance with a regular capsule. Normal echogenic appearance of the mesentery and fat surrounding the pancreas.

BREED

Pitbull

Free Abdomen

Normal mesenteric lymph nodes.

SEX

Spayed Female

No ascites evident.

AGE

11.5

ULTRASONOGRAPHIC FINDINGS

- Normal ultrasound examination of the abdomen

INTERPRETATION OF THE FINDINGS & FURTHER RECOMMENDATIONS

WEIGHT

31.4

Long term management of a patient with pancreatitis would be feeding small frequent meals of a low fat intestinal type diet.

INTERPRETED BY

Remo Lobetti, BVSc,
MMedVet (Med),
PhD, Dipl. ECVIM

IMAGING PERFORMED BY

Dr. Leah Richter

HOSPITAL NAME

Allied VE & Referral

REFERRING VET

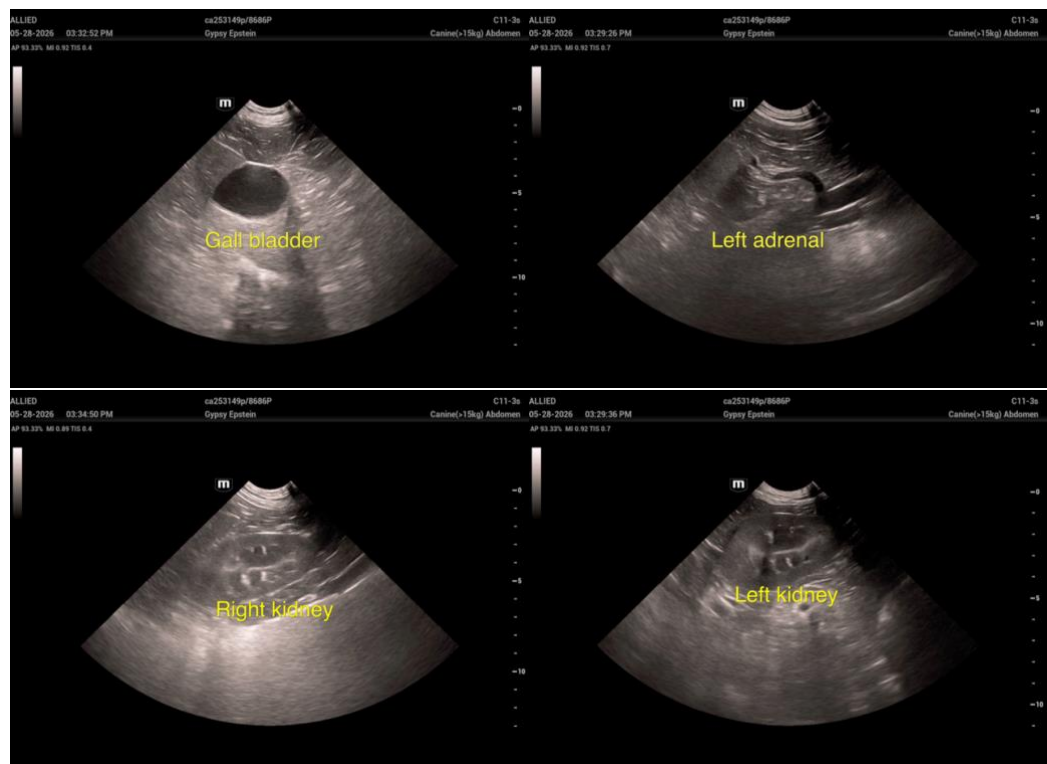
Dr. Leah Richter

INVOICE

37271

DATE

5/28/26





PATIENT

Gypsy Epstein

SPECIES

Canine

BREED

Pitbull

SEX

Spayed Female

AGE

11.5

WEIGHT

31.4

INTERPRETED BY

Remo Lobetti, BVSc,
MMedVet (Med),
PhD, Dipl. ECVIM

IMAGING PERFORMED BY

Dr. Leah Richter

HOSPITAL NAME

Allied VE & Referral

REFERRING VET

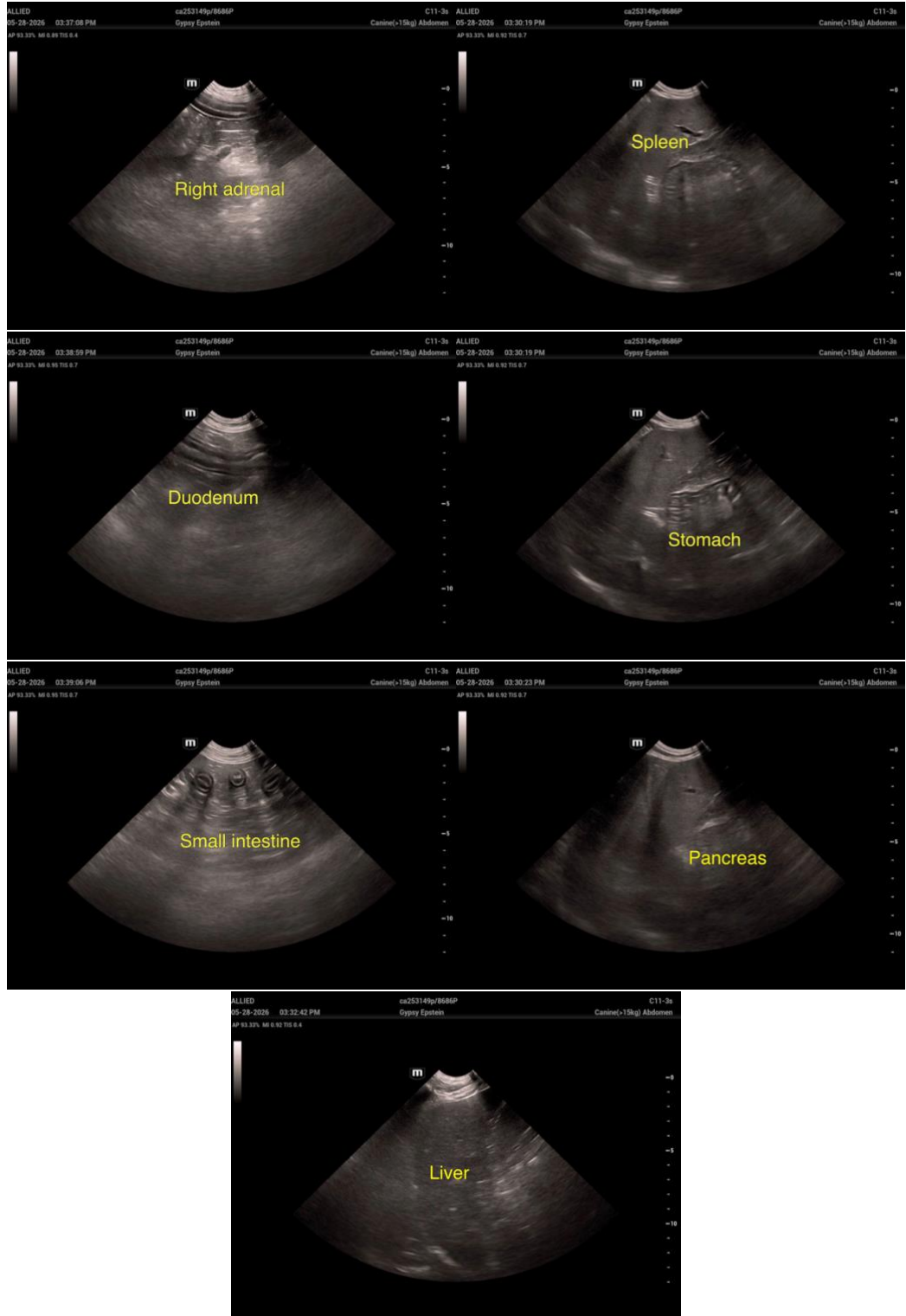
Dr. Leah Richter

INVOICE

37271

DATE

5/28/26





PATIENT

Gypsy Epstein

SPECIES

Canine

BREED

Pitbull

SEX

Spayed Female

AGE

11.5

WEIGHT

31.4

INTERPRETED BY

Remo Lobetti, BVSc,
MMedVet (Med),
PhD, Dipl. ECVIM

IMAGING PERFORMED BY

Dr. Leah Richter

HOSPITAL NAME

Allied VE & Referral

REFERRING VET

Dr. Leah Richter

INVOICE

37271

DATE

5/28/26

The information and recommendations provided are based on the images presented by the referring veterinarian/sonographer. No evaluation can be communicated regarding pathology that was not visible in the image/video clips provided.

Thank you for this referral. If the clinical or image interpretation does not parallel your findings or if I can be of any further assistance, please contact me.

Remo Lobetti, BVSc, MMedVet (Med), PhD, Dipl. ECVIM (Internal Medicine)

info@sonopath.com