



**PATIENT**

Tiger Lopez

**SPECIES**

Feline

**BREED**

DSH

**SEX**

Neutered Male

**AGE**

11 Years

**WEIGHT**

9.45 lbs

**INTERPRETED BY**

Remo Lobetti, BVSc,  
MMedVet (Med),  
PhD, Dipl. ECVIM

**IMAGING PERFORMED BY**

Kerri Becker

**HOSPITAL NAME**

Packanack Animal  
Hospital

**REFERRING VET**

Dr. Katz

**INVOICE**

75386

**DATE**

5/22/26

**PRESENTING CLINICAL SIGNS**

Vomiting, recent dx hyperthyroid, dehydration.  
Abnormal PE/Chem/CBC/UA Results: UA ph-8.5 prot-3+ upc<0.1 usg-1.062

**ULTRASONOGRAPHIC EXAMINATION OF THE ABDOMEN**

**Urinary System**

Full urinary bladder with a normal thickness and smooth appearance of the wall. Normal anechoic urine with no sediment or uroliths evident.

Normal appearance of the trigone area, proximal urethra, and iliac blood vessels.

Normal appearance and size of the iliac lymph nodes. Ureters not visualized, which can be considered a normal finding.

Normal renal size, architecture, echogenic appearance, cortico-medullary differentiation, which maintains a 1:3 cortex to medulla ratio, pelvis, and capsule. No infarcts, mineralization or renoliths evident. The kidneys measure 3.7 cm each. Normal color flow pattern evident.

**Adrenal Glands**

Normal shape, echogenic appearance, size, position, and appearance of the visible peri-adrenal vasculature. Left measures 0.30 cm in width. Right measures 0.38 cm in width.

**Spleen**

Normal size (0.50 cm in width) and echogenic appearance. Smooth homogenous parenchyma and regular curvilinear capsule. Normal volume of the splenic vasculature without any overt congestion or thrombosis evident. No inflammatory, neoplastic, infarction, or infiltrative changes evident.

**Liver**

Normal size, echogenic appearance, portal markings, and regular curvilinear capsule. No nodules or masses evident. Normal appearance of the hepatic and portal vasculature.

**Gallbladder**

Full containing normal anechoic bile. Normal thickness and echogenic appearance of the wall. Normal size and appearance of the cystic and common bile duct.

**Gastrointestinal**

Normal appearance of the stomach, duodenum, small intestine, ileo-cecal junction, and colon with no loss of layering, 1:3 muscularis to mucosa ratio, normal wall thickness and peristaltic activity, and no distension of the lumen.

**Pancreas**

Enlarged left pancreas (0.60 cm in width), which a hypoechogenic appearance and a slightly irregular capsule. Mild increase in echogenic appearance of the mesentery and fat surrounding the pancreas.



**PATIENT**

Tiger Lopez

**SPECIES**

Feline

**BREED**

DSH

**SEX**

Neutered Male

**AGE**

11 Years

**WEIGHT**

9.45 lbs

**INTERPRETED BY**

Remo Lobetti, BVSc,  
MMedVet (Med),  
PhD, Dipl. ECVIM

**IMAGING PERFORMED BY**

Kerri Becker

**HOSPITAL NAME**

Packanack Animal  
Hospital

**REFERRING VET**

Dr. Katz

**INVOICE**

75386

**DATE**

5/22/26

**Free Abdomen**

Normal mesenteric lymph nodes.

No ascites evident.

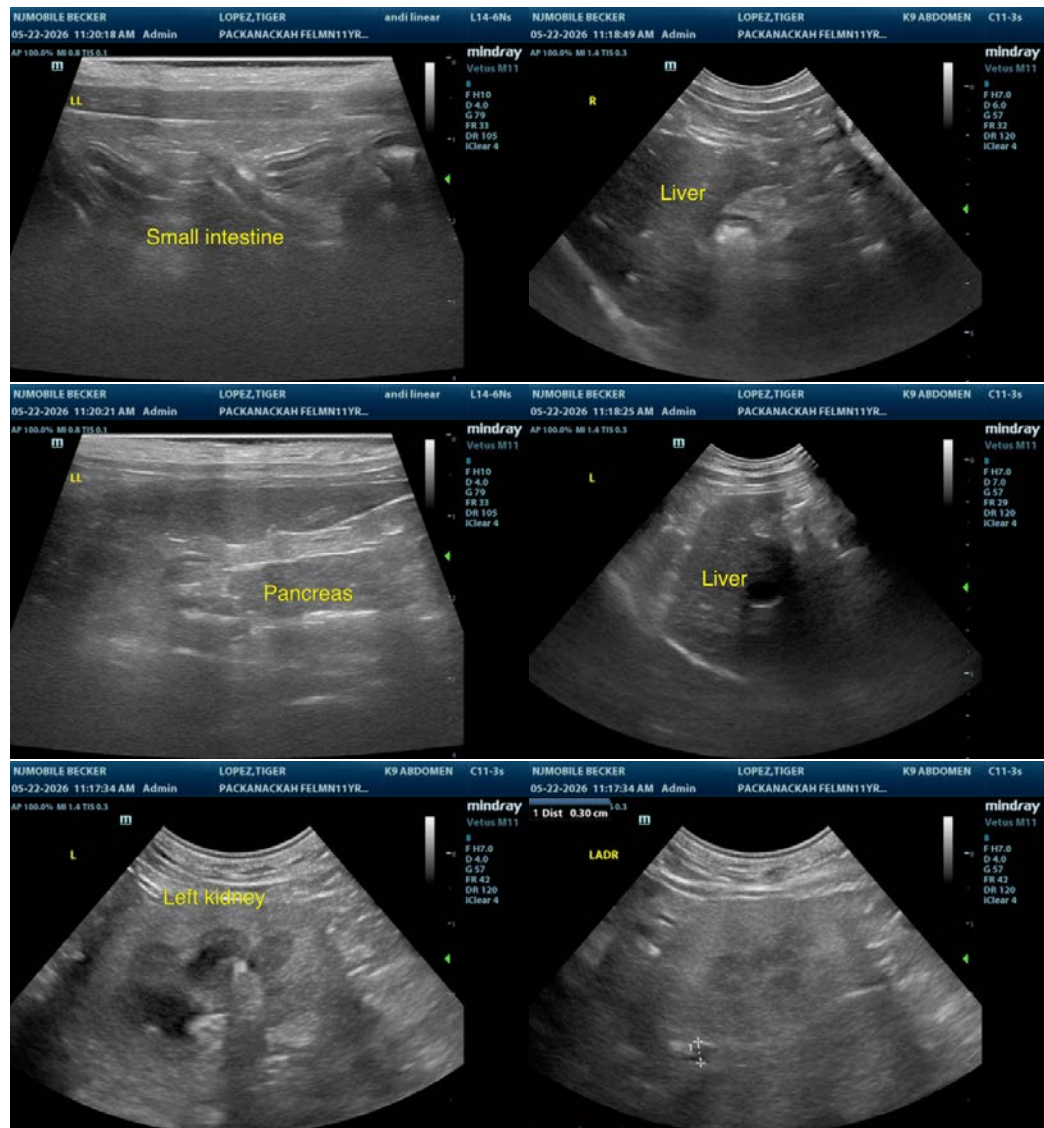
**ULTRASONOGRAPHIC FINDINGS**

- Pancreatitis.

**INTERPRETATION OF THE FINDINGS & FURTHER RECOMMENDATIONS**

Further assessment would be fPL/PSL assay.

Management of the pancreatitis would be fluid therapy, correction of any electrolyte anomalies, antiemetics, analgesics, and feeding small, frequent meals of a low-fat intestinal type diet.





**PATIENT**

Tiger Lopez

**SPECIES**

Feline

**BREED**

DSH

**SEX**

Neutered Male

**AGE**

11 Years

**WEIGHT**

9.45 lbs

**INTERPRETED BY**

Remo Lobetti, BVSc,  
MMedVet (Med),  
PhD, Dipl. ECVIM

**IMAGING PERFORMED BY**

Kerri Becker

**HOSPITAL NAME**

Packanack Animal  
Hospital

**REFERRING VET**

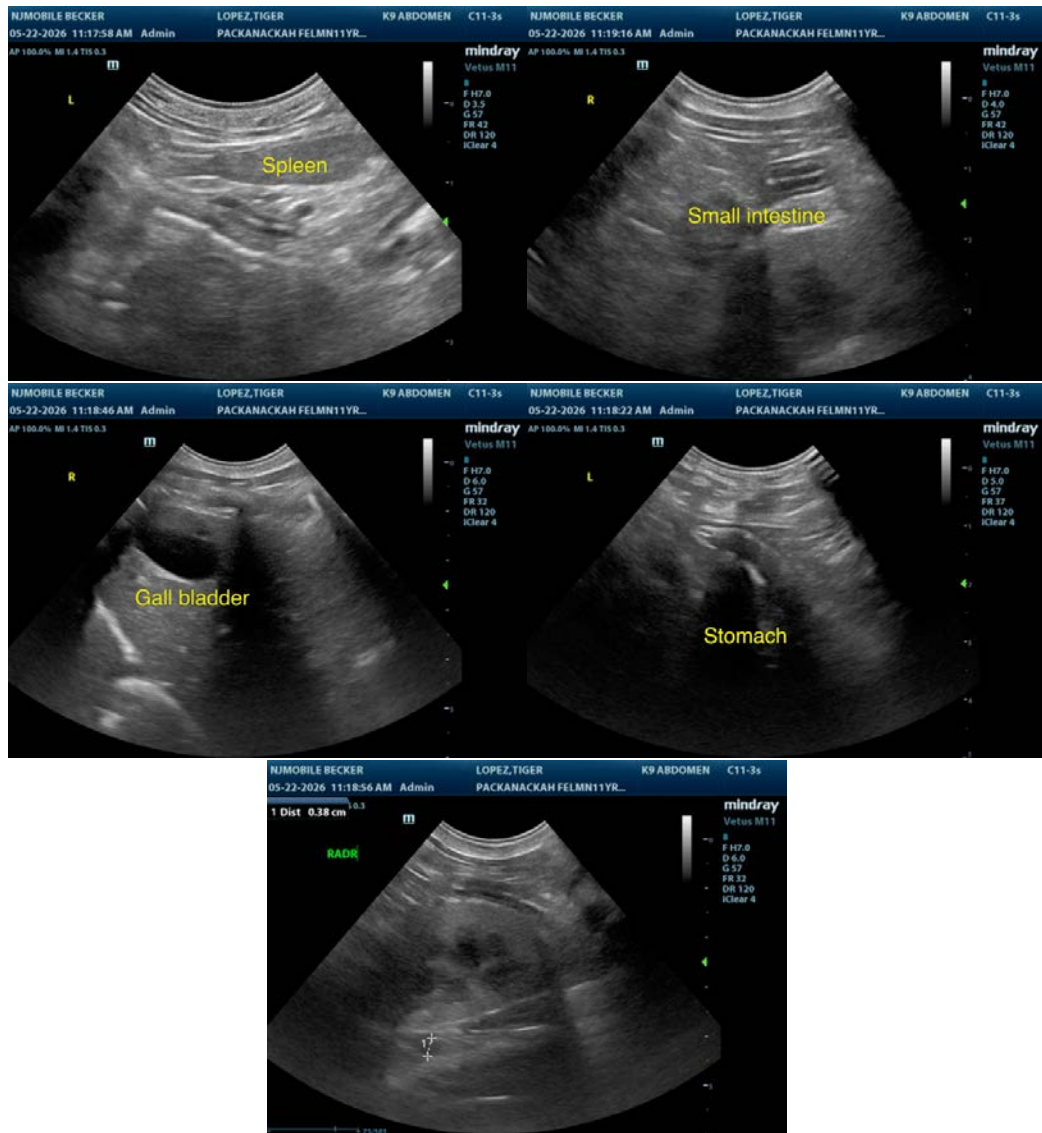
Dr. Katz

**INVOICE**

75386

**DATE**

5/22/26



The information and recommendations provided are based on the images presented by the referring veterinarian. No evaluation can be communicated regarding pathology that was not visible in the image/video clips provided.

Thank you for this referral. If the clinical or image interpretation does not parallel your findings or if I can be of any further assistance, please contact me.

**Remo Lobetti, BVSc, MMedVet (Med), PhD, Dipl. ECVIM (Internal Medicine)**

[info@sonopath.com](mailto:info@sonopath.com)