



PATIENT

Bailey Villegas

SPECIES

Canine

BREED

Doodle

SEX

Neutered Male

AGE

8 Years

WEIGHT

31 Pounds

INTERPRETED BY

Remo Lobetti BVSc,
 MMedVet, PhD,
 DECVIM

IMAGING PERFORMED BY

Kerri Becker

HOSPITAL NAME

All Creatures Denville

REFERRING VET

Dr. Ashmore

INVOICE

37176

DATE

5/22/26

PRESENTING CLINICAL SIGNS

History: Recheck gallbladder sediment. Dog is acting much better. Denamarin and ursodiol.

ULTRASONOGRAPHIC EXAMINATION OF THE ABDOMEN

Urinary System

Full urinary bladder with a normal thickness and smooth appearance of the wall. Normal anechoic urine with no sediment or uroliths evident. Normal appearance of the trigone area, proximal urethra, and iliac blood vessels. Normal appearance and size of the iliac lymph nodes. Ureters not visualized, which can be considered a normal finding.

Small hypoechogenic prostate was noted.

Normal renal size, architecture, echogenic appearance, cortico-medullary differentiation, which maintains a 1:3 cortex to medulla ratio, pelvis, and capsule. No infarcts, mineralization or renoliths evident. The left kidney measured 5.6 cm. The right kidney measured 6.1 cm. Normal color flow pattern was evident in both kidneys.

Adrenal Glands

Normal shape, echogenic appearance, size, position, and appearance of the visible peri-adrenal vasculature. The left adrenal gland measured 2.01 cm in length x 0.49 cm and 0.64 cm in width. The right adrenal gland measured 2.11 cm in length x 0.71 cm and 0.67 cm in width.

Spleen

Normal size (1.4 cm in width) and echogenic appearance. Smooth homogenous parenchyma and regular curvilinear capsule. Normal volume of the splenic vasculature without any overt congestion or thrombosis evident. No inflammatory, neoplastic, infarction, or infiltrative changes evident.

Liver

Normal size, echogenic appearance, portal markings, and regular curvilinear capsule. No nodules or masses evident. Normal appearance of the hepatic and portal vasculature.

Gallbladder

Full gallbladder, containing a small amount of adhered hyperechogenic sediment. Normal thickness and echogenic appearance of the wall. Normal size and appearance of the cystic and common bile duct.

Gastrointestinal

Normal appearance of the stomach, duodenum, small intestine, ileo-cecal junction, and colon with no loss of layering, 1:3 muscularis to mucosa ratio, normal wall thickness and peristaltic activity, and no distension of the lumen. A moderate amount of ingesta was present within the stomach, compatible with a recent meal.

Pancreas



PATIENT

Visible sections of the pancreas are of normal size and echogenic appearance with a regular capsule. Normal echogenic appearance of the mesentery and fat surrounding the pancreas.

Bailey Villegas

Free Abdomen

SPECIES

Normal mesenteric lymph nodes.

Canine

No ascites evident.

BREED

ULTRASONOGRAPHIC FINDINGS

Doodle

- Gallbladder sediment

SEX

INTERPRETATION OF THE FINDINGS & FURTHER RECOMMENDATIONS

Neutered Male

The appearance of a gallbladder on this ultrasound is similar to that of the previous ultrasound and thus the gallbladder sediment can be considered an incidental finding.

AGE

8 Years

WEIGHT

31 Pounds

INTERPRETED BY

Remo Lobetti BVSc,
 MMedVet, PhD,
 DECVIM

IMAGING PERFORMED BY

Kerri Becker

HOSPITAL NAME

All Creatures Denville

REFERRING VET

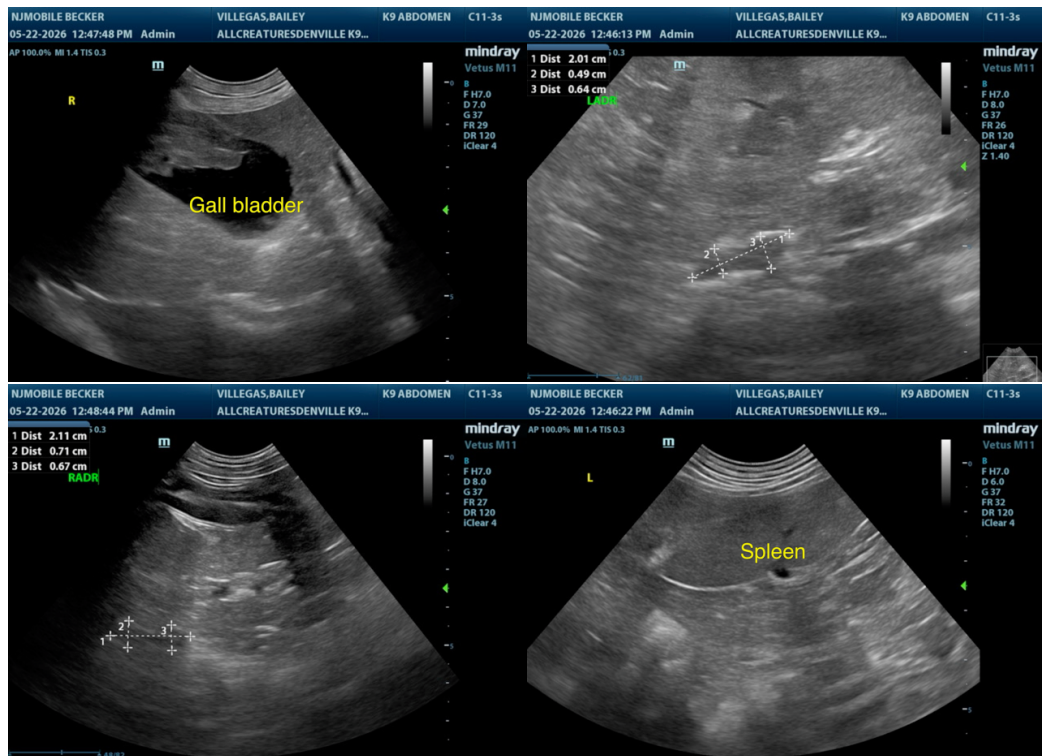
Dr. Ashmore

INVOICE

37176

DATE

5/22/26





PATIENT

Bailey Villegas

SPECIES

Canine

BREED

Doodle

SEX

Neutered Male

AGE

8 Years

WEIGHT

31 Pounds

INTERPRETED BY

Remo Lobetti BVSc,
 MMedVet, PhD,
 DECVIM

IMAGING PERFORMED BY

Kerri Becker

HOSPITAL NAME

All Creatures Denville

REFERRING VET

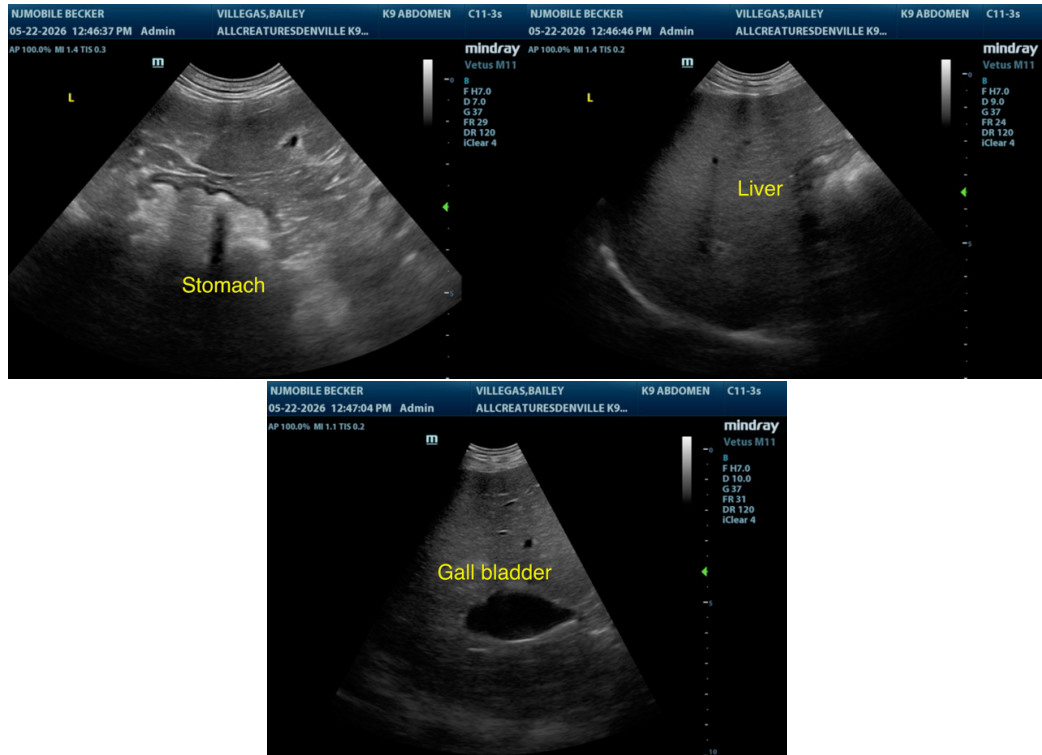
Dr. Ashmore

INVOICE

37176

DATE

5/22/26



The information and recommendations provided are based on the images presented by the referring veterinarian/sonographer. No evaluation can be communicated regarding pathology that was not visible in the image/video clips provided.

Thank you for this referral. If the clinical or image interpretation does not parallel your findings or if I can be of any further assistance, please contact me.

Remo Lobetti, BVSc, MMedVet (Med), PhD, Dipl. ECVIM (Internal Medicine)

info@sonopath.com