



PATIENT

Rika Lakjer

SPECIES

Canine

BREED

Greyhound

SEX

Spayed Female

AGE

6 ½ years

WEIGHT

48.4 lbs

INTERPRETED BY

Remo Lobetti, BVSc,
MMedVet (Med),
PhD, Dipl. ECVIM

IMAGING PERFORMED BY

Dr. Arms

HOSPITAL NAME

Gilbertsville VH

REFERRING VET

Dr. Alivernini

INVOICE

77815

DATE

5/21/26

PRESENTING CLINICAL SIGNS

History: Chronic intermittent GI signs (Diarrhea). History of chronic hookworms but recently negative fecals

ULTRASONOGRAPHIC EXAMINATION OF THE ABDOMEN

Urinary System

The urinary bladder is small with a normal thickness and smooth appearance of the wall. Normal anechoic urine with no sediment or uroliths evident.

Normal appearance of the trigone area and iliac blood vessels. The proximal urethra was not visualized.

Normal appearance and size of the iliac lymph nodes. Ureters not visualized, which can be considered a normal finding.

Normal renal size (left measured 6.2 cm, right measured 6.0 cm), architecture, echogenic appearance, cortico-medullary differentiation, which maintains a 1:3 cortex to medulla ratio, pelvis, and capsule. No infarcts, mineralization or renoliths evident.

Adrenal Glands

The adrenal glands are not clearly visualized, but appear to be of normal shape, echogenic appearance and size.

Spleen

Normal size and echogenic appearance. Smooth homogenous parenchyma and regular curvilinear capsule. Normal volume of the splenic vasculature without any overt congestion or thrombosis evident. No inflammatory, neoplastic, infarction, or infiltrative changes evident. The spleen measured 3.1 cm in width.

Liver

Normal size, echogenic appearance, portal markings, and regular curvilinear capsule. No nodules or masses evident. Normal appearance of the hepatic and portal vasculature.

Gallbladder

The gallbladder is full containing normal anechoic bile. Normal thickness and echogenic appearance of the wall. Normal size and appearance of the cystic and common bile duct.



PATIENT

Rika Lakjer

SPECIES

Canine

BREED

Greyhound

SEX

Spayed Female

AGE

6 ½ years

WEIGHT

48.4 lbs

INTERPRETED BY

Remo Lobetti, BVSc,
MMedVet (Med),
PhD, Dipl. ECVIM

IMAGING PERFORMED BY

Dr. Arms

HOSPITAL NAME

Gilbertsville VH

REFERRING VET

Dr. Alivernini

INVOICE

77815

DATE

5/21/26

Gastrointestinal

Normal appearance of the stomach, duodenum, small intestine, ileo-cecal junction, and colon with no loss of layering, 1:3 muscularis to mucosa ratio, normal wall thickness and peristaltic activity, and no distension of the lumen.

Pancreas

The visible sections of the pancreas are of normal size and echogenic appearance with a regular capsule. Normal echogenic appearance of the mesentery and fat surrounding the pancreas.

Free Abdomen

Prominent mesenteric lymph nodes measuring up to 0.6 x 2.7 cm in size with a hypoechoic appearance, but maintaining a normal shape.

No ascites evident.

ULTRASONOGRAPHIC FINDINGS

- Mesenteric lymphadenomegaly.

INTERPRETATION OF THE FINDINGS & FURTHER RECOMMENDATIONS

On this ultrasound there is no obvious etiology for the chronic intermittent diarrhea.

Although the GI tract appears ultrasonographically normal, with the presenting clinical signs, an underlying enteropathy such as dietary hypersensitivity, inflammatory bowel disease and possibly atypical Addison's should still be considered.

Further assessment would be cobalamin, folate and basal cortisol assay, possibly an ACTH stimulation test and endoscopy of the upper GI tract with biopsies.

Specific therapy would be dependent on an etiological diagnosis.

Symptomatic management that could be considered would be feeding a novel protein/hypoallergenic diet, cobalamin supplementation and if there is still not a satisfactory improvement then a course of Prednisolone would then be indicated.



PATIENT

Rika Lakjer

SPECIES

Canine

BREED

Greyhound

SEX

Spayed Female

AGE

6 ½ years

WEIGHT

48.4 lbs

INTERPRETED BY

Remo Lobetti, BVSc,
MMedVet (Med),
PhD, Dipl. ECVIM

IMAGING PERFORMED BY

Dr. Arms

HOSPITAL NAME

Gilbertsville VH

REFERRING VET

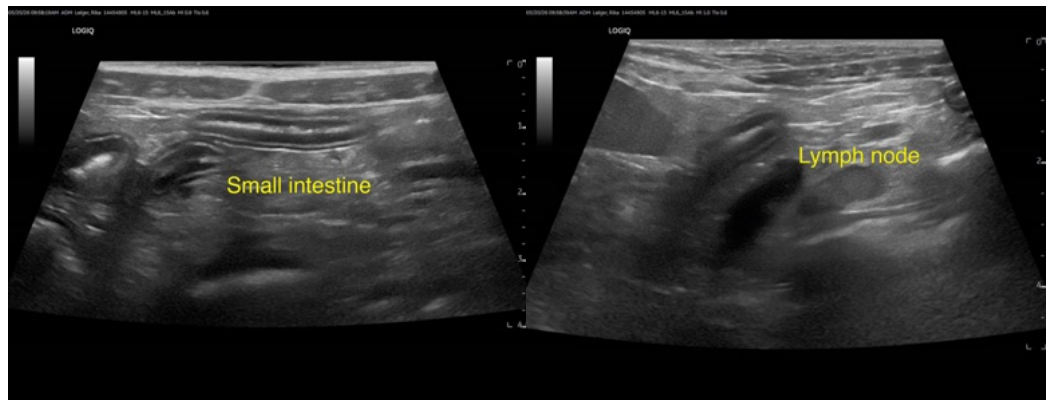
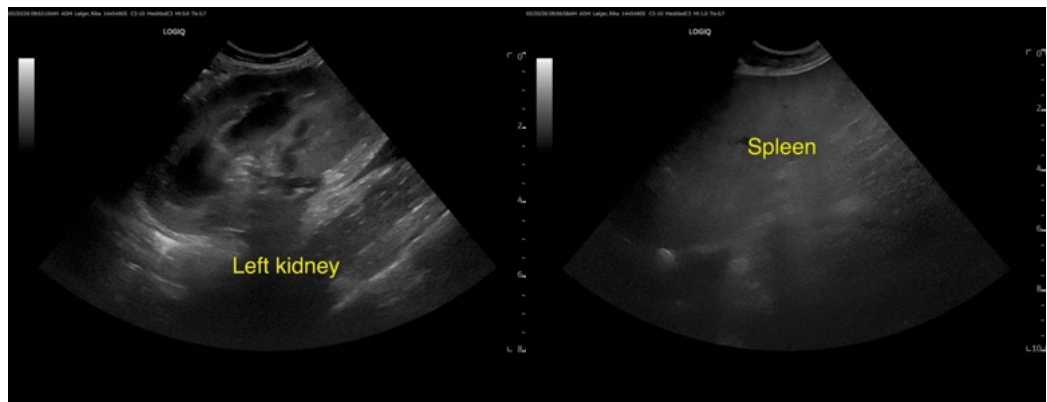
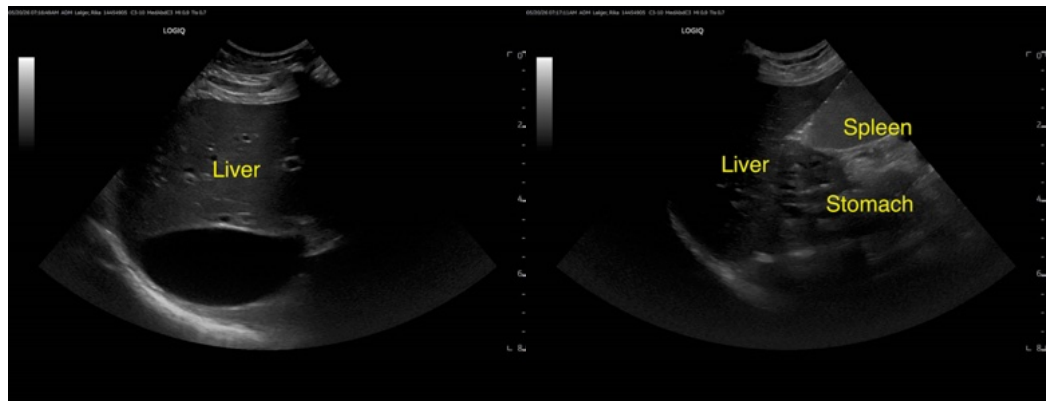
Dr. Alivernini

INVOICE

77815

DATE

5/21/26





PATIENT

Rika Lakjer

SPECIES

Canine

BREED

Greyhound

SEX

Spayed Female

AGE

6 ½ years

WEIGHT

48.4 lbs

INTERPRETED BY

Remo Lobetti, BVSc,
MMedVet (Med),
PhD, Dipl. ECVIM

IMAGING PERFORMED BY

Dr. Arms

HOSPITAL NAME

Gilbertsville VH

REFERRING VET

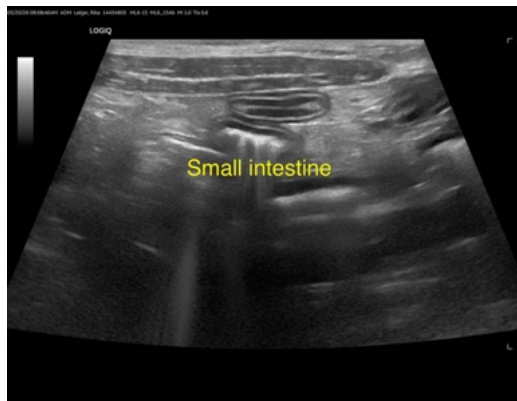Dr. Alivernini

INVOICE

77815

DATE

5/21/26



The information and recommendations provided are based on the images presented by the referring veterinarian/sonographer. No evaluation can be communicated regarding pathology that was not visible in the image/video clips provided.

Thank you for this referral. If the clinical or image interpretation does not parallel your findings or if I can be of any further assistance please contact me.

Remo Lobetti, BVSc, MMedVet (Med), PhD, Dipl. ECVIM (Internal Medicine)

info@sonopath.com