



PATIENT

Freya Simons

SPECIES

Canine

BREED

Greater Swiss
Mountain

SEX

Spayed female

AGE

3 years

WEIGHT

110 lbs

INTERPRETED BY

Remo Lobetti, BVSc,
MMedVet (Med),
PhD, Dipl. ECVIM

IMAGING PERFORMED BY

Brian Klug

HOSPITAL NAME

Sondel Family VC

REFERRING VET

Dr. Wallisch

INVOICE

77780

DATE

5/20/26

PRESENTING CLINICAL SIGNS

History: Symptoms started Jan 2026. Intermittent gastrointestinal symptoms of varying severity (vomiting/diarrhea/nausea/lip licking). Was positive for Giardia in January but successfully treated. In recent months, chief complaint is drooling, nausea/vomiting episodes, waxing/waning appetite & lethargy. Current food: Purina Pro Plan lamb and rice, sometimes bland diet chicken and rice. Medications: Omeprazole, Famotidine, Zyrtec, Fortiflora, Cerenia PRN, fish oil supplements
Abnormal PE/Chem/CBC/UA Results: PE nsf CBC: nsf CHEM: nsf, NA/K RATIO 33 Resting cortisol: 1.6 (1-5) Fecal PCR: negative

ULTRASONOGRAPHIC EXAMINATION OF THE ABDOMEN

Urinary System

The urinary bladder is small with a normal thickness and smooth appearance of the wall. Normal anechoic urine with no sediment or uroliths evident.

Normal appearance of the trigone area, proximal urethra, and iliac blood vessels.

Normal appearance and size of the iliac lymph nodes. Ureters not visualized, which can be considered a normal finding.

Normal renal size (left measured 7.5 cm, right measured 7.1 cm), architecture, echogenic appearance, cortico-medullary differentiation, which maintains a 1:3 cortex to medulla ratio, pelvis, and capsule. No infarcts, mineralization or renoliths evident.

Adrenal Glands

Normal shape, echogenic appearance, size, position, and appearance of the visible peri-adrenal vasculature. Left adrenal gland measured 0.43 cm and 0.62 cm in width. The right adrenal gland measured 0.4 cm and 0.55 cm in width.

Spleen

Normal size and echogenic appearance. Smooth homogenous parenchyma and regular curvilinear capsule. Normal volume of the splenic vasculature without any overt congestion or thrombosis evident. No inflammatory, neoplastic, infarction, or infiltrative changes evident. The spleen measured 2.4 cm in width.

Liver

Normal size, echogenic appearance, portal markings, and regular curvilinear capsule. No nodules or masses evident. Normal appearance of the hepatic and portal vasculature.



PATIENT

Freya Simons

SPECIES

Canine

BREED

Greater Swiss Mountain

SEX

Spayed female

AGE

3 years

WEIGHT

110 lbs

INTERPRETED BY

Remo Lobetti, BVSc,
MMedVet (Med),
PhD, Dipl. ECVIM

IMAGING PERFORMED BY

Brian Klug

HOSPITAL NAME

Sondel Family VC

REFERRING VET

Dr. Wallisch

INVOICE

77780

DATE

5/20/26

Gallbladder

The gallbladder is full containing normal anechoic bile. Normal thickness and echogenic appearance of the wall. Normal size and appearance of the cystic and common bile duct.

Gastrointestinal

Normal appearance of the stomach, duodenum, ileo-cecal junction, and colon with no loss of layering, 1:3 muscularis to mucosa ratio, normal wall thickness and peristaltic activity, and no distension of the lumen. Normal thickness of the small intestine (up to 0.37 cm) with no loss of layering, but with mild segmental increase in the muscularis to mucosa ratio, normal peristaltic activity and no distension of the lumen.

Pancreas

The visible sections of the pancreas are of normal size and echogenic appearance with a regular capsule. Normal echogenic appearance of the mesentery and fat surrounding the pancreas.

Free Abdomen

Normal mesenteric lymph nodes.

No ascites evident.

ULTRASONOGRAPHIC FINDINGS

- Enteropathy.

INTERPRETATION OF THE FINDINGS & FURTHER RECOMMENDATIONS

Etiologies for the enteropathy would be dietary hypersensitivity and inflammatory bowel disease.

Further assessment would be cobalamin and folate assay and endoscopy of the upper GI tract with biopsies.

Specific therapy would be dependent on an etiological diagnosis.

Symptomatic management that can be considered would be feeding small frequent meals of a novel protein/hypoallergenic diet, cobalamin supplementation and if there is still not a satisfactory improvement then a course of prednisolone would then be indicated.



PATIENT

Freya Simons

SPECIES

Canine

BREED

Greater Swiss Mountain

SEX

Spayed female

AGE

3 years

WEIGHT

110 lbs

INTERPRETED BY

Remo Lobetti, BVSc,
MMedVet (Med),
PhD, Dipl. ECVIM

IMAGING PERFORMED BY

Brian Klug

HOSPITAL NAME

Sondel Family VC

REFERRING VET

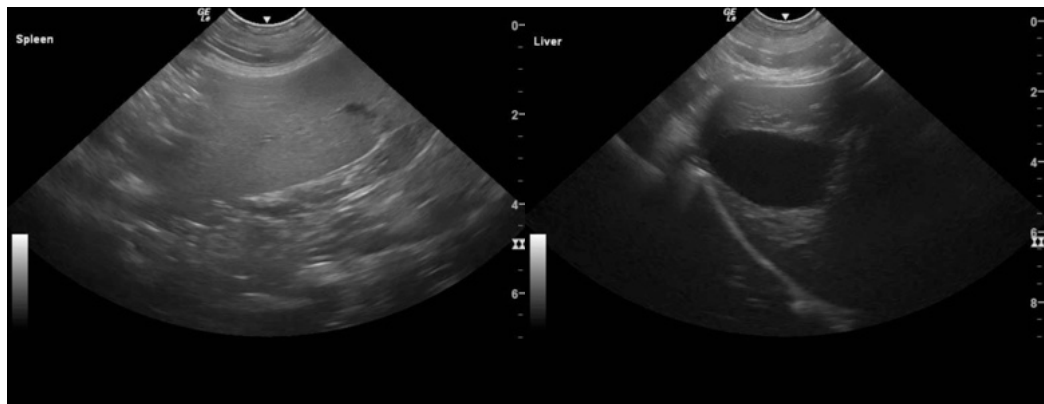
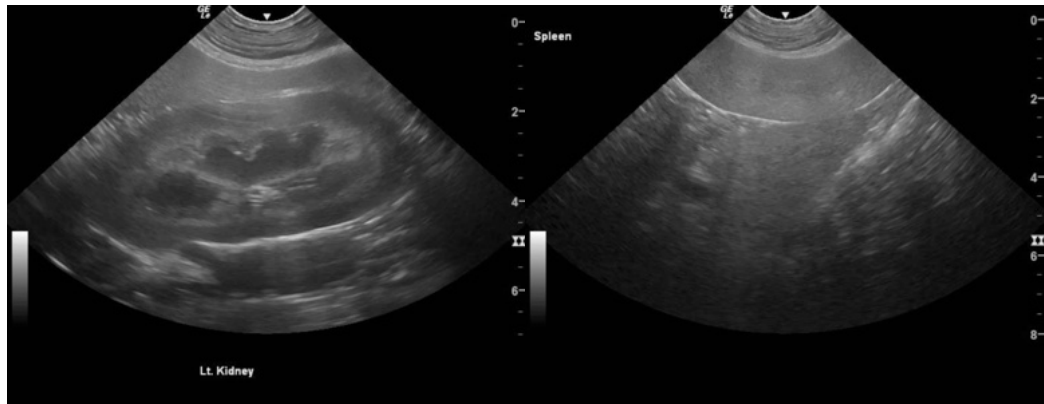
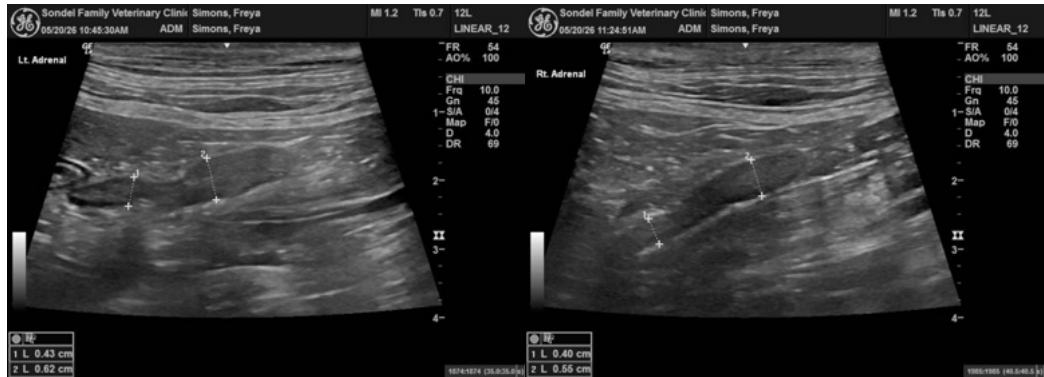
Dr. Wallisch

INVOICE

77780

DATE

5/20/26





PATIENT

Freya Simons

SPECIES

Canine

BREED

Greater Swiss Mountain

SEX

Spayed female

AGE

3 years

WEIGHT

110 lbs

INTERPRETED BY

Remo Lobetti, BVSc,
MMedVet (Med),
PhD, Dipl. ECVIM

IMAGING PERFORMED BY

Brian Klug

HOSPITAL NAME

Sondel Family VC

REFERRING VET

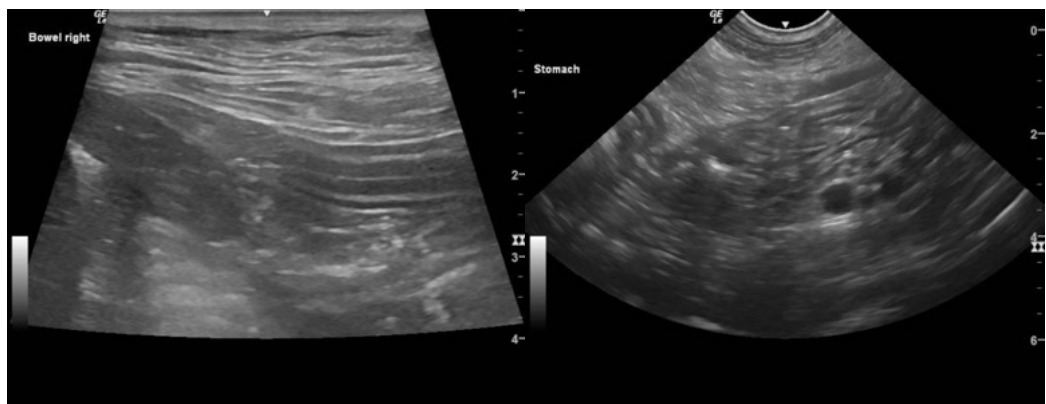
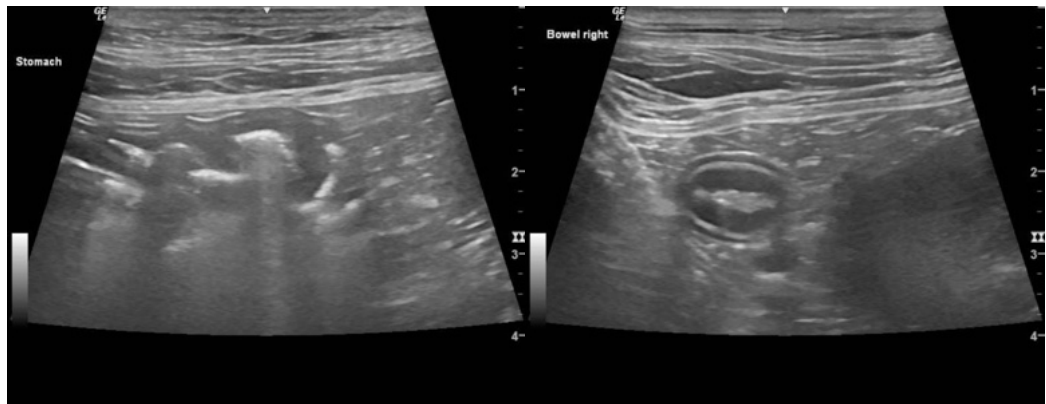
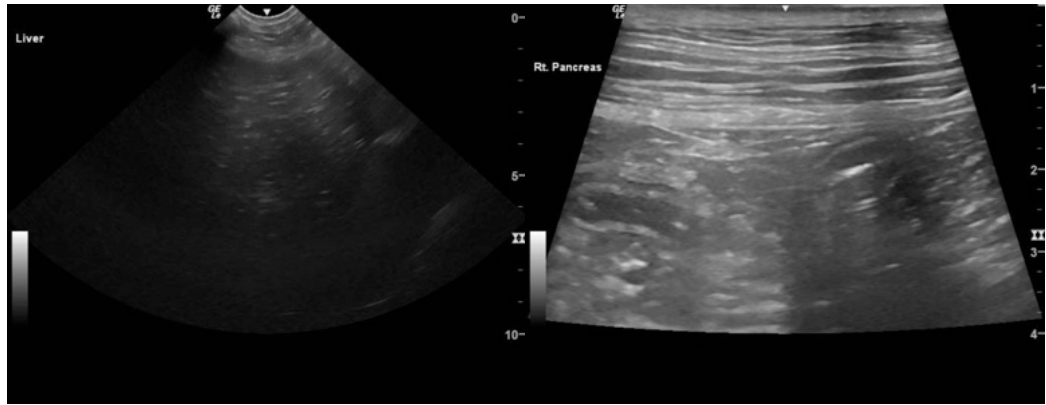
Dr. Wallisch

INVOICE

77780

DATE

5/20/26





PATIENT

Freya Simons

SPECIES

Canine

BREED

Greater Swiss Mountain

SEX

Spayed female

AGE

3 years

WEIGHT

110 lbs

INTERPRETED BY

Remo Lobetti, BVSc,
MMedVet (Med),
PhD, Dipl. ECVIM

IMAGING PERFORMED BY

Brian Klug

HOSPITAL NAME

Sondel Family VC

REFERRING VET

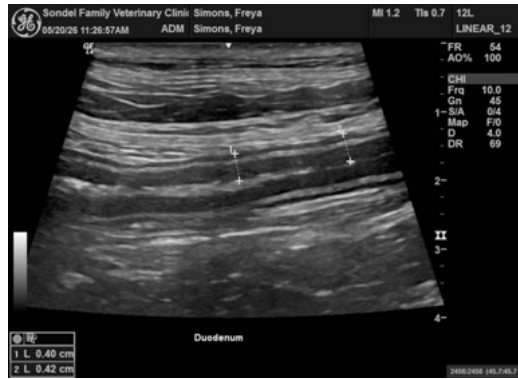Dr. Wallisch

INVOICE

77780

DATE

5/20/26



The information and recommendations provided are based on the images presented by the referring veterinarian/sonographer. No evaluation can be communicated regarding pathology that was not visible in the image/video clips provided.

Thank you for this referral. If the clinical or image interpretation does not parallel your findings or if I can be of any further assistance please contact me.

Remo Lobetti, BVSc, MMedVet (Med), PhD, Dipl. ECVIM (Internal Medicine)

info@sonopath.com