

PATIENT

Bubbles Glasgow

SPECIES

Canine

BREED

Beagle

SEX

Spayed female

AGE

12 years

WEIGHT

20.2 lbs

INTERPRETED BY

Remo Lobetti, BVSc,
MMedVet (Med), PhD,
Dipl. ECVIM (Internal
Medicine)

IMAGING PERFORMED BY

Denise Bruno, LVT,
RDMS

HOSPITAL NAME

Kenilworth AH

REFERRING VET

Dr. Mansour

INVOICE

77701

DATE

5/19/26

PRESENTING CLINICAL SIGNS

History: Globulin ^ 4.3 (1.6-3.6), vomiting yellow, low appetite. Labs attached

ULTRASONOGRAPHIC EXAMINATION OF THE ABDOMEN

Urinary System

The urinary bladder is small with a normal thickness and smooth appearance of the wall. Normal anechoic urine with no sediment or uroliths evident.

Normal appearance of the trigone area, proximal urethra (0.3 cm), and iliac blood vessels.

Normal appearance and size of the iliac lymph nodes. Ureters not visualized, which can be considered a normal finding.

Normal renal size, architecture, echogenic appearance, cortico-medullary differentiation, which maintains a 1:3 cortex to medulla ratio, pelvis, and capsule. No infarcts, mineralization or renoliths evident. Incidental, small cortical cysts are present in the right kidney. The left kidney measured 4.9 cm. The right kidney measured 5.3 cm.

Adrenal Glands

Normal shape, echogenic appearance, size, position, and appearance of the visible peri-adrenal vasculature. The left adrenal gland measured 2.07 cm in length x 0.68 cm and 0.57 cm in width. The right adrenal gland measured 2.01 cm in length x 0.65 cm and 0.58 cm in width.

Spleen

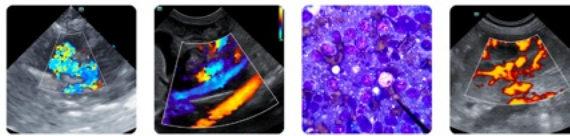
The spleen is folded on itself, with a normal size and echogenic appearance. Smooth homogenous parenchyma and regular curvilinear capsule. Normal volume of the splenic vasculature without any overt congestion or thrombosis evident. No inflammatory, neoplastic, infarction, or infiltrative changes evident. The spleen measured 1.8 cm in width.

Liver

Normal size, echogenic appearance, portal markings, and regular curvilinear capsule. No nodules or masses evident. Normal appearance of the hepatic and portal vasculature.

Gallbladder

The gallbladder is full containing a small amount of non-adhered, hyperechogenic sediment. Normal thickness and echogenic appearance of the wall. Normal size and appearance of the cystic and common bile duct.



PATIENT

Bubbles Glasgow

SPECIES

Canine

BREED

Beagle

SEX

Spayed female

AGE

12 years

WEIGHT

20.2 lbs

INTERPRETED BY

Remo Lobetti, BVSc,
MMedVet (Med), PhD,
Dipl. ECVIM (Internal
Medicine)

**IMAGING
PERFORMED BY**

Denise Bruno, LVT,
RDMS

HOSPITAL NAME

Kenilworth AH

REFERRING VET

Dr. Mansour

INVOICE

77701

DATE

5/19/26

Gastrointestinal

Normal appearance of the stomach, duodenum, small intestine, ileo-cecal junction, and colon with no loss of layering, 1:3 muscularis to mucosa ratio, normal wall thickness and peristaltic activity, and no distension of the lumen. The small intestine measured up to 0.49 cm.

Pancreas

The visible sections of the pancreas are of normal size and echogenic appearance with a regular capsule. Normal echogenic appearance of the mesentery and fat surrounding the pancreas.

Free Abdomen

Normal mesenteric lymph nodes.

No ascites evident.

ULTRASONOGRAPHIC FINDINGS

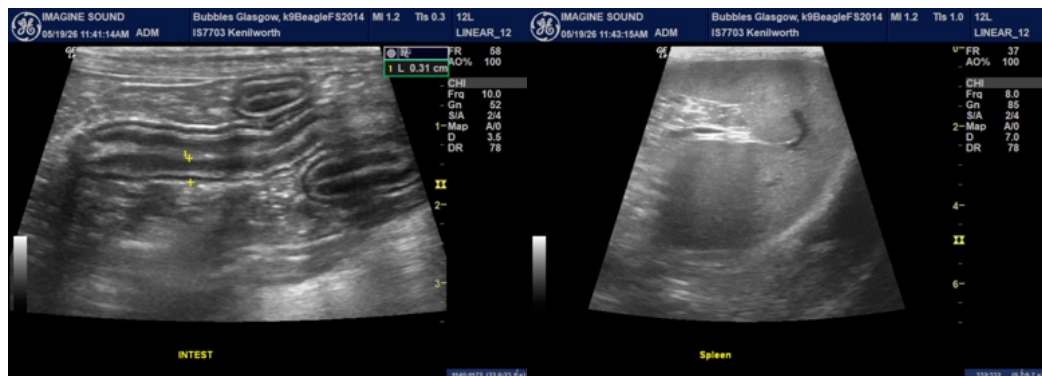
- Gallbladder sediment.

INTERPRETATION OF THE FINDINGS & FURTHER RECOMMENDATIONS

In essence a normal ultrasound examination of the abdomen as the gallbladder sediment can be considered an incidental finding.

With the hypocalcemia and hyperphosphatemia evident on blood work, primary hypoparathyroidism needs to be considered and followed up with a PTH assay.

Specific therapy would be dependent on an etiological diagnosis.





PATIENT

Bubbles Glasgow

SPECIES

Canine

BREED

Beagle

SEX

Spayed female

AGE

12 years

WEIGHT

20.2 lbs

INTERPRETED BY

Remo Lobetti, BVSc,
MMedVet (Med), PhD,
Dipl. ECVIM (Internal
Medicine)

IMAGING PERFORMED BY

Denise Bruno, LVT,
RDMS

HOSPITAL NAME

Kenilworth AH

REFERRING VET

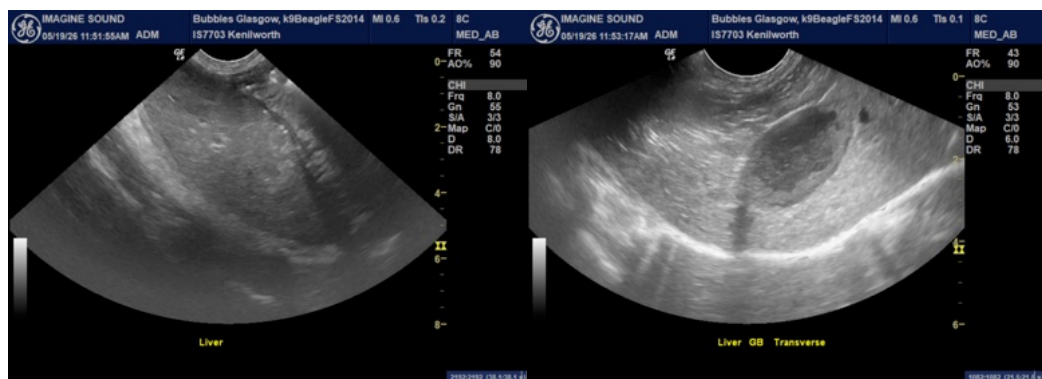
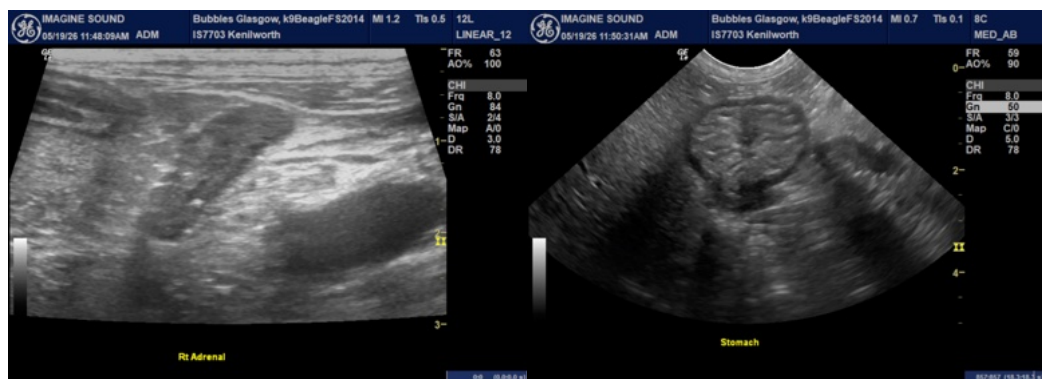
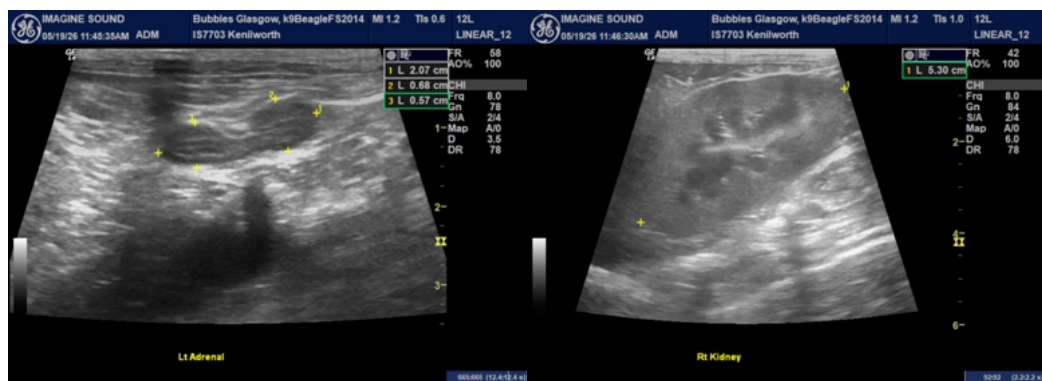
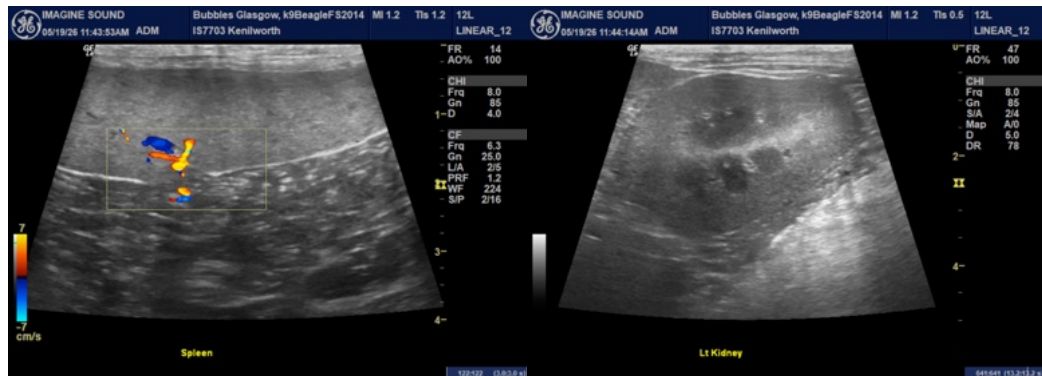
Dr. Mansour

INVOICE

77701

DATE

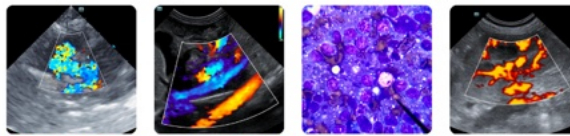
5/19/26



Imaging
performed by



dbimagesound@gmail.com
917-647-4318



Clinical Sonography & Telecytology
Educational Teleconsultation Services™

SonoPath

FOSTERING THE ART OF VETERINARY MEDICINE™

SonoPath.com info@sonopath.com 1.800.838.4268

PATIENT

Bubbles Glasgow

SPECIES

Canine

BREED

Beagle

SEX

Spayed female

AGE

12 years

WEIGHT

20.2 lbs

INTERPRETED BY

Remo Lobetti, BVSc,
MMedVet (Med), PhD,
Dipl. ECVIM (Internal
Medicine)

IMAGING PERFORMED BY

Denise Bruno, LVT,
RDMS

HOSPITAL NAME

Kenilworth AH

REFERRING VET

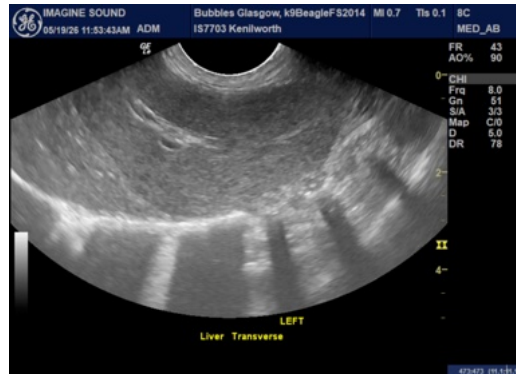
Dr. Mansour

INVOICE

77701

DATE

5/19/26



The information and recommendations provided are based on the images presented by the referring veterinarian/sonographer. No evaluation can be communicated regarding pathology that was not visible in the image/video clips provided.

Thank you for this referral. If the clinical or image interpretation does not parallel your findings or if I can be of any further assistance please contact me.

Remo Lobetti, BVSc, MMedVet (Med), PhD, Dipl. ECVIM (Internal Medicine)

info@sonopath.com