



## PATIENT

Ace Ricart

## SPECIES

Canine

## BREED

Australian Shepherd

## SEX

Neutered male

## AGE

10 years

## WEIGHT

51 lbs

## INTERPRETED BY

Remo Lobetti, BVSc,  
MMedVet (Med),  
PhD, Dipl. ECVIM

## IMAGING PERFORMED BY

Jessica Milligan, DVM

## HOSPITAL NAME

Dockside Veterinary  
Imaging

## REFERRING VET

Dr. Mercak

## INVOICE

77676

## DATE

5/19/26

## PRESENTING CLINICAL SIGNS

History: Elevated liver enzymes, slight anemia. Random seizures, decreased appetite.  
ALT 431, AST 84, ALP 398, glob 4.4, alb 2.6. HCT 39.6, Hgb 13.2 (all values from 5-10-26)

## ULTRASONOGRAPHIC EXAMINATION OF THE ABDOMEN

### *Urinary System*

The urinary bladder is small with a normal thickness and smooth appearance of the wall. Normal anechoic urine with no sediment or uroliths evident.

Normal appearance of the trigone area, proximal urethra, and iliac blood vessels.

Normal appearance and size of the iliac lymph nodes. Ureters not visualized, which can be considered a normal finding.

Normal renal size (left measured 6.2 cm, right measured 5.5 cm), architecture, echogenic appearance, cortico-medullary differentiation, which maintains a 1:3 cortex to medulla ratio, pelvis, and capsule. No infarcts, mineralization or renoliths evident. Normal color flow pattern is evident in both kidneys.

The prostate is small and hypoechogenic measuring 0.9 cm in width.

### *Adrenal Glands*

Normal shape, echogenic appearance, size, position, and appearance of the visible peri-adrenal vasculature. Left adrenal gland measured 0.41 cm and 0.47 cm in width. The right adrenal gland measured 0.51 cm and 0.53 cm in width.

### *Spleen*

Normal size and echogenic appearance. Smooth homogenous parenchyma and regular curvilinear capsule. Normal volume of the splenic vasculature without any overt congestion or thrombosis evident. No inflammatory, neoplastic, infarction, or infiltrative changes evident. The spleen measured 1.4 cm in width.

### *Liver*

Normal size with a diffuse, mottled echogenic and coarse appearance, normal portal markings, and regular curvilinear capsule. No nodules or masses evident. Normal appearance of the hepatic and portal vasculature. A small amount of fluid is evident between the liver lobes.



## PATIENT

Ace Ricart

## SPECIES

Canine

## BREED

Australian Shepherd

## SEX

Neutered male

## AGE

10 years

## WEIGHT

51 lbs

## INTERPRETED BY

Remo Lobetti, BVSc,  
MMedVet (Med),  
PhD, Dipl. ECVIM

## IMAGING PERFORMED BY

Jessica Milligan, DVM

## HOSPITAL NAME

Dockside Veterinary  
Imaging

## REFERRING VET

Dr. Mercak

## INVOICE

77676

## DATE

5/19/26

## ***Gallbladder***

The gallbladder is full containing normal anechoic bile. Normal thickness and echogenic appearance of the wall. Normal size and appearance of the cystic and common bile duct.

## ***Gastrointestinal***

Normal appearance of the stomach, duodenum, small intestine, ileo-cecal junction, and colon with no loss of layering, 1:3 muscularis to mucosa ratio, normal wall thickness and peristaltic activity, and no distension of the lumen. Fecal material was present in the colon.

## ***Pancreas***

The visible sections of the pancreas are of normal size and echogenic appearance with a regular capsule. Normal echogenic appearance of the mesentery and fat surrounding the pancreas.

## ***Free Abdomen***

Normal mesenteric lymph nodes.

No ascites evident.

## **ULTRASONOGRAPHIC FINDINGS**

- Hepatopathy

## **INTERPRETATION OF THE FINDINGS & FURTHER RECOMMENDATIONS**

Etiologies for the hepatopathy would be reactive hyperplasia, early nodular hyperplasia, chronic active hepatitis with vacuolar, metabolic and infiltrative neoplasia a less likely differential diagnosis.

Further assessment would be based on the pending results; however, a tru cut or wedge biopsy of the liver may be required for a final etiological diagnosis.

Specific therapy would be dependent on an etiological diagnosis.

Symptomatic management that can be considered would be the use of Ursodiol with regular monitoring of liver enzyme activity.



**PATIENT**

Ace Ricart

**SPECIES**

Canine

**BREED**

Australian Shepherd

**SEX**

Neutered male

**AGE**

10 years

**WEIGHT**

51 lbs

**INTERPRETED BY**

Remo Lobetti, BVSc,  
MMedVet (Med),  
PhD, Dipl. ECVIM

**IMAGING  
PERFORMED BY**

Jessica Milligan, DVM

**HOSPITAL NAME**

Dockside Veterinary  
Imaging

**REFERRING VET**

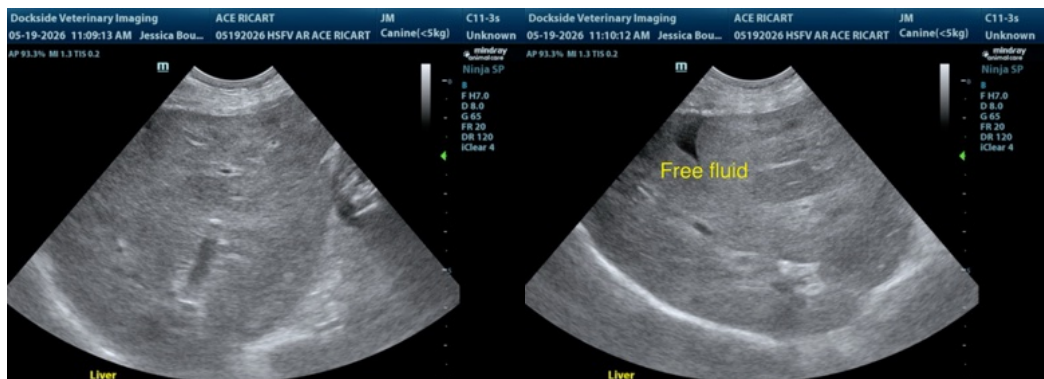
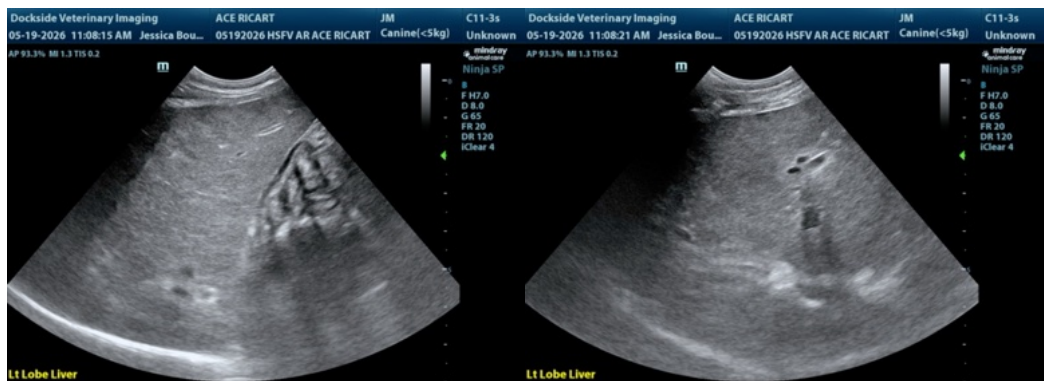
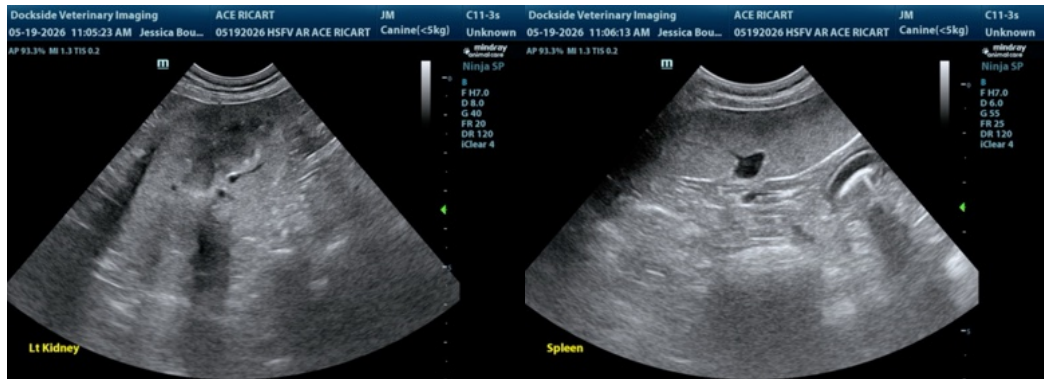
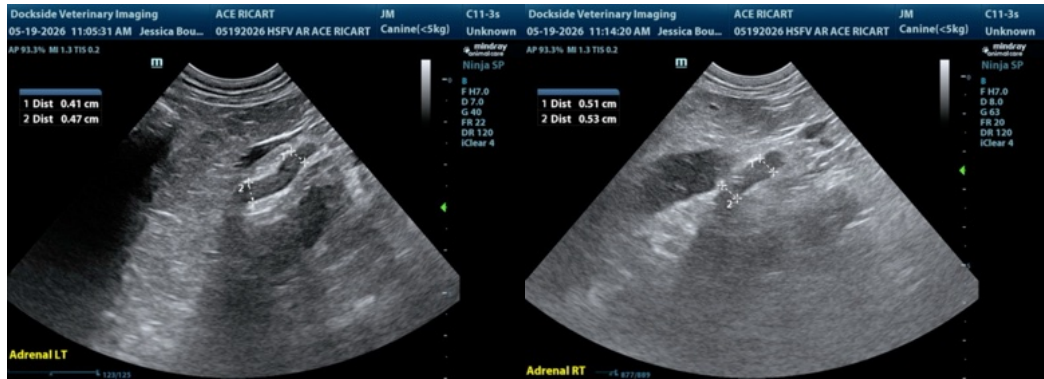
Dr. Mercak

**INVOICE**

77676

**DATE**

5/19/26





## PATIENT

Ace Ricart

## SPECIES

Canine

## BREED

Australian Shepherd

## SEX

Neutered male

## AGE

10 years

## WEIGHT

51 lbs

## INTERPRETED BY

Remo Lobetti, BVSc,  
MMedVet (Med),  
PhD, Dipl. ECVIM

## IMAGING PERFORMED BY

Jessica Milligan, DVM

## HOSPITAL NAME

Dockside Veterinary  
Imaging

## REFERRING VET

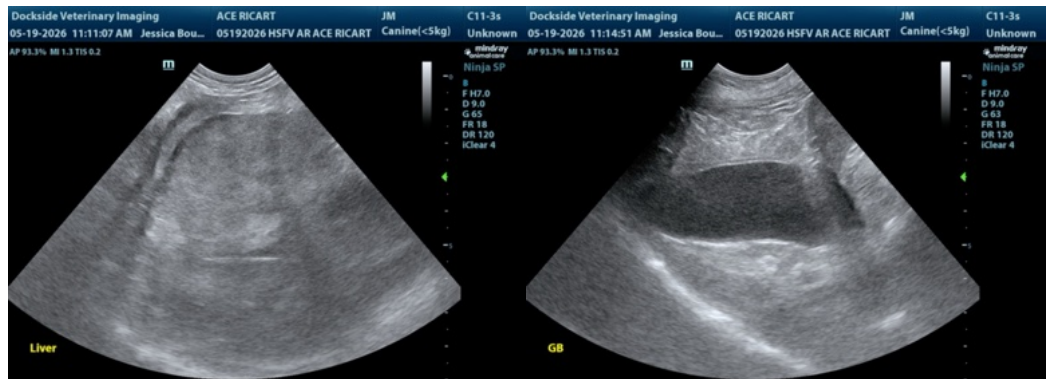
Dr. Mercak

## INVOICE

77676

## DATE

5/19/26



The information and recommendations provided are based on the images presented by the referring veterinarian/sonographer. No evaluation can be communicated regarding pathology that was not visible in the image/video clips provided.

Thank you for this referral. If the clinical or image interpretation does not parallel your findings or if I can be of any further assistance please contact me.

Remo Lobetti, BVSc, MMedVet (Med), PhD, Dipl. ECVIM (Internal Medicine)

[info@sonopath.com](mailto:info@sonopath.com)