



PATIENT

Skye Duffin

SPECIES

Canine

BREED

Belgian Malinois

SEX

Spayed female

AGE

9 years

WEIGHT

46.8 lbs

INTERPRETED BY

Remo Lobetti, BVSc,
MMedVet (Med),
PhD, Dipl. ECVIM

IMAGING PERFORMED BY

Dr. Michelle

HOSPITAL NAME

Southkent VH

REFERRING VET

Dr. Seneker

INVOICE

77621

DATE

5/18/26

PRESENTING CLINICAL SIGNS

History: Diarrhea, vomiting, weight loss, ADR
Abnormal PE/Chem/CBC/UA Results: Loss of serosal detail on abdominal x-rays, a lot of gas, abnormal area near spleen CBC/Chemistry WNL

ULTRASONOGRAPHIC EXAMINATION OF THE ABDOMEN

Urinary System

The urinary bladder is small with a normal thickness and smooth appearance of the wall. Normal anechoic urine with no sediment or uroliths evident.

Normal appearance of the trigone area, proximal urethra, and iliac blood vessels.

Normal appearance and size of the iliac lymph nodes. Ureters not visualized, which can be considered a normal finding.

Normal renal size (left measured 4.9 cm, right measured 4.7 cm), architecture, echogenic appearance, cortico-medullary differentiation, which maintains a 1:3 cortex to medulla ratio, pelvis, and capsule. No infarcts, mineralization or renoliths evident. Normal color flow pattern is evident in both kidneys.

Adrenal Glands

The left adrenal gland is normal in shape, echogenic appearance, size, position, and appearance of the visible peri-adrenal vasculature. Left adrenal gland measured 1.13 cm in length x 0.41 cm in width. The right adrenal gland was not visualized.

Spleen

A mottled echogenic appearance of the head of the spleen with a hyperechogenic appearance of the mesentery surrounding the head as well as a small amount of fluid accumulation. The rest of the spleen is of normal size (2.6 cm in width) maintaining a normal echogenic appearance, smooth homogenous parenchyma and regular curvilinear capsule. Normal volume of the splenic vasculature without any overt congestion or thrombosis evident.

Liver

Normal size, echogenic appearance, portal markings, and regular curvilinear capsule. No nodules or masses evident. Normal appearance of the hepatic and portal vasculature.

Gallbladder

The gallbladder is small containing normal anechoic bile. Normal thickness and echogenic appearance of the wall. Normal size and appearance of the cystic and common bile duct.



PATIENT

Gastrointestinal

Skye Duffin

Normal appearance of the stomach, duodenum, small intestine, ileo-cecal junction, and colon with no loss of layering, 1:3 muscularis to mucosa ratio, normal wall thickness and peristaltic activity, and no distension of the lumen.

SPECIES

Canine

BREED

Belgian Malinois

Pancreas

The pancreas is not clearly visualized, but the visualized sections of the pancreas are of normal size and echogenic appearance with a regular capsule. Normal echogenic appearance of the mesentery and fat surrounding the pancreas.

SEX

Spayed female

Free Abdomen

Normal mesenteric lymph nodes.

AGE

9 years

No ascites evident.

WEIGHT

46.8 lbs

ULTRASONOGRAPHIC FINDINGS

- Focal splenic pathology.

INTERPRETED BY

Remo Lobetti, BVSc,
MMedVet (Med),
PhD, Dipl. ECVIM

INTERPRETATION OF THE FINDINGS & FURTHER RECOMMENDATIONS

Etiologies for the splenic pathology would be reactive hyperplasia, focal splenitis, granulomatous disease and possibly emerging neoplasia.

IMAGING PERFORMED BY

Dr. Michelle

Although the visible section of the pancreas appears ultrasonographically normal, with the presenting clinical signs, pancreatitis should still be considered.

HOSPITAL NAME

Southkent VH

Further assessment would be CPL/PSL assay, FNA cytology of the head of the spleen and if possible analysis of the acidic fluid.

REFERRING VET

Dr. Seneker

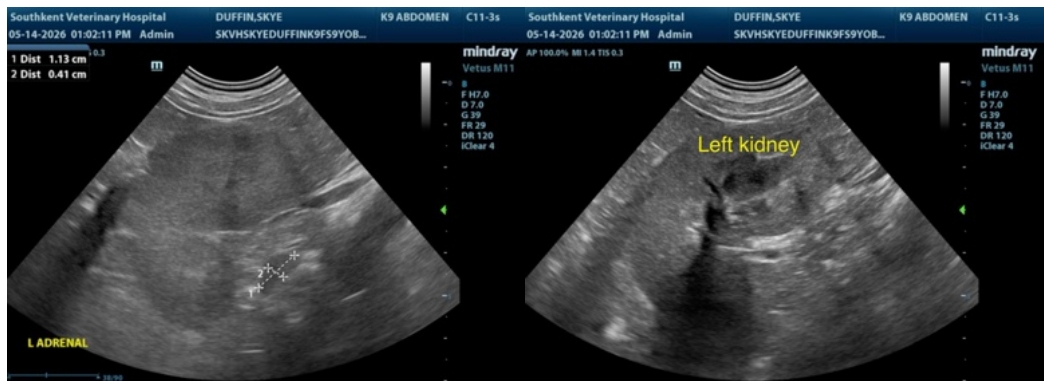
Specific therapy would be dependent on an etiological diagnosis.

INVOICE

77621

DATE

5/18/26





PATIENT

Skye Duffin

SPECIES

Canine

BREED

Belgian Malinois

SEX

Spayed female

AGE

9 years

WEIGHT

46.8 lbs

INTERPRETED BY

Remo Lobetti, BVSc,
MMedVet (Med),
PhD, Dipl. ECVIM

IMAGING PERFORMED BY

Dr. Michelle

HOSPITAL NAME

Southkent VH

REFERRING VET

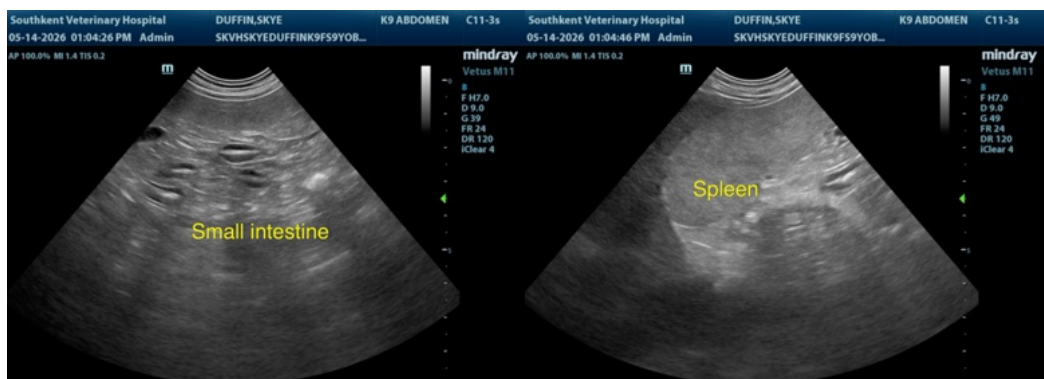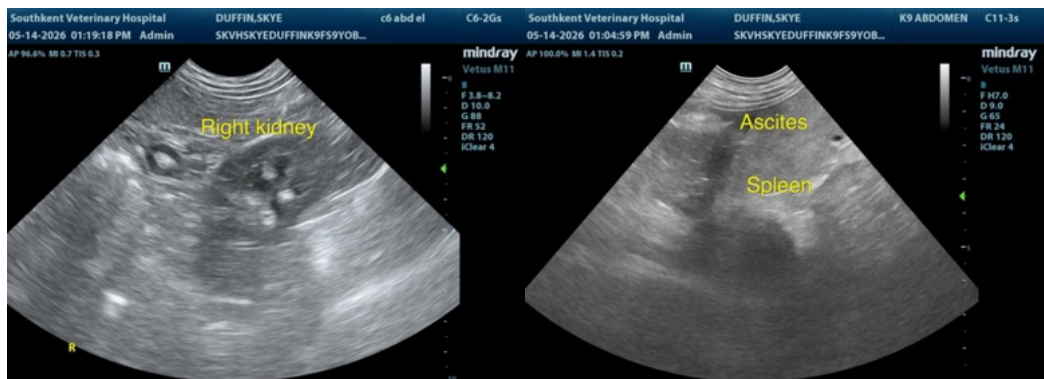
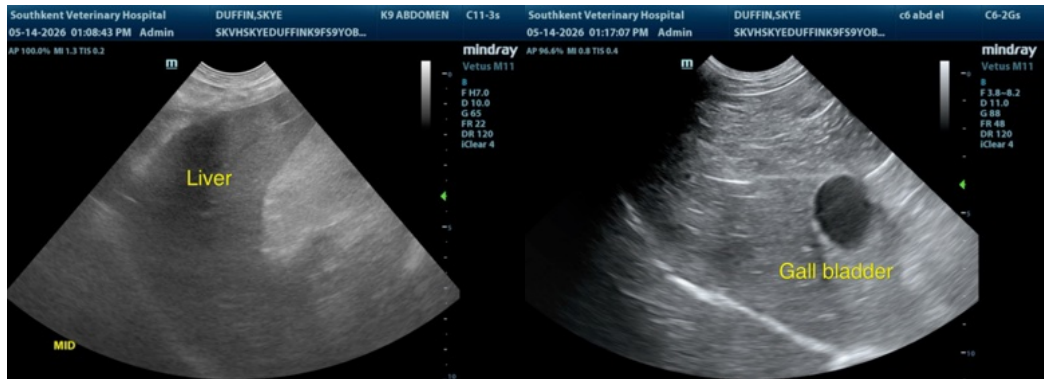
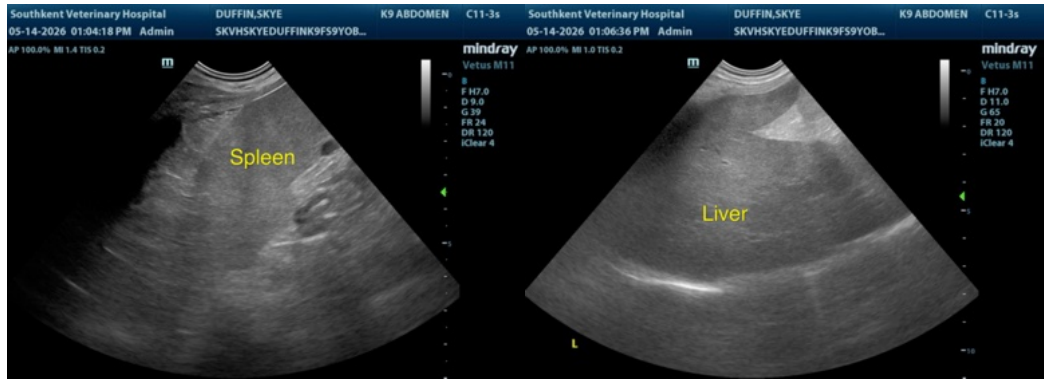
Dr. Seneker

INVOICE

77621

DATE

5/18/26





PATIENT

Skye Duffin

SPECIES

Canine

BREED

Belgian Malinois

SEX

Spayed female

AGE

9 years

WEIGHT

46.8 lbs

INTERPRETED BY

Remo Lobetti, BVSc,
MMedVet (Med),
PhD, Dipl. ECVIM

IMAGING PERFORMED BY

Dr. Michelle

HOSPITAL NAME

Southkent VH

REFERRING VET

Dr. Seneker

INVOICE

77621

DATE

5/18/26

The information and recommendations provided are based on the images presented by the referring veterinarian/sonographer. No evaluation can be communicated regarding pathology that was not visible in the image/video clips provided.

Thank you for this referral. If the clinical or image interpretation does not parallel your findings or if I can be of any further assistance please contact me.

Remo Lobetti, BVSc, MMedVet (Med), PhD, Dipl. ECVIM (Internal Medicine)

info@sonopath.com