



PATIENT

Rigby Wease

SPECIES

Canine

BREED

Husky

SEX

Spayed female

AGE

9 years

WEIGHT

66 lbs

INTERPRETED BY

Remo Lobetti, BVSc,
MMedVet (Med),
PhD, Dipl. ECVIM

IMAGING PERFORMED BY

Rachel Bunn, DVM

HOSPITAL NAME

Wellesley AH

REFERRING VET

Dr. Bunn

INVOICE

75583

DATE

5/15/26

PRESENTING CLINICAL SIGNS

History: Generally healthy canine. Owner has noticed some recent clumsiness jumping on/off couch or stairs. No specific hyperpathia noted & normal hind CP responses.

Abnormal PE/Chem/CBC/UA Results: ALT elevation (137 U/L) first noticed May 2025. Recheck in May 2026 shows ALT 224 U/L and ALP 162 U/L. Normal LFTs & CBC. No updated urine but in 2025 USG 1.028, pH \geq 9, and 1+ MAP crystals. Normal T4. Chronic anaplasma positive

ULTRASONOGRAPHIC EXAMINATION OF THE ABDOMEN

Urinary System

The urinary bladder is small with a normal thickness and smooth appearance of the wall. Normal anechoic urine with no sediment or uroliths evident.

Normal appearance of the trigone area, proximal urethra, and iliac blood vessels.

Normal appearance and size of the iliac lymph nodes. Ureters not visualized, which can be considered a normal finding.

Normal renal size (left measured 6.1 cm, right measured 6.2 cm), architecture, echogenic appearance, cortico-medullary differentiation, which maintains a 1:3 cortex to medulla ratio, pelvis, and capsule. No infarcts, mineralization or renoliths evident. Normal color flow pattern is evident in both kidneys.

Adrenal Glands

The left adrenal gland is normal in shape, echogenic appearance, size, position, and appearance of the visible peri-adrenal vasculature. Left adrenal gland measured 2.81 cm in length x 0.42 cm and 0.41 cm in width. The right adrenal gland was not clearly visualized, but appears to be of normal shape, echogenic appearance and size.

Spleen

Normal size and echogenic appearance. Smooth homogenous parenchyma and regular curvilinear capsule. Normal volume of the splenic vasculature without any overt congestion or thrombosis evident. No inflammatory, neoplastic, infarction, or infiltrative changes evident. The spleen measured 2.6 cm in width.

Liver

Normal size, echogenic appearance, portal markings, and regular curvilinear capsule. No nodules or masses evident. Normal appearance of the hepatic and portal vasculature.



PATIENT

Rigby Wease

SPECIES

Canine

BREED

Husky

SEX

Spayed female

AGE

9 years

WEIGHT

66 lbs

INTERPRETED BY

Remo Lobetti, BVSc,
MMedVet (Med),
PhD, Dipl. ECVIM

IMAGING PERFORMED BY

Rachel Bunn, DVM

HOSPITAL NAME

Wellesley AH

REFERRING VET

Dr. Bunn

INVOICE

75583

DATE

5/15/26

Gallbladder

The gallbladder is small containing normal anechoic bile. Normal thickness and echogenic appearance of the wall. Normal size and appearance of the cystic and common bile duct.

Gastrointestinal

Normal appearance of the stomach, duodenum, small intestine, ileo-cecal junction, and colon with no loss of layering, 1:3 muscularis to mucosa ratio, normal wall thickness and peristaltic activity, and no distension of the lumen.

Pancreas

The visible sections of the pancreas are of normal size and echogenic appearance with a regular capsule. Normal echogenic appearance of the mesentery and fat surrounding the pancreas.

Free Abdomen

Normal mesenteric lymph nodes.

No ascites evident.

ULTRASONOGRAPHIC FINDINGS

- Normal ultrasound examination of the abdomen.

INTERPRETATION OF THE FINDINGS & FURTHER RECOMMENDATIONS

Although the liver appears ultrasonographically normal, with the progressive, mild elevation of liver enzyme activity etiologies to consider would be reactive hyperplasia, early nodular hyperplasia, vacuolar and metabolic.

Hepatitis and infiltrative neoplasia would be highly unlikely differential diagnosis.

Further assessment that could be considered would be FNA cytology of the liver; however, tru cut or wedge biopsy may be required for a finale etiological diagnosis.

Specific therapy would be dependent on an etiological diagnosis.

Symptomatic management that could be considered would be the use of Ursodiol with regular monitoring of liver enzyme activity.



PATIENT

Rigby Wease

SPECIES

Canine

BREED

Husky

SEX

Spayed female

AGE

9 years

WEIGHT

66 lbs

INTERPRETED BY

Remo Lobetti, BVSc,
MMedVet (Med),
PhD, Dipl. ECVIM

**IMAGING
PERFORMED BY**

Rachel Bunn, DVM

HOSPITAL NAME

Wellesley AH

REFERRING VET

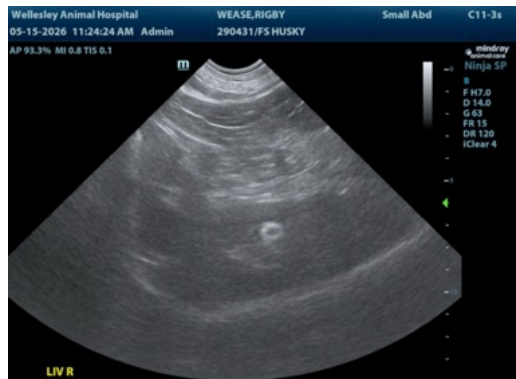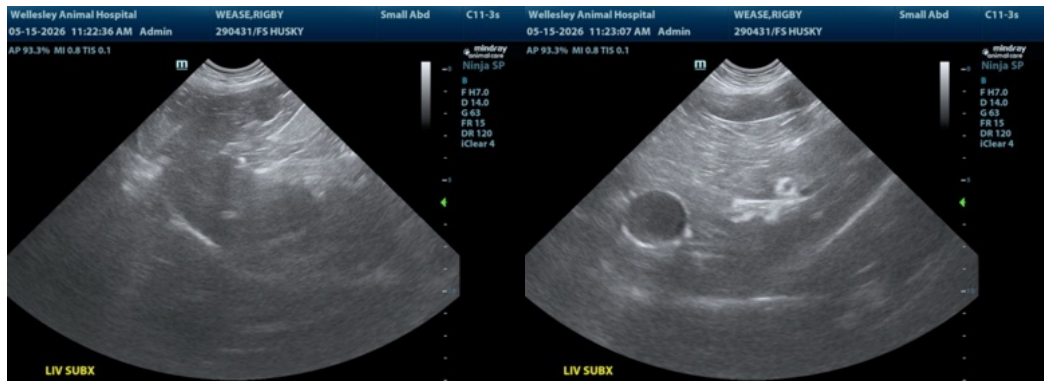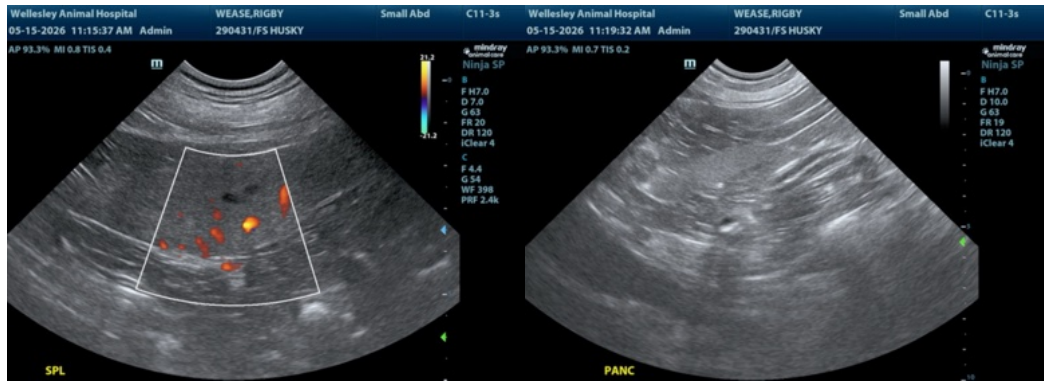
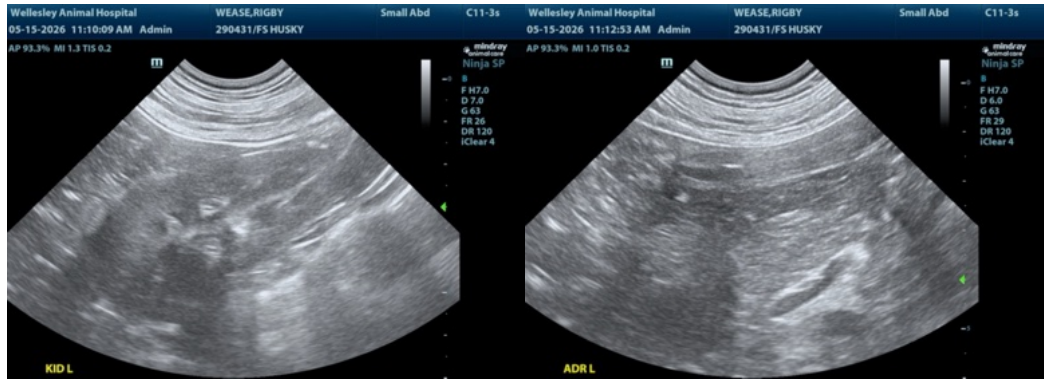
Dr. Bunn

INVOICE

75583

DATE

5/15/26





PATIENT

Rigby Wease

SPECIES

Canine

BREED

Husky

SEX

Spayed female

AGE

9 years

WEIGHT

66 lbs

INTERPRETED BY

Remo Lobetti, BVSc,
MMedVet (Med),
PhD, Dipl. ECVIM

IMAGING PERFORMED BY

Rachel Bunn, DVM

HOSPITAL NAME

Wellesley AH

REFERRING VET

Dr. Bunn

INVOICE

75583

DATE

5/15/26

The information and recommendations provided are based on the images presented by the referring veterinarian/sonographer. No evaluation can be communicated regarding pathology that was not visible in the image/video clips provided.

Thank you for this referral. If the clinical or image interpretation does not parallel your findings or if I can be of any further assistance please contact me.

Remo Lobetti, BVSc, MMedVet (Med), PhD, Dipl. ECVIM (Internal Medicine)

info@sonopath.com