



PATIENT

Dixie Browning

SPECIES

Canine

BREED

Hound Cross

SEX

Spayed female

AGE

9 ½ years

WEIGHT

64 lbs

INTERPRETED BY

Remo Lobetti, BVSc,
MMedVet (Med),
PhD, Dipl. ECVIM

IMAGING PERFORMED BY

Alison Cornwall

HOSPITAL NAME

Onion River AH

REFERRING VET

Dr. Cullman Clark

INVOICE

75573

DATE

5/15/26

PRESENTING CLINICAL SIGNS

History: PU/PD, concern for mass in abdomen.
Urine USG 1.002 otherwise NSF BW NSF in Oct 2025 before PU/PD started.

ULTRASONOGRAPHIC EXAMINATION OF THE ABDOMEN

Urinary System

The urinary bladder is full with a normal thickness and smooth appearance of the wall. Normal anechoic urine with no sediment or uroliths evident.

Normal appearance of the trigone area, proximal urethra, and iliac blood vessels.

Normal appearance and size of the iliac lymph nodes. Ureters not visualized, which can be considered a normal finding.

Normal renal size (left measured 6.1 cm, right measured 6.8 cm), architecture, echogenic appearance, cortico-medullary differentiation, which maintains a 1:3 cortex to medulla ratio, pelvis, and capsule. No infarcts, mineralization or renoliths evident. Normal color flow pattern is evident in both kidneys.

Adrenal Glands

Normal shape, echogenic appearance, size, position, and appearance of the visible peri-adrenal vasculature. Left adrenal gland measured 2.78 cm in length x 0.7 and 0.74 cm in width. The right adrenal gland measured 0.72 cm in width.

Spleen

Normal size and echogenic appearance. Smooth homogenous parenchyma and regular curvilinear capsule. Normal volume of the splenic vasculature without any overt congestion or thrombosis evident. No inflammatory, neoplastic, infarction, or infiltrative changes evident. The spleen measured 2.7 cm in width.

Liver

Normal size, echogenic appearance, portal markings, and regular curvilinear capsule. No nodules or masses evident. Normal appearance of the hepatic and portal vasculature.

Gallbladder

The gallbladder is full containing a scant amount of non-adhered, hyperechogenic sediment. Normal thickness and echogenic appearance of the wall. Normal size and appearance of the cystic and common bile duct.



PATIENT

Dixie Browning

SPECIES

Canine

BREED

Hound Cross

SEX

Spayed female

AGE

9 ½ years

WEIGHT

64 lbs

INTERPRETED BY

Remo Lobetti, BVSc,
MMedVet (Med),
PhD, Dipl. ECVIM

IMAGING PERFORMED BY

Alison Cornwall

HOSPITAL NAME

Onion River AH

REFERRING VET

Dr. Cullman Clark

INVOICE

75573

DATE

5/15/26

Gastrointestinal

Normal appearance of the stomach, duodenum, small intestine, ileo-cecal junction, and colon with no loss of layering, 1:3 muscularis to mucosa ratio, normal wall thickness and peristaltic activity, and no distension of the lumen.

Pancreas

The visible sections of the pancreas are of normal size and echogenic appearance with a regular capsule. Normal echogenic appearance of the mesentery and fat surrounding the pancreas.

Free Abdomen

Normal mesenteric lymph nodes.

No ascites evident.

Thorax

Normal appearance of the heart. No pericardial or pleural effusion evident.

ULTRASONOGRAPHIC FINDINGS

- Normal ultrasound examination of the abdomen.

INTERPRETATION OF THE FINDINGS & FURTHER RECOMMENDATIONS

On this ultrasound there is no obvious etiology for the PU/PD.

Possible etiologies for the PuPd would be partial central diabetes insipidus, psychogenic polydipsia, medullary solute wash-out, neurological disease, and severely protein-restricted diet. Further assessment could include dietary history, quantification of water intake, measurement/calculation of serum osmolality, neurological exam, and a modified water deprivation test; the latter only done if renal function is normal.

Serum osmolality can be calculated as follows, with the presence of low osmolality supportive of primary polydipsia:

$$\text{Osmolality (mOsm/kg)} = 2 \times \text{sodium} + \text{glucose (mg/dL)}/18 + \text{BUN (mg/dL)}/2.8.$$

Normal reference range: 290-310

Modified water deprivation test: Start with 120mls/kg water per day for 2-3 days; then reduce to 80mls/kg for 2-3 days; then reduce to 60mls/kg for 2-3 days. During this period, increase the protein content of the diet (meat, cottage cheese). After that withhold food and water and monitor hematocrit, total solids, and SG. Continue until 5% dehydrated. If no improvement in SG, then administer vasopressin and continue monitoring the SG. If there is a marked improvement without having to administer



PATIENT

Dixie Browning

SPECIES

Canine

BREED

Hound Cross

SEX

Spayed female

AGE

9 ½ years

WEIGHT

64 lbs

INTERPRETED BY

Remo Lobetti, BVSc,
MMedVet (Med),
PhD, Dipl. ECVIM

IMAGING PERFORMED BY

Alison Cornwall

HOSPITAL NAME

Onion River AH

REFERRING VET

Dr. Cullman Clark

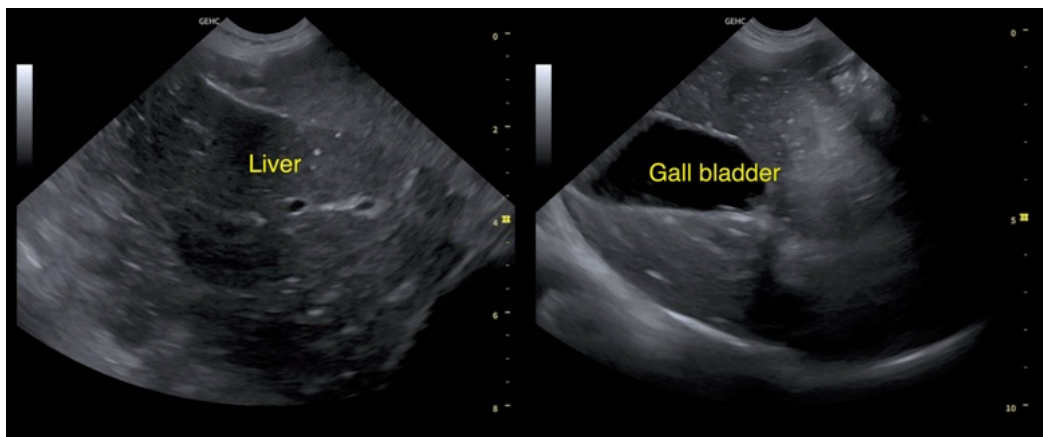
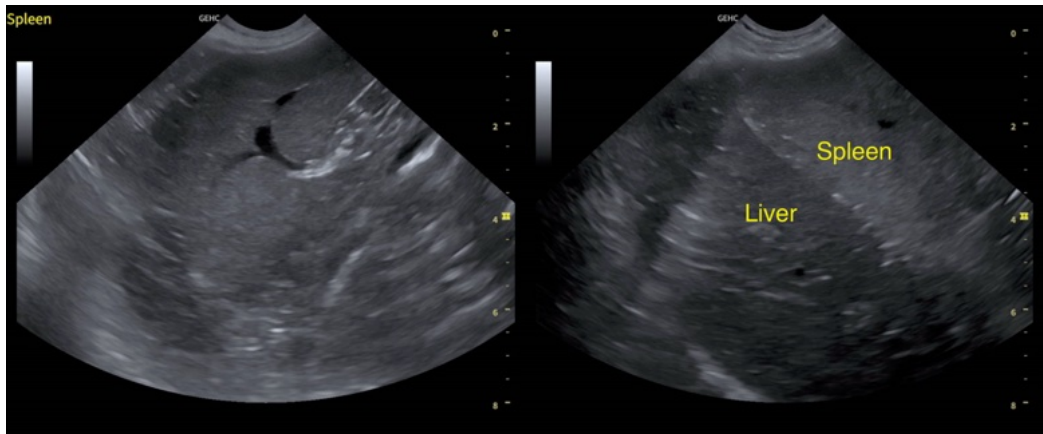
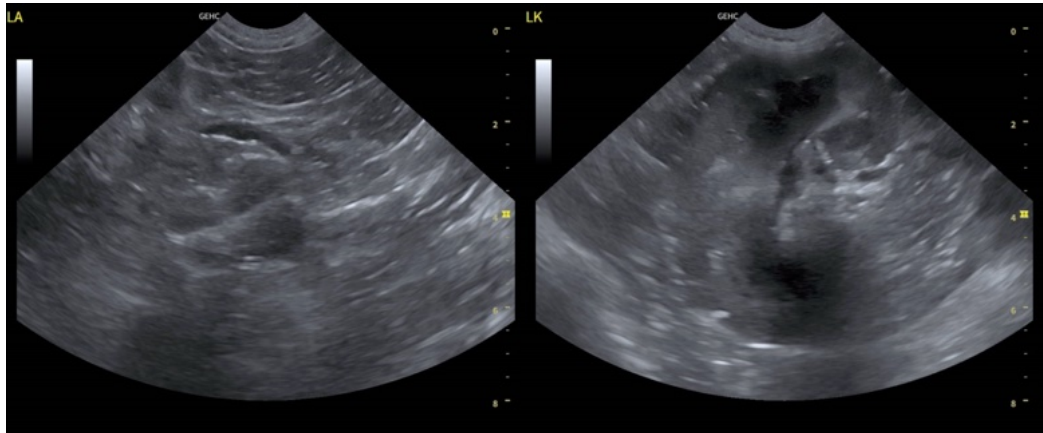
INVOICE

75573

DATE

5/15/26

vasopressin, then the diagnosis would be psychogenic polydipsia or medullary solute washout. If there is only an improvement after vasopressin has been administered, then the diagnosis would be partial central diabetes insipidus.





PATIENT

Dixie Browning

SPECIES

Canine

BREED

Hound Cross

SEX

Spayed female

AGE

9 ½ years

WEIGHT

64 lbs

INTERPRETED BY

Remo Lobetti, BVSc,
MMedVet (Med),
PhD, Dipl. ECVIM

IMAGING PERFORMED BY

Alison Cornwall

HOSPITAL NAME

Onion River AH

REFERRING VET

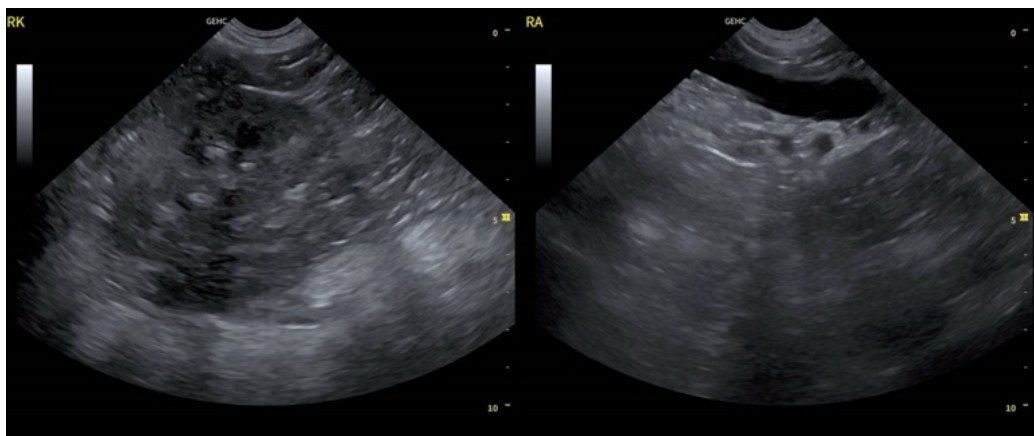
Dr. Cullman Clark

INVOICE

75573

DATE

5/15/26



The information and recommendations provided are based on the images presented by the referring veterinarian/sonographer. No evaluation can be communicated regarding pathology that was not visible in the image/video clips provided.

Thank you for this referral. If the clinical or image interpretation does not parallel your findings or if I can be of any further assistance please contact me.

Remo Lobetti, BVSc, MMedVet (Med), PhD, Dipl. ECVIM (Internal Medicine)

info@sonopath.com