



PATIENT

Sasha Myers

SPECIES

Canine

BREED

Husky

SEX

Spayed female

AGE

8 years

WEIGHT

42 lbs

INTERPRETED BY

Remo Lobetti, BVSc,
MMedVet (Med), PhD,
Dipl. ECVIM (Internal
Medicine)

IMAGING PERFORMED BY

Amy Isaac

HOSPITAL NAME

Valley West & Elk VH

REFERRING VET

Dr. Isaac

INVOICE

75475

DATE

5/14/26

PRESENTING CLINICAL SIGNS

History: History of hematuria with blood clots. WBC and RBC +++ in urine, bacteria seen with dilution. Responded well to Clavamox 250 mg PO BID for one week, but relapsed once meds were discontinued. Plan to culture once off antibiotics for at least one week.

Abnormal PE/Chem/CBC/UA Results: PE is normal. No abnormal findings on vaginal exam, slightly recessed vulva.

ULTRASONOGRAPHIC EXAMINATION OF THE ABDOMEN

Urinary System

The urinary bladder is small with a normal thickness and smooth appearance of the wall. Normal anechoic urine with no sediment or uroliths evident.

Normal appearance of the trigone area, proximal urethra, and iliac blood vessels.

Normal appearance and size of the iliac lymph nodes. Ureters not visualized, which can be considered a normal finding.

Normal renal size (left measured 5.8 cm, right measured 5.6 cm), architecture, echogenic appearance, cortico-medullary differentiation, which maintains a 1:3 cortex to medulla ratio, pelvis, and capsule. No infarcts, mineralization or renoliths evident. Normal color flow pattern is evident in both kidneys.

Adrenal Glands

The left adrenal gland is normal in shape, echogenic appearance, size, position, and appearance of the visible peri-adrenal vasculature. Left adrenal gland measured 0.45 cm in width. The right adrenal gland was not clearly visualized, but appears to be of normal shape, echogenic appearance and size.

Spleen

Normal size and echogenic appearance. Smooth homogenous parenchyma and regular curvilinear capsule. Normal volume of the splenic vasculature without any overt congestion or thrombosis evident. No inflammatory, neoplastic, infarction, or infiltrative changes evident. The spleen measured 1.5 cm in width.

Liver

Normal size, echogenic appearance, portal markings, and regular curvilinear capsule. No nodules or masses evident. Normal appearance of the hepatic and portal vasculature.



PATIENT

Sasha Myers

SPECIES

Canine

BREED

Husky

SEX

Spayed female

AGE

8 years

WEIGHT

42 lbs

INTERPRETED BY

Remo Lobetti, BVSc,
MMedVet (Med), PhD,
Dipl. ECVIM (Internal
Medicine)

IMAGING PERFORMED BY

Amy Isaac

HOSPITAL NAME

Valley West & Elk VH

REFERRING VET

Dr. Isaac

INVOICE

75475

DATE

5/14/26

Gallbladder

The gallbladder is full containing a small amount of non-adhered, hyperechogenic sediment. Normal thickness and echogenic appearance of the wall. Normal size and appearance of the cystic and common bile duct.

Gastrointestinal

Normal appearance of the stomach, duodenum, small intestine, ileo-cecal junction, and colon with no loss of layering, 1:3 muscularis to mucosa ratio, normal wall thickness and peristaltic activity, and no distension of the lumen.

Pancreas

The visible sections of the pancreas are of normal size and echogenic appearance with a regular capsule. Normal echogenic appearance of the mesentery and fat surrounding the pancreas.

Free Abdomen

Normal mesenteric lymph nodes.

No ascites evident.

ULTRASONOGRAPHIC FINDINGS

- Gallbladder sediment.

INTERPRETATION OF THE FINDINGS & FURTHER RECOMMENDATIONS

On this ultrasound there is no obvious etiology for the hematuria and urinary tract infection. The gallbladder sediment can be considered an incidental finding.

Further assessment would be urine culture.

Management would be antibiotic therapy based on urine culture and sensitivity results.



PATIENT

Sasha Myers

SPECIES

Canine

BREED

Husky

SEX

Spayed female

AGE

8 years

WEIGHT

42 lbs

INTERPRETED BY

Remo Lobetti, BVSc,
MMedVet (Med), PhD,
Dipl. ECVIM (Internal
Medicine)

**IMAGING
PERFORMED BY**

Amy Isaac

HOSPITAL NAME

Valley West & Elk VH

REFERRING VET

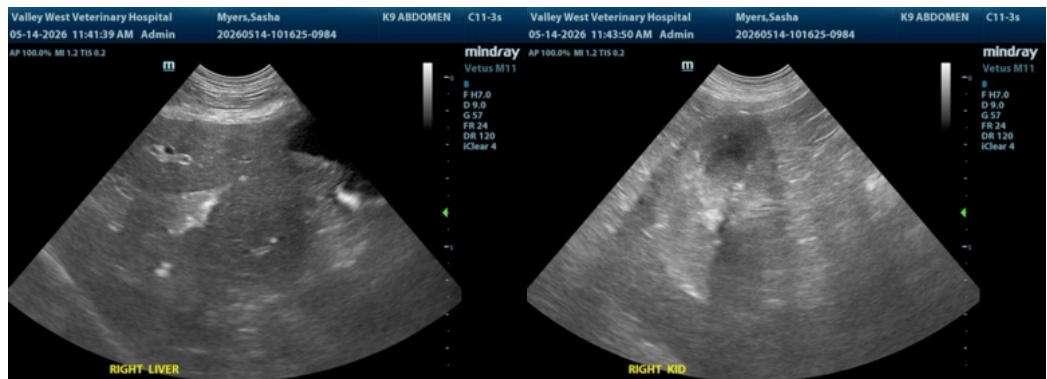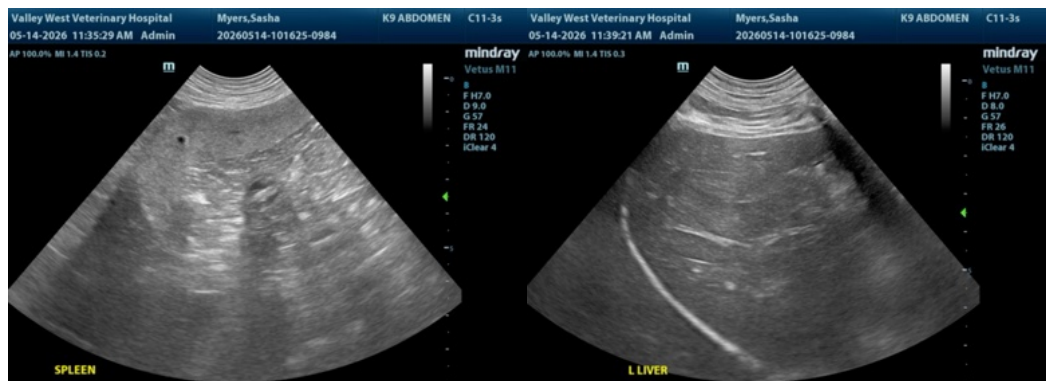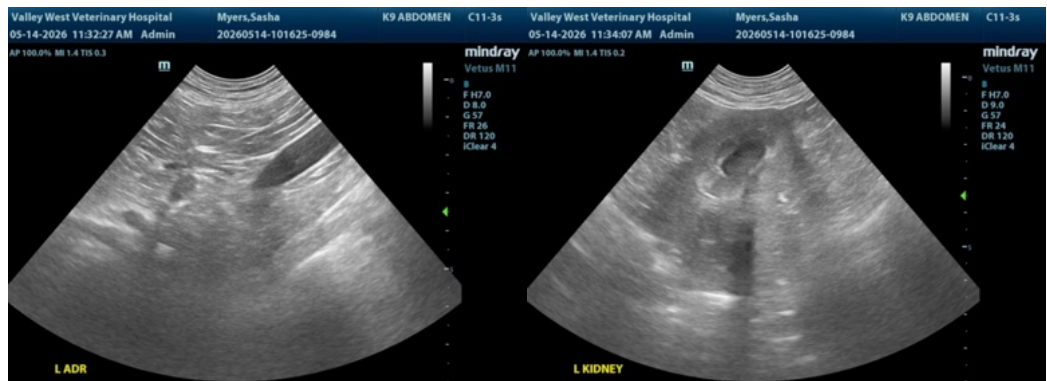
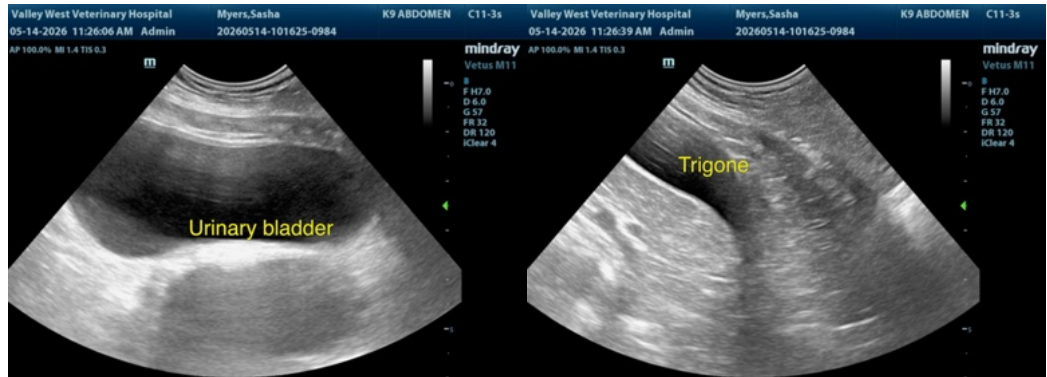
Dr. Isaac

INVOICE

75475

DATE

5/14/26





PATIENT

Sasha Myers

SPECIES

Canine

BREED

Husky

SEX

Spayed female

AGE

8 years

WEIGHT

42 lbs

INTERPRETED BY

Remo Lobetti, BVSc,
MMedVet (Med), PhD,
Dipl. ECVIM (Internal
Medicine)

IMAGING PERFORMED BY

Amy Isaac

HOSPITAL NAME

Valley West & Elk VH

REFERRING VET

Dr. Isaac

INVOICE

75475

DATE

5/14/26

The information and recommendations provided are based on the images presented by the referring veterinarian/sonographer. No evaluation can be communicated regarding pathology that was not visible in the image/video clips provided.

Thank you for this referral. If the clinical or image interpretation does not parallel your findings or if I can be of any further assistance please contact me.

Remo Lobetti, BVSc, MMedVet (Med), PhD, Dipl. ECVIM (Internal Medicine)

info@sonopath.com