



PATIENT

Madchen Adelaar

SPECIES

Canine

BREED

Mixed

SEX

Spayed female

AGE

10 years

WEIGHT

38.6 lbs

INTERPRETED BY

Remo Lobetti, BVSc,
MMedVet (Med),
PhD, Dipl. ECVIM

IMAGING PERFORMED BY

Dr. Heather Platzer

HOSPITAL NAME

Hershire AH

REFERRING VET

Dr. Erika Gallisdorfer

INVOICE

75495

DATE

5/13/26

PRESENTING CLINICAL SIGNS

History: Has had ultrasounds the last two years (5/1/24, and 1/15/25) - liver hypoechoic intraparenchymal nodules along with non-organized, mild gallbladder debris and Benign splenic nodules. Bloodwork monitoring every 6 months had been stable except for this bw were his values have increased further enzymes - ALT (334 was 265), ALP (1936 was 1,885) - recommended repeating ultrasound to monitor structural appearance of liver and GB changes

ULTRASONOGRAPHIC EXAMINATION OF THE ABDOMEN

Urinary System

The urinary bladder is full with a normal thickness and smooth appearance of the wall. Normal anechoic urine with no sediment or uroliths evident.

Normal appearance of the trigone area, proximal urethra, and iliac blood vessels.

Normal appearance and size of the iliac lymph nodes. Ureters not visualized, which can be considered a normal finding.

Normal renal size (left measured 5.8 cm, right measured 5.9 cm), architecture, echogenic appearance, cortico-medullary differentiation, which maintains a 1:3 cortex to medulla ratio, pelvis, and capsule. No infarcts, mineralization or renoliths evident. Normal color flow pattern is evident in both kidneys.

Adrenal Glands

Normal shape, echogenic appearance, size, position, and appearance of the visible peri-adrenal vasculature. Left adrenal gland measured 2.19 cm in length x 0.46 cm and 0.53 cm in width. The right adrenal gland measured 3.16 cm in length x 0.58 cm in width.

Spleen

Normal size and echogenic appearance. Smooth homogenous parenchyma and regular curvilinear capsule. Normal volume of the splenic vasculature without any overt congestion or thrombosis evident. Incidental myelolipomas were present. No inflammatory, neoplastic, infarction, or infiltrative changes evident. The spleen measured 2.1 cm in width.

Liver

Normal size with a diffuse, increased echogenic, coarse and nodular appearance, normal portal markings, and regular curvilinear capsule. Nodules are hypoechogenic, parenchymal and measure up to 0.7 x 1.5 cm in size. No masses evident. Normal appearance of the hepatic and portal vasculature.



PATIENT

Madchen Adelaar

SPECIES

Canine

BREED

Mixed

SEX

Spayed female

AGE

10 years

WEIGHT

38.6 lbs

INTERPRETED BY

Remo Lobetti, BVSc,
MMedVet (Med),
PhD, Dipl. ECVIM

IMAGING PERFORMED BY

Dr. Heather Platzer

HOSPITAL NAME

Hershire AH

REFERRING VET

Dr. Erika Gallisdorfer

INVOICE

75495

DATE

5/13/26

Gallbladder

The gallbladder is full containing a small amount of non-adhered hyperechogenic sediment. Normal thickness and echogenic appearance of the wall. Normal size and appearance of the cystic and common bile duct.

Gastrointestinal

Normal appearance of the stomach, duodenum, small intestine, ileo-cecal junction, and colon with no loss of layering, 1:3 muscularis to mucosa ratio, normal wall thickness and peristaltic activity, and no distension of the lumen.

Pancreas

The visible sections of the pancreas are of normal size and echogenic appearance with a regular capsule. Normal echogenic appearance of the mesentery and fat surrounding the pancreas.

Free Abdomen

Normal mesenteric lymph nodes.

No ascites evident.

ULTRASONOGRAPHIC FINDINGS

- Nodular hepatopathy.
- Gallbladder sediment.

INTERPRETATION OF THE FINDINGS & FURTHER RECOMMENDATIONS

With the patient's history the most likely etiology for the nodular hepatopathy would be nodular hyperplasia with chronic hepatitis a possible differential diagnosis and granulomatous disease and infiltrative neoplasia highly unlikely differential diagnosis.

The gallbladder sediment can be considered an incidental finding.

Further assessment (if not previously done) would be FNA cytology of the liver. However, a tru cut or wedge biopsy may required for a final etiological diagnosis.

Specific therapy would be dependent on an etiological diagnosis.

Symptomatic management that could be considered for both the hepatopathy and the gallbladder sediment would be the use of Ursodiol with regular monitoring of liver enzyme activity.



PATIENT

Madchen Adelaar

SPECIES

Canine

BREED

Mixed

SEX

Spayed female

AGE

10 years

WEIGHT

38.6 lbs

INTERPRETED BY

Remo Lobetti, BVSc,
MMedVet (Med),
PhD, Dipl. ECVIM

IMAGING PERFORMED BY

Dr. Heather Platzer

HOSPITAL NAME

Hershire AH

REFERRING VET

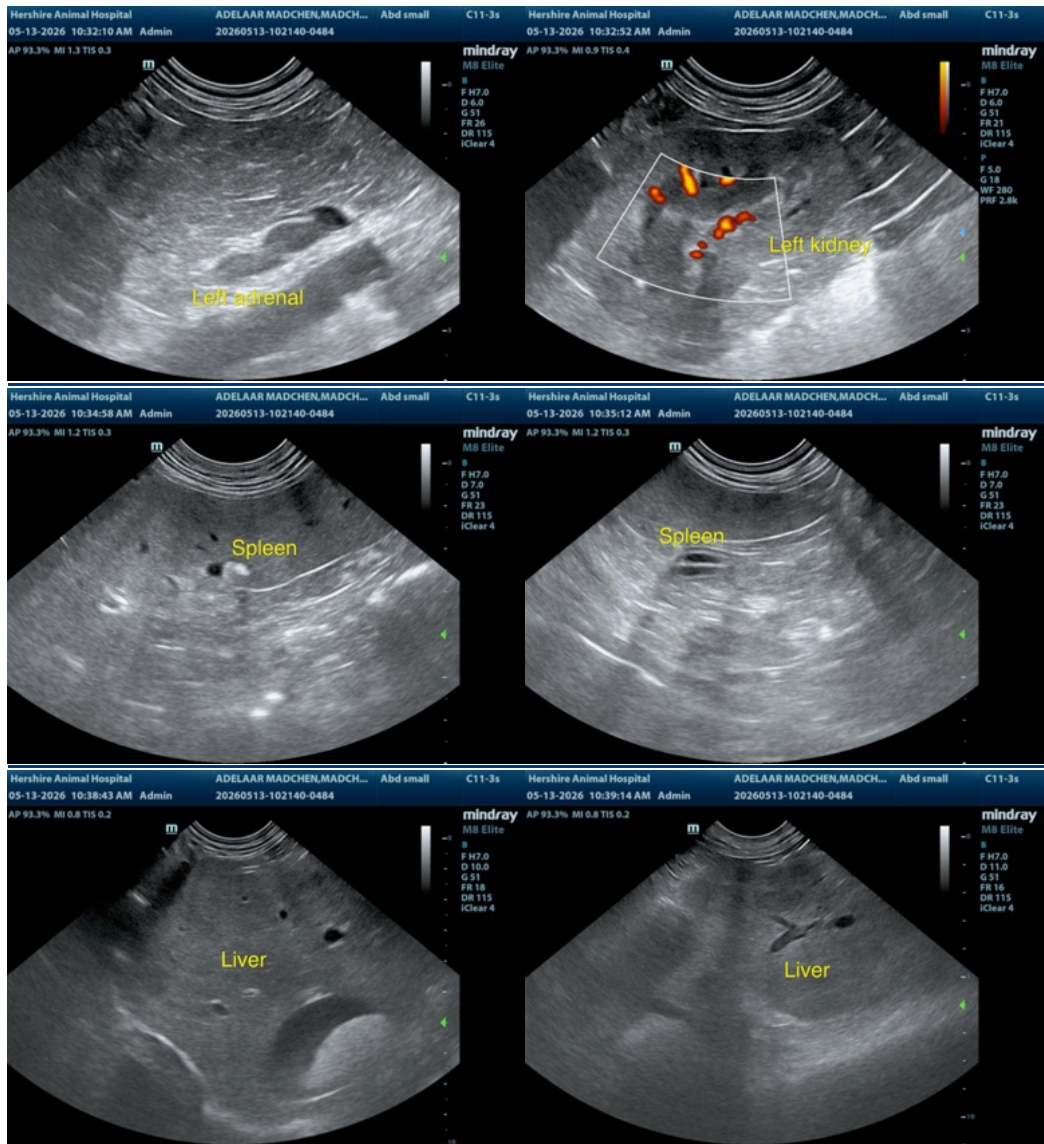
Dr. Erika Gallisdorfer

INVOICE

75495

DATE

5/13/26





PATIENT

Madchen Adelaar

SPECIES

Canine

BREED

Mixed

SEX

Spayed female

AGE

10 years

WEIGHT

38.6 lbs

INTERPRETED BY

Remo Lobetti, BVSc,
MMedVet (Med),
PhD, Dipl. ECVIM

IMAGING PERFORMED BY

Dr. Heather Platzer

HOSPITAL NAME

Hershire AH

REFERRING VET

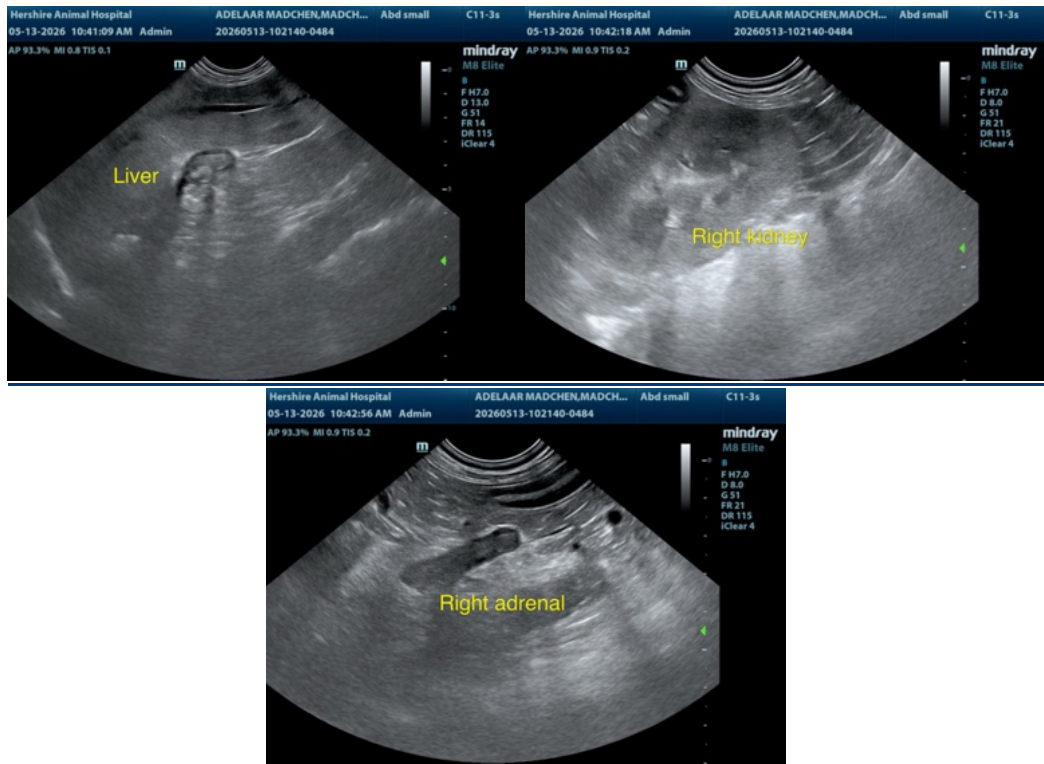
Dr. Erika Gallisdorfer

INVOICE

75495

DATE

5/13/26



The information and recommendations provided are based on the images presented by the referring veterinarian/sonographer. No evaluation can be communicated regarding pathology that was not visible in the image/video clips provided.

Thank you for this referral. If the clinical or image interpretation does not parallel your findings or if I can be of any further assistance please contact me.

Remo Lobetti, BVSc, MMedVet (Med), PhD, Dipl. ECVIM (Internal Medicine)

info@sonopath.com