



PATIENT

Lexi Sciuto

SPECIES

Canine

BREED

Golden Retriever

SEX

Spayed female

AGE

9 years

WEIGHT

48.3 lbs

INTERPRETED BY

Remo Lobetti, BVSc,
MMedVet (Med),
PhD, Dipl. ECVIM

IMAGING PERFORMED BY

Mallory Fois

HOSPITAL NAME

The Pet Hospital of
Stratford

REFERRING VET

Dr. Giuliani

INVOICE

75489

DATE

5/13/26

PRESENTING CLINICAL SIGNS

History: Presented 5/11 for ADR, decreased appetite for a couple of weeks. Was PU/PD at first now not drinking much. Did vomit, no diarrhea. Lethargic. O does not think got into anything. Lost ~17 lbs since October. dehydrated. BW- cpl and upc pending. ALB 2.2, Free T4 - 0.4/5.1

ULTRASONOGRAPHIC EXAMINATION OF THE ABDOMEN

Urinary System

The urinary bladder is small with a normal thickness and smooth appearance of the wall. Normal anechoic urine with no sediment or uroliths evident.

Normal appearance of the trigone area, proximal urethra, and iliac blood vessels.

Normal appearance and size of the iliac lymph nodes. Ureters not visualized, which can be considered a normal finding.

Normal renal size (left measured 5.5 cm, right measured 6.6 cm), architecture, echogenic appearance, cortico-medullary differentiation, which maintains a 1:3 cortex to medulla ratio, pelvis, and capsule. No infarcts, mineralization or renoliths evident. Normal color flow pattern is evident in both kidneys.

Adrenal Glands

The adrenal glands are not clearly visualized, but appear to be of normal shape, echogenic appearance and size.

Spleen

Normal size and echogenic appearance. Smooth homogenous parenchyma and regular curvilinear capsule. Normal volume of the splenic vasculature without any overt congestion or thrombosis evident. No inflammatory, neoplastic, infarction, or infiltrative changes evident. The spleen measured 1.3 cm in width.

Liver

Normal size, echogenic appearance, portal markings, and regular curvilinear capsule. No nodules or masses evident. Normal appearance of the hepatic and portal vasculature.

Gallbladder

The gallbladder is small containing normal anechoic bile. Normal thickness and echogenic appearance of the wall. Normal size and appearance of the cystic and common bile duct.



PATIENT

Lexi Sciuto

SPECIES

Canine

BREED

Golden Retriever

SEX

Spayed female

AGE

9 years

WEIGHT

48.3 lbs

INTERPRETED BY

Remo Lobetti, BVSc,
MMedVet (Med),
PhD, Dipl. ECVIM

IMAGING PERFORMED BY

Mallory Fois

HOSPITAL NAME

The Pet Hospital of
Stratford

REFERRING VET

Dr. Giuliani

INVOICE

75489

DATE

5/13/26

Gastrointestinal

Thickening of the wall of the pylorus measuring up to 1.0 cm with a hypoechoic appearance and possibly some loss of layering. The rest of the gastric wall is of normal thickness with no loss of layering and maintaining a 1:3 muscularis to mucosa ratio. Normal appearance of the duodenum, small intestine, ileo-cecal junction, and colon with no loss of layering, 1:3 muscularis to mucosa ratio, normal wall thickness and peristaltic activity, and no distension of the lumen.

Pancreas

The visible sections of the pancreas are of normal size and echogenic appearance with a regular capsule. Normal echogenic appearance of the mesentery and fat surrounding the pancreas.

Free Abdomen

Normal mesenteric lymph nodes.

No ascites evident.

ULTRASONOGRAPHIC FINDINGS

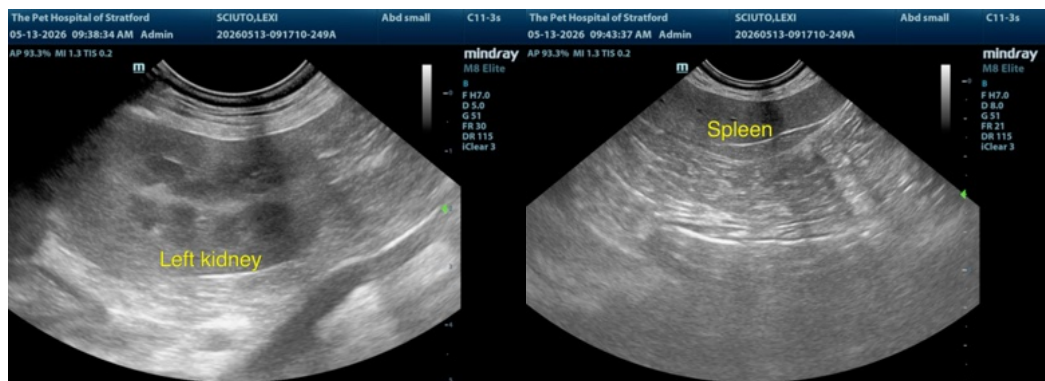
- Pyloric thickening.

INTERPRETATION OF THE FINDINGS & FURTHER RECOMMENDATIONS

Etiologies for the pyloric thickening would be chronic gastritis, Helicobacter gastritis, pyloric hypertrophy, ulcerative disease and possibly neoplasia.

Further assessment would be FNA cytology of the pylorus (if possible) and gastroscopy with biopsies.

Specific therapy would be dependent on an etiological diagnosis.





PATIENT

Lexi Sciuto

SPECIES

Canine

BREED

Golden Retriever

SEX

Spayed female

AGE

9 years

WEIGHT

48.3 lbs

INTERPRETED BY

Remo Lobetti, BVSc,
MMedVet (Med),
PhD, Dipl. ECVIM

IMAGING PERFORMED BY

Mallory Fois

HOSPITAL NAME

The Pet Hospital of
Stratford

REFERRING VET

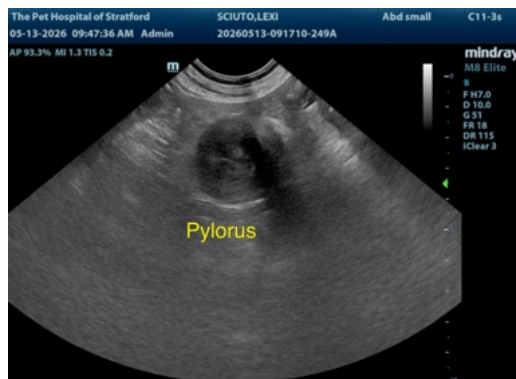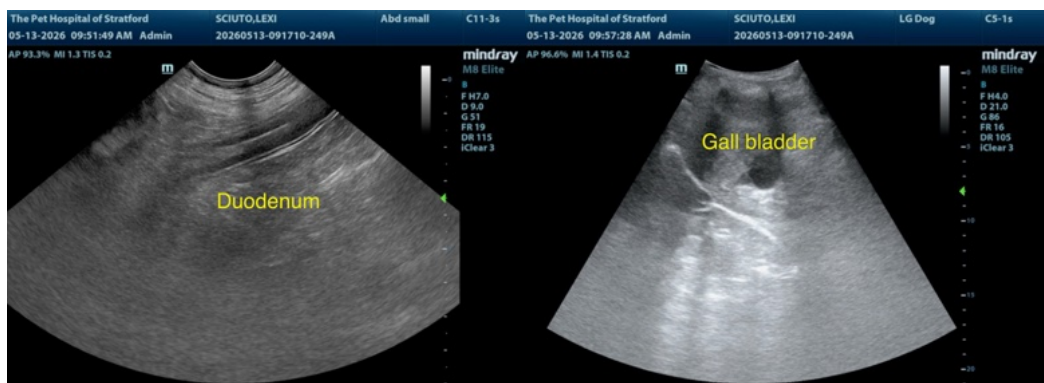
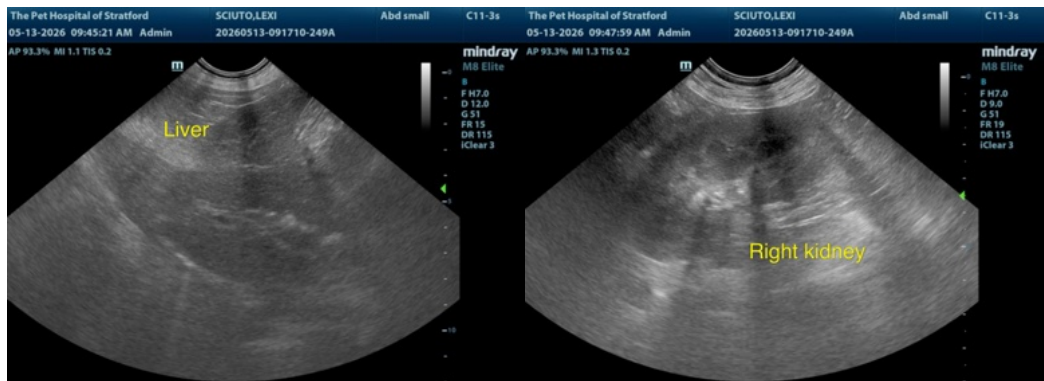
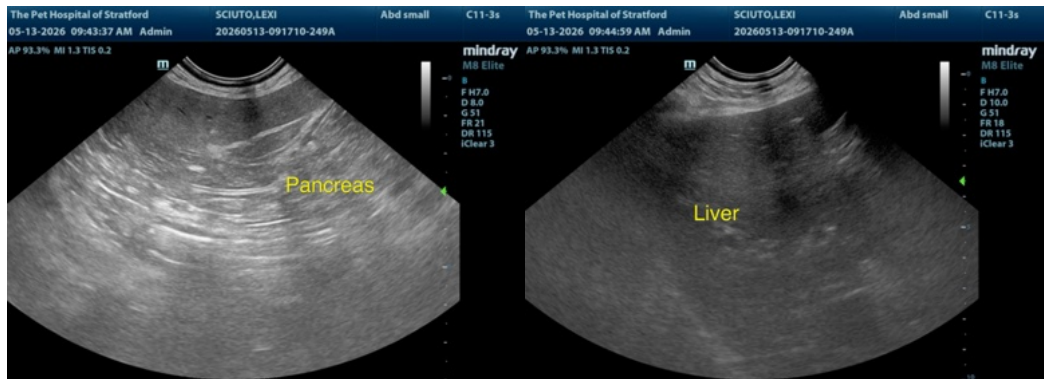Dr. Giuliani

INVOICE

75489

DATE

5/13/26





PATIENT

Lexi Sciuto

SPECIES

Canine

BREED

Golden Retriever

SEX

Spayed female

AGE

9 years

WEIGHT

48.3 lbs

INTERPRETED BY

Remo Lobetti, BVSc,
MMedVet (Med),
PhD, Dipl. ECVIM

IMAGING PERFORMED BY

Mallory Fois

HOSPITAL NAME

The Pet Hospital of
Stratford

REFERRING VET

Dr. Giuliani

INVOICE

75489

DATE

5/13/26

The information and recommendations provided are based on the images presented by the referring veterinarian/sonographer. No evaluation can be communicated regarding pathology that was not visible in the image/video clips provided.

Thank you for this referral. If the clinical or image interpretation does not parallel your findings or if I can be of any further assistance please contact me.

Remo Lobetti, BVSc, MMedVet (Med), PhD, Dipl. ECVIM (Internal Medicine)

info@sonopath.com