



PATIENT

Chewie Medina

SPECIES

Canine

BREED

Yorkie Poo Mix

SEX

Neutered male

AGE

7 years

WEIGHT

10.4 lbs

INTERPRETED BY

Remo Lobetti, BVSc,
MMedVet (Med),
PhD, Dipl. ECVIM

IMAGING PERFORMED BY

Mario Valverde

HOSPITAL NAME

TLC AH

REFERRING VET

Dr. Priscilla

INVOICE

75485

DATE

5/13/26

PRESENTING CLINICAL SIGNS

History: -REC ABDOMINAL U/S TO EVALUATE THE LIVER AND KIDNEYS (to rule out kidney/bladder stones); +/- cystotomy

-glucose curve in 1 week-2 weeks (after abdominal u/s)

-stay on Vetsulin 2.5 units bid

- for abdominal u/s (2-4 hour fasting (1/2 meal); Give 1/2 dose insulin at time of meal (1 unit of Vetsulin); Try to perform as first case of the day

History for abdominal u/s:

- P is doing well overall; no v/d; p is e/d well

-history of hepatitis since 2023- well controlled and liver enzymes are now normal; D/C CYCLOSPORINE EARLY THIS YEAR

-Diagnosed with Diabetes Mellitus 1/2026

-upon cystocentesis for urine collections it appeared possible bladder calculi on 5/4/2026

-medication includes Vetsulin, cerenia prn, w/d diet; ursodiol

-GOAL is to evaluate the liver and kidneys/ bladder

ULTRASONOGRAPHIC EXAMINATION OF THE ABDOMEN

Urinary System

The urinary bladder is full with a normal thickness and smooth appearance of the wall. Normal anechoic urine with no sediment or uroliths evident.

Normal appearance of the trigone area, proximal urethra, and iliac blood vessels.

Normal appearance and size of the iliac lymph nodes. Ureters not visualized, which can be considered a normal finding.

Normal renal size (left measured 3.6 cm, right measured 4.1 cm), architecture, echogenic appearance, cortico-medullary differentiation, which maintains a 1:3 cortex to medulla ratio, pelvis, and capsule. No infarcts, mineralization or renoliths evident.

The prostate is small and hypoechogenic.

Adrenal Glands

Normal shape, echogenic appearance, size, position, and appearance of the visible peri-adrenal vasculature. Left adrenal gland measured 0.33 cm in width. The right adrenal gland measured 0.5 cm in width.

Spleen

Normal size and echogenic appearance. Smooth homogenous parenchyma and regular curvilinear capsule. Normal volume of the splenic vasculature without any overt congestion or thrombosis evident. No inflammatory, neoplastic, infarction, or infiltrative changes evident. The spleen measured 0.7 cm in width.



PATIENT

Chewie Medina

SPECIES

Canine

BREED

Yorkie Poo Mix

SEX

Neutered male

AGE

7 years

WEIGHT

10.4 lbs

INTERPRETED BY

Remo Lobetti, BVSc,
MMedVet (Med),
PhD, Dipl. ECVIM

IMAGING PERFORMED BY

Mario Valverde

HOSPITAL NAME

TLC AH

REFERRING VET

Dr. Priscilla

INVOICE

75485

DATE

5/13/26

Liver

Normal size, echogenic appearance, portal markings, and regular curvilinear capsule. No nodules or masses evident. Normal appearance of the hepatic and portal vasculature.

Gallbladder

The gallbladder is small containing normal anechoic bile. Normal thickness and echogenic appearance of the wall. Normal size and appearance of the cystic and common bile duct.

Gastrointestinal

Normal appearance of the stomach, duodenum, small intestine, ileo-cecal junction, and colon with no loss of layering, 1:3 muscularis to mucosa ratio, normal wall thickness and peristaltic activity, and no distension of the lumen. Fecal material was present in the colon.

Pancreas

The visible sections of the pancreas are of normal size and echogenic appearance with a regular capsule. Normal echogenic appearance of the mesentery and fat surrounding the pancreas.

Free Abdomen

Normal mesenteric lymph nodes.

No ascites evident.

ULTRASONOGRAPHIC FINDINGS

- Normal ultrasound examination of the abdomen.

INTERPRETATION OF THE FINDINGS & FURTHER RECOMMENDATIONS

No specific therapy is recommended at this time.



PATIENT

Chewie Medina

SPECIES

Canine

BREED

Yorkie Poo Mix

SEX

Neutered male

AGE

7 years

WEIGHT

10.4 lbs

INTERPRETED BY

Remo Lobetti, BVSc,
MMedVet (Med),
PhD, Dipl. ECVIM

**IMAGING
PERFORMED BY**

Mario Valverde

HOSPITAL NAME

TLC AH

REFERRING VET

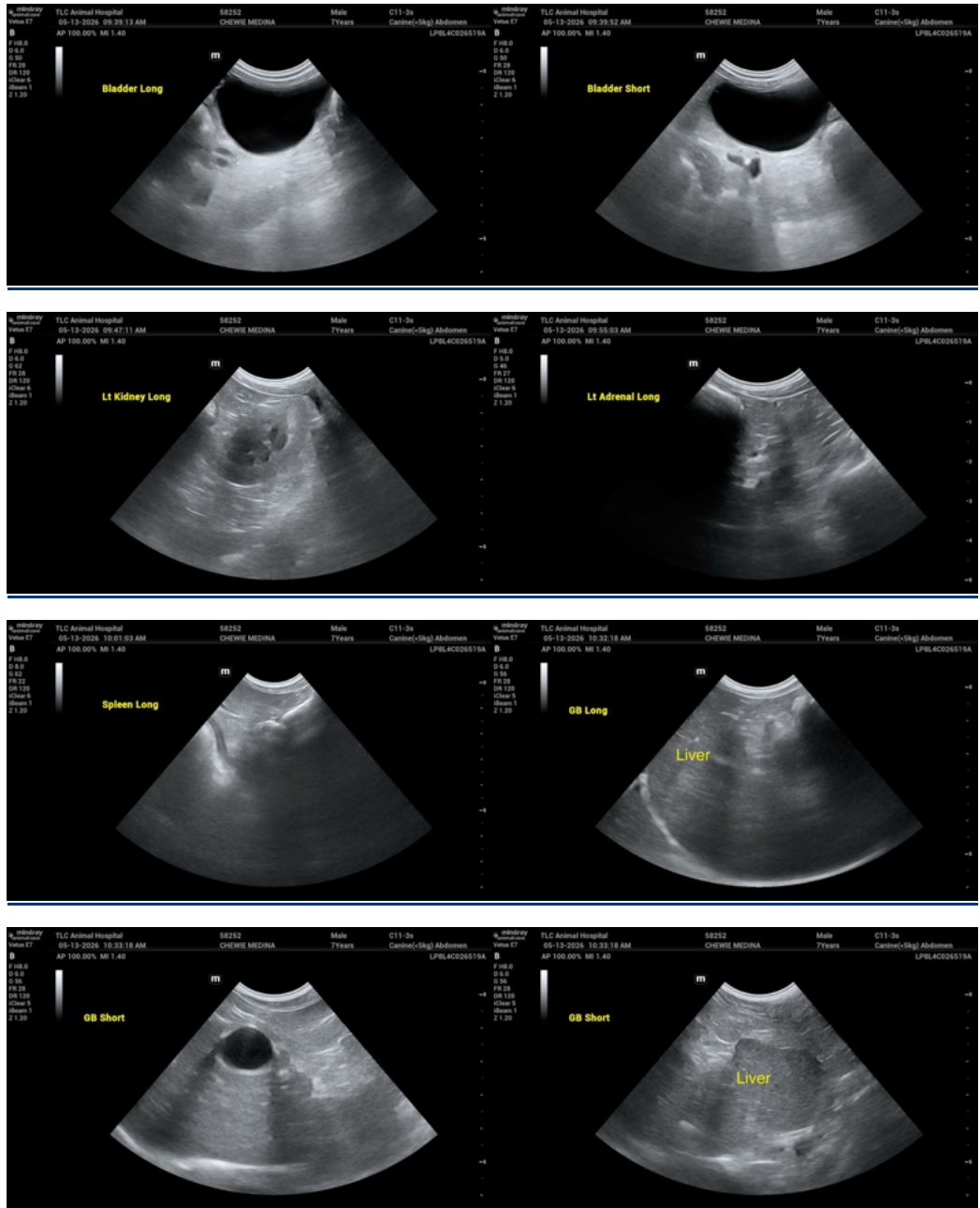
Dr. Priscilla

INVOICE

75485

DATE

5/13/26





PATIENT

Chewie Medina

SPECIES

Canine

BREED

Yorkie Poo Mix

SEX

Neutered male

AGE

7 years

WEIGHT

10.4 lbs

INTERPRETED BY

Remo Lobetti, BVSc,
MMedVet (Med),
PhD, Dipl. ECVIM

IMAGING PERFORMED BY

Mario Valverde

HOSPITAL NAME

TLC AH

REFERRING VET

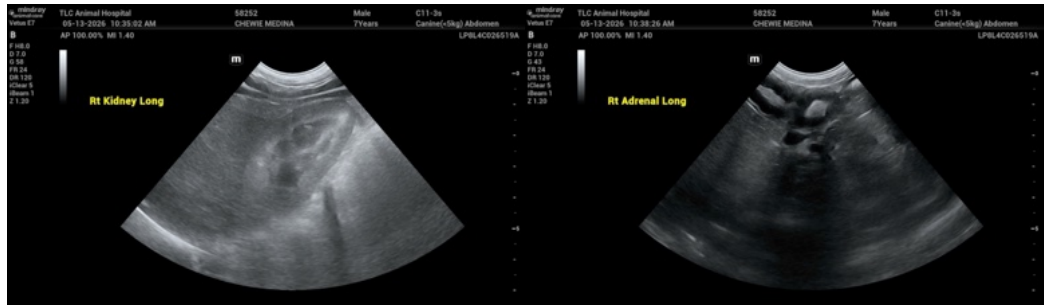
Dr. Priscilla

INVOICE

75485

DATE

5/13/26



The information and recommendations provided are based on the images presented by the referring veterinarian/sonographer. No evaluation can be communicated regarding pathology that was not visible in the image/video clips provided.

Thank you for this referral. If the clinical or image interpretation does not parallel your findings or if I can be of any further assistance please contact me.

Remo Lobetti, BVSc, MMedVet (Med), PhD, Dipl. ECVIM (Internal Medicine)

info@sonopath.com