



PATIENT

Goose Hackemer

SPECIES

Canine

BREED

Mix

SEX

Spayed female

AGE

8 years

WEIGHT

67.8 lbs

INTERPRETED BY

Remo Lobetti, BVSc,
MMedVet (Med),
PhD, Dipl. ECVIM

IMAGING PERFORMED BY

Dr. Joan Kula
Gramazio

HOSPITAL NAME

Narrowsburg
Veteirmary

REFERRING VET

Dr. Kula Gramazio

INVOICE

75374

DATE

5/12/26

PRESENTING CLINICAL SIGNS

History: Has been off lately. Getting up and pacing and panting at night time. Palpated a anal gland mass in the rectum area came back as inflammation and no neoplasia. Took radiographs and radiology report recommended abdominal ultrasound to rule out potential splenic mass. E/D/U/D normally otherwise.

Abnormal PE/Chem/CBC/UA Results: All normal

ULTRASONOGRAPHIC EXAMINATION OF THE ABDOMEN

Urinary System

The urinary bladder is full with a normal thickness and smooth appearance of the wall. Normal anechoic urine with no sediment or uroliths evident.

Normal appearance of the trigone area, proximal urethra, and iliac blood vessels.

Normal appearance and size of the iliac lymph nodes. Ureters not visualized, which can be considered a normal finding.

Normal renal size (left measured 5.5 cm, right measured 5.8 cm), architecture, echogenic appearance, cortico-medullary differentiation, which maintains a 1:3 cortex to medulla ratio, pelvis, and capsule. No infarcts, mineralization or renoliths evident.

Adrenal Glands

The adrenal glands are not clearly visualized, but both appear to be of normal shape, echogenic appearance and size.

Spleen

Normal size and echogenic appearance. Smooth homogenous parenchyma and regular curvilinear capsule. Normal volume of the splenic vasculature without any overt congestion or thrombosis evident. No inflammatory, neoplastic, infarction, or infiltrative changes evident. The spleen measured 2.3 cm in width.

Liver

Normal size, echogenic appearance, portal markings, and regular curvilinear capsule. No nodules or masses evident. Normal appearance of the hepatic and portal vasculature.

Gallbladder

The gallbladder is full containing a small amount of non-adhered, hyperechogenic sediment. Normal thickness and echogenic appearance of the wall. Normal size and appearance of the cystic and common bile duct.



PATIENT

Goose Hackemer

SPECIES

Canine

BREED

Mix

SEX

Spayed female

AGE

8 years

WEIGHT

67.8 lbs

INTERPRETED BY

Remo Lobetti, BVSc,
MMedVet (Med),
PhD, Dipl. ECVIM

IMAGING PERFORMED BY

Dr. Joan Kula
Gramazio

HOSPITAL NAME

Narrowsburg
Veteirmary

REFERRING VET

Dr. Kula Gramazio

INVOICE

75374

DATE

5/12/26

Gastrointestinal

Normal appearance of the stomach, duodenum, small intestine, ileo-cecal junction, and colon with no loss of layering, 1:3 muscularis to mucosa ratio, normal wall thickness and peristaltic activity, and no distension of the lumen. A moderate amount of ingesta is present within the stomach compatible with a recent meal.

Pancreas

The visible sections of the pancreas are of normal size and echogenic appearance with a regular capsule. Normal echogenic appearance of the mesentery and fat surrounding the pancreas.

Free Abdomen

Normal mesenteric lymph nodes.

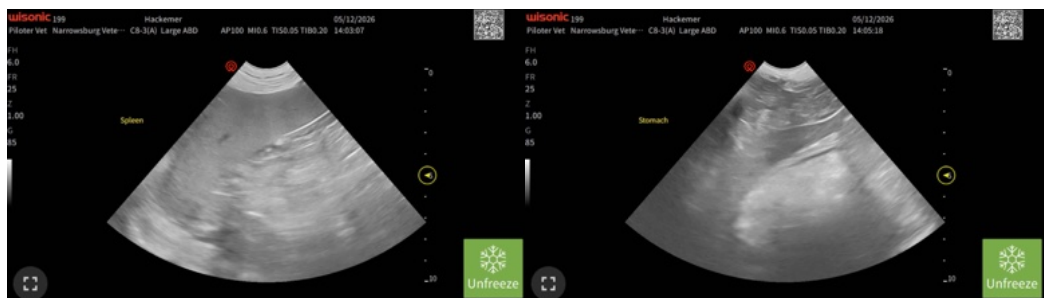
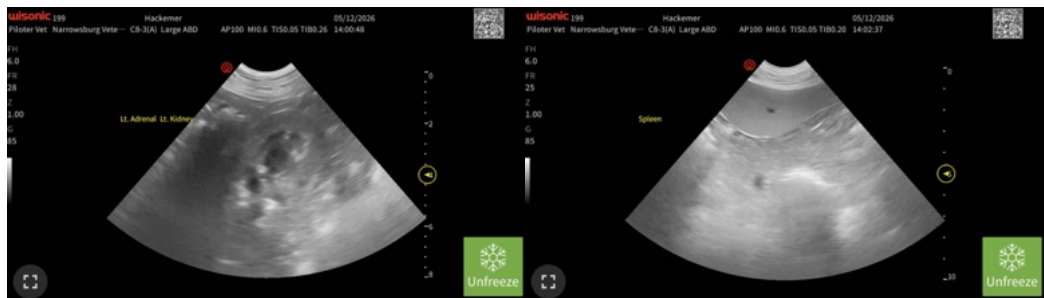No ascites evident.

ULTRASONOGRAPHIC FINDINGS

- Gallbladder sediment.

INTERPRETATION OF THE FINDINGS & FURTHER RECOMMENDATIONS

In essence a normal ultrasound examination of the abdomen, as the gallbladder sediment can be considered an incidental finding.





PATIENT

Goose Hackemer

SPECIES

Canine

BREED

Mix

SEX

Spayed female

AGE

8 years

WEIGHT

67.8 lbs

INTERPRETED BY

Remo Lobetti, BVSc,
MMedVet (Med),
PhD, Dipl. ECVIM

IMAGING PERFORMED BY

Dr. Joan Kula
Gramazio

HOSPITAL NAME

Narrowsburg
Veteirmary

REFERRING VET

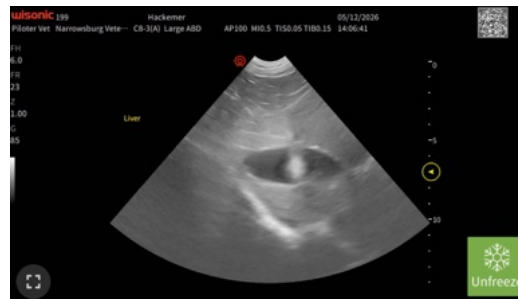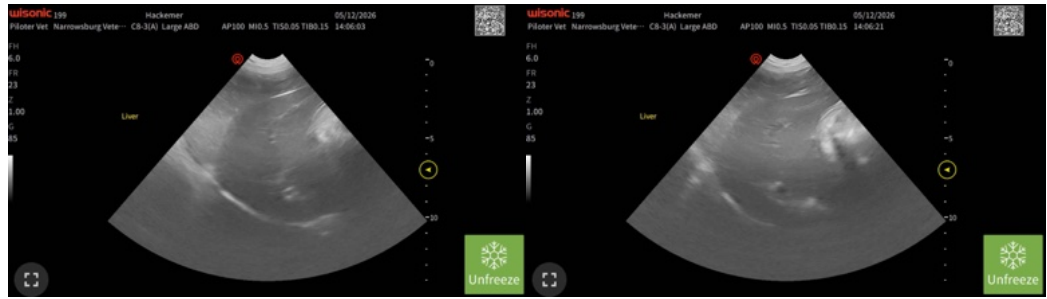
Dr. Kula Gramazio

INVOICE

75374

DATE

5/12/26



The information and recommendations provided are based on the images presented by the referring veterinarian/sonographer. No evaluation can be communicated regarding pathology that was not visible in the image/video clips provided.

Thank you for this referral. If the clinical or image interpretation does not parallel your findings or if I can be of any further assistance please contact me.

Remo Lobetti, BVSc, MMedVet (Med), PhD, Dipl. ECVIM (Internal Medicine)

info@sonopath.com