



## PATIENT

Boris Kuwabara

## SPECIES

Canine

## BREED

French Bulldog

## SEX

Neutered male

## AGE

9 years

## WEIGHT

29.2 lbs

## INTERPRETED BY

Remo Lobetti, BVSc,  
MMedVet (Med),  
PhD, Dipl. ECVIM

## IMAGING PERFORMED BY

Dr. Stranzl

## HOSPITAL NAME

Dakota VC

## REFERRING VET

Dr. Stranzl

## INVOICE

75384

## DATE

5/12/26

## PRESENTING CLINICAL SIGNS

History: Immunohistochemistry results - T cell lymphoma on skin, paraplegic hind legs  
hx or recurrent UTIs

hx KCS

HX parapalegic

HX allergies

Hx fractured premolar L upper

Hx mild mitral regurg/tricuspid regurgitant pressure gradient w/ R sided cardiac prominence

## ULTRASONOGRAPHIC EXAMINATION OF THE ABDOMEN

### *Urinary System*

The urinary bladder is small with a normal thickness and smooth appearance of the wall. Normal anechoic urine with no sediment or uroliths evident.

Normal appearance of the trigone area, proximal urethra, and iliac blood vessels.

Normal appearance and size of the iliac lymph nodes. Ureters not visualized, which can be considered a normal finding.

Normal renal size (left measured 5.2 cm, right measured 5.1 cm), architecture, echogenic appearance, cortico-medullary differentiation, which maintains a 1:3 cortex to medulla ratio, pelvis, and capsule. No infarcts, mineralization or renoliths evident. Normal color flow pattern is evident in both kidneys.

The prostate is small and hypoechogenic.

### *Adrenal Glands*

The left adrenal gland is normal in shape, echogenic appearance, size, position, and appearance of the visible peri-adrenal vasculature. Left adrenal gland measured 1.85 cm in length x 0.4 cm in width. The right adrenal gland was not visualized.

### *Spleen*

Normal size and echogenic appearance. Smooth homogenous parenchyma and regular curvilinear capsule. Normal volume of the splenic vasculature without any overt congestion or thrombosis evident. No inflammatory, neoplastic, infarction, or infiltrative changes evident. The spleen measured 1.9 cm in width.

### *Liver*

Normal size, echogenic appearance, portal markings, and regular curvilinear capsule. No nodules or masses evident. Normal appearance of the hepatic and portal vasculature.



**PATIENT**

Boris Kuwabara

**SPECIES**

Canine

**BREED**

French Bulldog

**SEX**

Neutered male

**AGE**

9 years

**WEIGHT**

29.2 lbs

**INTERPRETED BY**

Remo Lobetti, BVSc,  
MMedVet (Med),  
PhD, Dipl. ECVIM

**IMAGING PERFORMED BY**

Dr. Stranzl

**HOSPITAL NAME**

Dakota VC

**REFERRING VET**

Dr. Stranzl

**INVOICE**

75384

**DATE**

5/12/26

**Gallbladder**

The gallbladder is small containing normal anechoic bile. Normal thickness and echogenic appearance of the wall. Normal size and appearance of the cystic and common bile duct.

**Gastrointestinal**

Normal appearance of the stomach, duodenum, small intestine, ileo-cecal junction, and colon with no loss of layering, 1:3 muscularis to mucosa ratio, normal wall thickness and peristaltic activity, and no distension of the lumen.

**Pancreas**

The visible sections of the pancreas are of normal size and echogenic appearance with a regular capsule. Normal echogenic appearance of the mesentery and fat surrounding the pancreas.

**Free Abdomen**

Normal mesenteric lymph nodes.

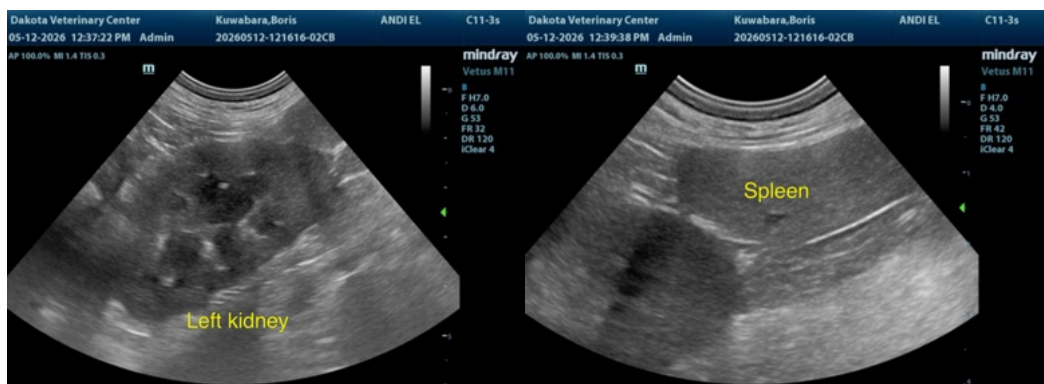
No ascites evident.

**ULTRASONOGRAPHIC FINDINGS**

- Normal ultrasound examination of the abdomen.

**INTERPRETATION OF THE FINDINGS & FURTHER RECOMMENDATIONS**

On this ultrasound there is no obvious evidence of intraabdominal lymphoma.





## PATIENT

Boris Kuwabara

## SPECIES

Canine

## BREED

French Bulldog

## SEX

Neutered male

## AGE

9 years

## WEIGHT

29.2 lbs

## INTERPRETED BY

Remo Lobetti, BVSc,  
MMedVet (Med),  
PhD, Dipl. ECVIM

## IMAGING PERFORMED BY

Dr. Stranzl

## HOSPITAL NAME

Dakota VC

## REFERRING VET

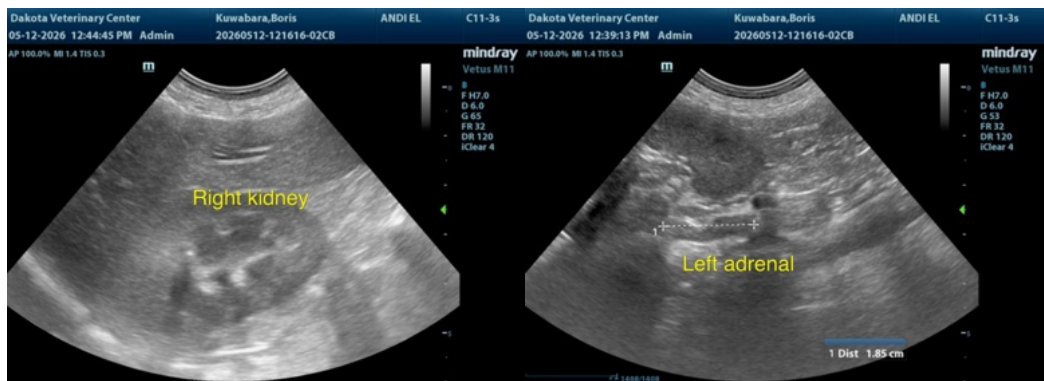
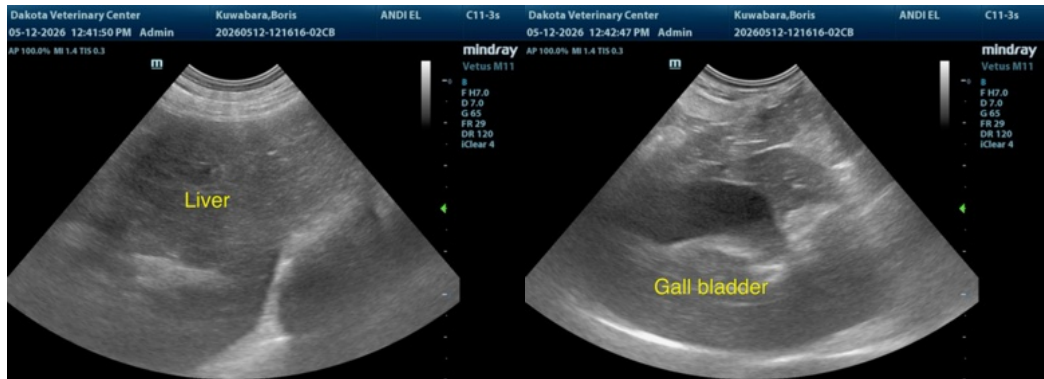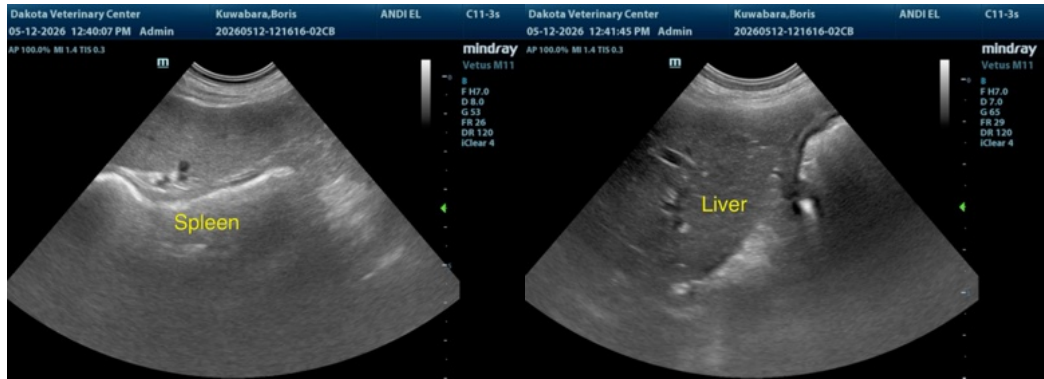Dr. Stranzl

## INVOICE

75384

## DATE

5/12/26



The information and recommendations provided are based on the images presented by the referring veterinarian/sonographer. No evaluation can be communicated regarding pathology that was not visible in the image/video clips provided.

Thank you for this referral. If the clinical or image interpretation does not parallel your findings or if I can be of any further assistance please contact me.

Remo Lobetti, BVSc, MMedVet (Med), PhD, Dipl. ECVIM (Internal Medicine)

[info@sonopath.com](mailto:info@sonopath.com)